

# Fractional CO<sub>2</sub> laser and adjunctive therapies in skin of color melasma patients



Carey Kim, MD,<sup>a,b</sup> Jia C. Gao, BS,<sup>a,b</sup> Janet Moy, MD,<sup>a,b</sup> and Hyun Soo Lee, MD<sup>c,d</sup>  
New York and Valhalla, New York

**Background:** Ablative lasers have long been considered an unfavorable option for melasma in patients with skin of color and continue to be underutilized.

**Objective:** To evaluate the safety and outcomes of ablative fractional CO<sub>2</sub> lasers on refractory melasma in patients with skin of color.

**Methods:** A retrospective chart review of 12 patients from a single-center dermatology clinic. The study included refractory melasma patients receiving ablative fractional CO<sub>2</sub> laser therapy alone or with laser toning and/or tranexamic acid (TXA). A validated modified Melasma Area and Severity Index (mMASI) scoring scale was used to assess disease severity at baseline and approximately 1 month after each treatment session.

**Results:** Among the 12 patients, 41.7% patients showed >50% reduction in mMASI scores with 33.3% of patients showing statistical significance ( $P < .05$ ). The CO<sub>2</sub> laser therapy with the TXA cohort showed the largest decrease in the mean mMASI scores and the CO<sub>2</sub> laser with laser toning showed the lowest decrease in scores. Patients who started on oral TXA earlier, after their initial ablative laser session, showed better clinical improvement.

**Limitations:** Retrospective study design with short follow-up period and a small sample size.

**Conclusion:** Ablative CO<sub>2</sub> laser treatment may be a reasonable option for refractory melasma in patients with skin of color, though future research is needed. (JAAD Int 2022;8:118-23.)

**Key words:** ablative laser; Asian; general dermatology; melasma; retrospective study; skin of color.

## INTRODUCTION

Melasma is an acquired hyperpigmentation condition that is common in darker skin types and Asian women of childbearing age.<sup>1</sup> Several etiologic factors have been identified, including UV and visible light exposure, hormonal changes from exogenous hormone use or pregnancy, and genetic predisposition; however, the pathogenesis of melasma remains unclear.<sup>2,3</sup> Although otherwise asymptomatic and without known associated conditions, melasma can cause considerable physical and psychosocial distress.<sup>4</sup>

Many treatment options are available for melasma, but with mixed results and high rates of adverse events and recurrence. First-line treatment for melasma involves topical therapies, which can be safe and effective, but noticeable improvement requires long periods of diligent use.<sup>5,6</sup> Laser- and light-based therapies have become an alternative and adjunctive treatment option, especially in patients with refractory melasma.

The safety and efficacy of intense pulsed light, Q-switched lasers, and nonablative fractional lasers for melasma have been well described in many studies

From the Department of Dermatology, Metropolitan Medical Center, New York,<sup>a</sup> the Department of Dermatology, New York Medical College, Valhalla,<sup>b</sup> the Department of Dermatology, Mount Sinai Hospital, New York,<sup>c</sup> and Metro Dermatology, New York.<sup>d</sup>

Funding sources: None.

IRB approval status: Reviewed and approved by NYMC IRB; approval 14558.

Accepted for publication February 25, 2022.

Correspondence to: Carey Kim, MD, 1901 1st Avenue, New York, NY 10029. E-mail: [kimc28@nychhc.org](mailto:kimc28@nychhc.org). 2666-3287

© 2022 by the American Academy of Dermatology, Inc. Published by Elsevier Inc. This is an open access article under the CC BY-NC-ND license (<http://creativecommons.org/licenses/by-nc-nd/4.0/>).

<https://doi.org/10.1016/j.jdin.2022.02.010>

and systematic reviews.<sup>7,8</sup> These lasers have wide ranges of efficacy as single and combined treatments, often with minimal side effects but high recurrence rates.<sup>9</sup> Laser toning, which is a low fluence multipass technique commonly using Q-switched Nd:YAG lasers, showed modified Melasma Area and Severity Index (mMASI) score improvements of 21% to 75% with no adverse events in a 12-patient study treated with 10 weekly sessions.<sup>10</sup> Combination laser toning and intense pulsed light treatment of mixed-type melasma showed an average mMASI score decrease of 59.35% with no subsequent dyspigmentation.<sup>11</sup> Another study combining laser toning with oral tranexamic acid (TXA) found superior mMASI score reductions when compared with laser-only treatments.<sup>12</sup> However, few studies using ablative fractional lasers for melasma have been conducted because of the risk of posttreatment dyspigmentation, particularly in patients with skin of color.<sup>8</sup> Although laser parameters and adjunctive therapies appropriate for skin of color have been described to mitigate some of the risks of dyspigmentation, ablative lasers have long been considered an unfavorable option and continue to be under-researched and underutilized.<sup>13,14</sup>

Ablative fractionated lasers, including CO<sub>2</sub> and erbium:YAG lasers have been reported to improve melasma with limited side effects. A split-face study of 30 patients showed MASI reductions in patients treated with CO<sub>2</sub> lasers with and without TXA.<sup>15</sup> Treatments that combine CO<sub>2</sub> lasers with long-term skin lightening topicals had treatment benefits of up to 12 months posttreatment.<sup>16</sup> Greater reductions in MASI scores and Melanin Index were observed with fractional CO<sub>2</sub> lasers compared with Q-switch 1064 nm Nd:YAG lasers with no significant adverse events in both treatment groups.<sup>17</sup> A case report of a skin type V patient unresponsive to nonablative fractional laser treatment showed improvements after 7 sessions over 10 months with ablative CO<sub>2</sub> laser treatment.<sup>18</sup> Findings using ablative lasers have been promising; however, the paucity of studies in patients with skin of color continues to limit its use.

Herein, the authors evaluated the safety and efficacy of an ablative fractional CO<sub>2</sub> laser (eCO<sub>2</sub> Lutronic) on refractory cases of melasma in patients with skin of color by retrospective review of medical records and photographic analysis. The authors

describe the treatment plans, laser settings, and concomitant therapies used for patients with skin of color and report the clinical outcomes and associated adverse events.

## MATERIALS AND METHODS

We conducted a retrospective chart review of 12 patients selected from a single-center dermatology clinic at Metro Dermatology. Patients over 18 years of age with refractory melasma and Fitzpatrick skin type III to IV, who received ablative fractional CO<sub>2</sub> laser therapy alone or with laser toning and/or TXA from January 2010 to December 2020 were included in the study. Refractory melasma was defined as minimal or no

response after 3 to 5 laser toning sessions and a TXA dosage of 325 mg twice daily.

The exclusion criteria were as follows: less than 18 years of age, completion of chemical peels or laser procedures related to melasma lesions within 3 months before starting CO<sub>2</sub> laser therapy, or concomitant use of topical skin lightening therapies. Patients with incomplete clinical data or missing clinical photos were further excluded.

Assessments were done using electronic medical records, and accompanying patient photos were extracted from the Canfield digital photography system. A validated mMASI scoring scale was used to assess disease severity at baseline, approximately 1 month (average, 35 days) after each treatment session, and at posttreatment follow-up if any side effects were observed. Investigators completed an mMASI training module to ensure reliability and accuracy between the 2 independent blinded raters (C.K., J.G.).

Laser procedures were performed by an experienced dermatologist (H.L.) using Lutronic eCO<sub>2</sub> fractional laser and Lutronic PicoPlus and Spectra toning lasers. Settings for the Spectra laser were 1 J/cm<sup>2</sup>, 8 mm, 10 Hz, 3 to 4 passes, and for the PicoPlus was 0.3 to 0.5 J/cm<sup>2</sup>, 10 Hz, 3 to 4 passes.

## RESULTS

Among the 12 patients who received CO<sub>2</sub> laser therapy, 10 patients completed adjunctive laser toning and/or TXA (Table D). The 4 cohorts of patients received the following therapies: 4 received fractional CO<sub>2</sub> alone, 2 received fractional CO<sub>2</sub> with laser toning, 2 received fractional CO<sub>2</sub> with TXA, and 6 received

### CAPSULE SUMMARY

- Various nonablative lasers have been described to treat recalcitrant melasma; however, efficacy and safety studies of ablative CO<sub>2</sub> lasers on patients with skin of color are limited.
- Clinicians may consider ablative CO<sub>2</sub> lasers in refractory cases of melasma in darker skin types.

**Abbreviations used:**

TXA:	tranexamic acid
mMASI:	modified Melasma Area and Severity Index

fractional CO<sub>2</sub> with laser toning and TXA. Patients 2 and 12 completed 2 types of treatments and were included in 2 treatment cohorts. Nine of 12 patients (75%) showed some improvement in mMASI scores and 5 of 12 (41.7%) patients showed >50% reduction in mMASI scores, with 4 of these patients (33.3%) showing statistical significance (Fig 1). All patients with more than 1 laser session showed improvements ( $P < .05$ ). Laser toning was completed with a mean of 2.8 weeks after the CO<sub>2</sub> laser procedure, and TXA patients were on medication for a mean of 12 weeks when posttreatment mMASI scores were evaluated.

Patients were stratified based on treatment types to show any differences in treatment efficacy among the 4 cohorts (Table II). Fractional CO<sub>2</sub> with TXA had a superior outcome and fractional CO<sub>2</sub> with laser toning performed the worst based on absolute changes in average mMASI scores. Only the cohort treated with fractional CO<sub>2</sub> alone had a >50% mMASI score reduction. The patient treated with fractional CO<sub>2</sub> and laser toning who started TXA earlier (patient 7) had a greater mMASI score reduction of 1.35 compared to a mean of 0.75 in patients who started on TXA 2 weeks later (patients 4 and 5).

Complications were uncommon with CO<sub>2</sub> laser therapy and resolved within the next follow-up visit for 1 patient. Patient 1 experienced facial swelling for several days after the procedure and was prescribed Epiceram with subsequent resolution after 1 week. The laser parameters were modified during the second session from 24 mJ, 50/cm to 22 mJ, 75/cm with no future complications. Patient 6 had exacerbation of hyperpigmentation during the 1-month postprocedure visit and was subsequently lost to follow-up.

## DISCUSSION

Topical medications are considered first-line treatment for melasma with lasers reserved for refractory or severe cases of melasma.<sup>5</sup> We evaluated the outcomes and adverse effects of ablative lasers in conjunction with adjunctive therapies in patients with skin of color with melasma.

The majority of patients (75%) in our study showed improved melasma with at least 1 session of CO<sub>2</sub> laser therapy. More than half of the patients with improvements had >50% reduction in mMASI scores and 4 of these patients showed statistically significant decreases in melasma severity. Patients treated with a

combination of CO<sub>2</sub> and laser toning showed worsening in mMASI scores. Interestingly, the addition of TXA in the treatment protocol of patients treated with both lasers had a protective effect and produced improved mMASI scores. The CO<sub>2</sub> laser therapy with the TXA cohort showed the greatest absolute decreases in the mean mMASI scores.

Prior studies describing ablative laser parameters in darker skin types were reviewed and adjusted in our patient population to improve tolerability, reduce risks of scarring and dyspigmentation, and optimize efficacy.<sup>19</sup> The majority of patients included in this study tolerated ablative laser treatment well. One patient experienced transient swelling which resolved within a week of onset, and an additional patient had worsening hyperpigmentation and was lost to follow-up. There were no other incidents of permanent scarring, dyspigmentation, or other reported adverse events.

Earlier administration of oral TXA was associated with better posttreatment mMASI scores. Concomitant administration of oral TXA has been known to play a complementary role in laser-based melasma treatments.<sup>15</sup> However, outcomes relative to the timing of oral TXA administration in conjunction with laser therapy have not been reported. The patient who started on oral TXA at the same time as their initial laser treatment showed better clinical improvement than patients who were prescribed oral TXA at later dates. Earlier administration of oral TXA appears to improve the clinical outcomes of patients concomitantly treated with CO<sub>2</sub> and toning lasers in melasma patients with skin of color.

The study limitations are that it is a single-center study, has a limited sample size, and a short follow-up period. However, the average onset of postinflammatory hyperpigmentation after ablative fractional CO<sub>2</sub> treatment is 7 to 14 days; therefore, hyperpigmentation as a side effect would likely develop within the 30-day follow-up period.<sup>20</sup> The scorers used clinical images taken approximately 30 days after the initial ablative laser treatment with periods ranging between 21 and 41 days. The patients selected for the study were managed with intention-to-treat rather than a head-to-head comparison of treatment modalities.

In cases of refractory melasma, providers may consider a trial of ablative CO<sub>2</sub> laser treatment as it is well-tolerated and shows robust improvement for patients with skin of color. Its use in conjunction with oral TXA is promising, but further studies with combination ablative lasers are still required. Equally important, once remission is achieved, maintenance therapy with skin lightening topicals and preventative iron oxide-containing sunscreens are essential to minimize future recurrences.

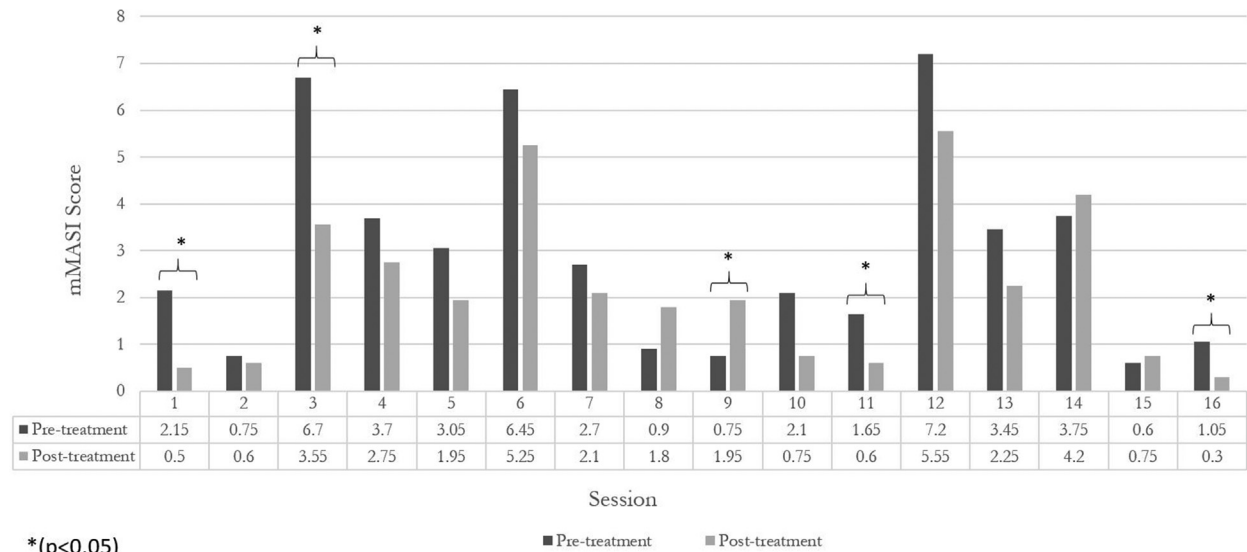
**Table I.** Patient demographics with treatment characteristics and results

Participant	Age, sex	Fitzpatrick skin type	Laser type (no. of sessions)	CO <sub>2</sub> laser parameters	TXA treatment (duration)	Initial mMASI score	Posttreatment mMASI score	Complications
1	54 y, F	III	CO <sub>2</sub> <sup>†</sup> (2)	24 mJ, 50/cm	No	2.15*	0.5*	Swelling
			CO <sub>2</sub> <sup>†</sup>	22 mJ, 75/cm	No	0.75	0.6	No
2	51 y, F	III	CO <sub>2</sub> <sup>†</sup> (3)	22 mJ, 75/cm	Yes (7 wk)	6.7*	3.55*	No
			CO <sub>2</sub> <sup>†</sup> then laser toning <sup>‡</sup> (1)	24 mJ, 75/cm	Yes (11 wk)	3.7	2.75	No
			CO <sub>2</sub> <sup>†</sup>	24 mJ, 75/cm	Yes (16 wk)	3.05	1.95	No
3	59 y, F	IV	CO <sub>2</sub> <sup>†</sup> (1)	22 mJ, 100/cm	Yes (2.4 wk)	6.45	5.25	No
4	66 y, F	III	CO <sub>2</sub> <sup>†</sup> (1) then laser toning <sup>‡</sup> (1)	28 mJ, 50/cm	Yes (2 wk)	2.7	2.1	No
5	53 y, F	III	CO <sub>2</sub> <sup>†</sup> (1) then laser toning <sup>‡</sup> (1)	24 mJ, 100/cm	Yes (1 wk)	0.9	1.8	No
6	35 y, F	III	CO <sub>2</sub> <sup>†</sup> (1) then laser toning <sup>‡</sup> (1)	22 mJ, 75/cm	Yes (4.9 wk)	0.75*	1.95*	Hyperpigmentation
7	47 y, F	III	CO <sub>2</sub> <sup>†</sup> (1) then laser toning <sup>‡</sup> (1)	26 mJ, 50/cm	Yes (4 wk)	2.1	0.75	No
8	61 y, F	IV	CO <sub>2</sub> <sup>†</sup> (1)	50 mJ, 50/cm	No	1.65*	0.6*	No
9	65 y, F	IV	CO <sub>2</sub> <sup>†</sup> (1) then laser toning <sup>‡</sup> (1)	26 mJ, 50/cm	Yes (16 wk)	7.2	5.55	No
10	57 y, F	III	CO <sub>2</sub> <sup>†</sup> (1)	24 mJ, 75/cm	No	3.45	2.25	No
11	61 y, F	III	CO <sub>2</sub> <sup>†</sup> (1) then laser toning <sup>‡</sup> (1)	24 mJ, 100/cm	No	3.75	4.2	No
12	48 y, F	III	CO <sub>2</sub> <sup>†</sup> (2) then laser toning <sup>‡</sup> (1)	24 mJ, 75/cm	No	0.6	0.75	No
			CO <sub>2</sub> <sup>†</sup>	30 mJ, 50/cm	No	1.05*	0.3*	No

\**P* < .05.

<sup>†</sup>Lutronic eCO<sub>2</sub>.

<sup>‡</sup>Lutronic PicoPlus/Spectra.



**Fig 1.** Clinical outcomes of patients with melasma based on individual CO<sub>2</sub> laser sessions. *mMASI*, Modified Melasma Area and Severity Index.

**Table II.** Patient characteristics and treatment results based on treatment types

Data	Fractional CO <sub>2</sub> alone	Fractional CO <sub>2</sub> + laser toning	Fractional CO <sub>2</sub> + TXA	Fractional CO <sub>2</sub> + laser toning + TXA
Number of patients	4	2	2	6
Number of total sessions	5	2	3	6
Sex				
Male	0	0	0	0
Female	3 (100%)	2 (100%)	2 (100%)	6 (100%)
Age, y (mean ± SD)	55.0 ± 4.74	54.5 ± 6.50	55.0 ± 4.00	52.8 ± 10.6
Fitzpatrick skin type				
III	2	2	1	5
IV	1	0	0	1
mMASI score				
Pretreatment (mean ± SD)	1.81 ± 1.064	2.18 ± 2.23	5.40 ± 2.04	2.89 ± 2.38
Posttreatment (mean ± SD)	0.850 ± 0.792	2.48 ± 2.44	3.58 ± 1.65	2.48 ± 1.64
P value	.144	.911	.296	.735

**Conflicts of interest**

None disclosed.

**REFERENCES**

1. Newcomer VD, Lindberg MC, Sternberg TH. A melanosis of the face ("chloasma"). *Arch Dermatol.* 1961;83(2):284-299.
2. Grimes PE. Melasma. Etiologic and therapeutic considerations. *Arch Dermatol.* 1995;131(12):1453-1457.
3. Lee AY. Recent progress in melasma pathogenesis. *Pigment Cell Melanoma Res.* 2015;28(6):648-660.
4. Balkrishnan R, McMichael AJ, Camacho FT, et al. Development and validation of a health-related quality of life

- instrument for women with melasma. *Br J Dermatol.* 2003; 149(3):572-577.
5. Ball Arefiev KL, Hantash BM. Advances in the treatment of melasma: a review of the recent literature. *Dermatol Surg.* 2012;38(7 Pt 1):971-984.
6. McKesey J, Tovar-Garza A, Pandya AG. Melasma treatment: an evidence-based review. *Am J Clin Dermatol.* 2020;21(2):173-225.
7. Shah SD, Aurangabadkar SJ. Laser toning in melasma. *J Cutan Aesthet Surg.* 2019;12(2):76-84.
8. Trivedi MK, Yang FC, Cho BK. A review of laser and light therapy in melasma. *Int J Womens Dermatol.* 2017;3(1):11-20.

9. Aurangabadkar SJ. Optimizing Q-switched lasers for melasma and acquired dermal melanoses. *Indian J Dermatol Venereol Leprol.* 2019;85(1):10-17.
10. Hofbauer Parra CA, Careta MF, Valente NY, de Sanches Osório NE, Torezan LA. Clinical and histopathologic assessment of facial melasma after low-fluence Q-switched neodymium-doped yttrium aluminium garnet laser. *Dermatol Surg.* 2016;42(4):507-512.
11. Na SY, Cho S, Lee JH. Intense pulsed light and low-fluence Q-switched Nd:YAG laser treatment in melasma patients. *Ann Dermatol.* 2012;24(3):267-273.
12. Shin JU, Park J, Oh SH, Lee JH. Oral tranexamic acid enhances the efficacy of low-fluence 1064-nm quality-switched neodymium-doped yttrium aluminum garnet laser treatment for melasma in Koreans: a randomized, prospective trial. *Dermatol Surg.* 2013;39(3 Pt 1):435-442.
13. Arora P, Sarkar R, Garg VK, Arya L. Lasers for treatment of melasma and post-inflammatory hyperpigmentation. *J Cutan Aesthet Surg.* 2012;5(2):93-103.
14. Ho SG, Chan HH. The Asian dermatologic patient: review of common pigmentary disorders and cutaneous diseases. *Am J Clin Dermatol.* 2009;10(3):153-168.
15. Tawfic SO, Abdel Halim DM, Albarbary A, Abdelhady M. Assessment of combined fractional CO<sub>2</sub> and tranexamic acid in melasma treatment. *Lasers Surg Med.* 2019;51(1):27-33.
16. Trelles MA, Velez M, Gold MH. The treatment of melasma with topical creams alone, CO<sub>2</sub> fractional ablative resurfacing alone, or a combination of the two: a comparative study. *J Drugs Dermatol.* 2010;9(4):315-322.
17. Jalaly NY, Valizadeh N, Barikbin B, Yousefi M. Low-power fractional CO<sub>2</sub> laser versus low-fluence Q-switch 1,064 nm Nd:YAG laser for treatment of melasma: a randomized, controlled, split-face study. *Am J Clin Dermatol.* 2014;15(4):357-363.
18. Neeley MR, Pearce FB, Collawn SS. Successful treatment of malar dermal melasma with a fractional ablative CO<sub>2</sub> laser in a patient with type V skin. *J Cosmet Laser Ther.* 2010;12(6):258-260.
19. Wat H, Wu DC, Chan HH. Fractional resurfacing in the Asian patient: current state of the art. *Lasers Surg Med.* 2017;49(1):45-59.
20. Wanitphakdeedecha R, Phuardchantuk R, Manuskiatti W. The use of sunscreen starting on the first day after ablative fractional skin resurfacing. *J Eur Acad Dermatol Venereol.* 2014;28(11):1522-1528.