

Navigating the initial diagnosis and management of adult IgA vasculitis: A review



Brenna G. Kelly, BA,^{a,b} Delaney B. Stratton, PhD, DNP, FNP-BC,^a Iyad Mansour, MD,^c Bekir Tanriover, MD, MPH, MBA,^c Keliagh S. Culpepper, MD,^{a,d} and Clara Curiel-Lewandrowski, MD^a
Tucson, Arizona; and Milwaukee, Wisconsin

Background: IgA vasculitis in adults has not been thoroughly studied. This has left a practice gap related to the management and follow-up of a population that is at an increased risk of comorbidities and potentially poor outcomes. For this reason, it is important to synthesize evidence from the current literature because this can help direct the movement for more robust studies to clarify best practice recommendations.

Objective: We sought to create a narrative review for the practicing dermatologist when diagnosing and leading the care of IgA vasculitis in adult patients.

Methods: A broad literature search was performed with a focus on articles that were published after the introduction of the most updated European Alliance of Associations for Rheumatology/Pediatric Rheumatology International Trials Organization/Pediatric Rheumatology European Society criteria.

Results: The characteristics and management guidelines for IgA vasculitis in adults have been refined, although more rigorous studies are needed to develop best practice recommendations.

Limitations: Because of the lack of sufficient randomized controlled trials on IgA vasculitis in adults, this narrative review is composed of mostly observational, descriptive studies.

Conclusion: Adults with IgA vasculitis are at an increased risk of complicated disease course, necessitating formal diagnostic assessment and clear-cut follow-up recommendations to manage and prevent poor health outcomes related to various comorbidities. (JAAD Int 2022;8:71-8.)

Key words: autoimmune; dermatopathology; direct immunofluorescence; IgA vasculitis; leukocytoclastic vasculitis; vasculitis.

INTRODUCTION

IgA vasculitis (IgAV) is a subset of vasculitis mediated by IgA immune complex deposition and is clinically characterized by palpable purpura, abdominal pain, arthritis, and renal involvement. Because IgAV is more common in children, most literature focuses on pediatrics. However, IgAV in adults might be more common than initially thought because of under-diagnosis, and essential differences exist between children and adults (Table I).¹⁻⁷ IgAV in

adults is also associated with more severe disease, necessitating a greater focus on management.⁸ Currently, the broad approach to the initial workup and management of IgAV is based on comorbidities, associated symptoms, and the approach and expertise of the clinician managing the patient at the time of diagnosis. Because cutaneous eruption is the presenting sign in approximately 75% of cases, dermatologists are specifically positioned to spearhead the care and management of these patients.^{9,10} This is a

From the Divisions of ^aDermatology and Nephrology,^c University of Arizona, Tucson; Derspath Diagnostics, Tucson^d; and Medical College of Wisconsin, Milwaukee.^b

Funding sources: None.

Conflicts of Interest: None disclosed.

IRB approval status: Not applicable.

Accepted for publication May 3, 2022.

Correspondence to: Clara Curiel-Lewandrowski, MD, Division of Dermatology, University of Arizona, 1501 N. Campbell Avenue, Tucson, AZ 85724. E-mail: ccuriel@email.arizona.edu.

2666-3287

© 2022 by the American Academy of Dermatology, Inc. Published by Elsevier Inc. This is an open access article under the CC BY-NC-ND license (<http://creativecommons.org/licenses/by-nc-nd/4.0/>).

<https://doi.org/10.1016/j.jdin.2022.05.004>

critical opportunity because the prevention and management of the associated comorbidities are of great importance. This article aims to develop a narrative review and protocol for dermatologists when diagnosing and leading the care of IgAV in adults.

METHODS

Studies published in English were searched using PubMed, Cumulative Index to Nursing and Allied Health Literature, and Cochrane Library. In combination with the term “Adult IgA vasculitis,” the following search terms were used to obtain articles published in peer-reviewed journals: “causes,” “associations,” “cutaneous,” “laboratory,” “management,” “diagnosis,” “treatment,” “prognosis,” “outcome,” “death,” “relapse,” “remission,” “epidemiology,” “review,” “organ involvement,” “comorbidities,” “malignancy,” “gastrointestinal involvement,” “renal involvement,” “joint involvement,” and “pulmonary involvement.” Referenced studies were also included after being reviewed and accepted by the panel of authors. The publication time frame was focused on articles published between January 2010 and December 2021. This timeframe was chosen for consistency purposes because the updated and improved criteria, created by the working groups European Alliance of Associations for Rheumatology (EULAR), Pediatric Rheumatology International Trials Organization (PRINTO), Pediatric Rheumatology European Society (PRES) (EULAR/PRINTO/PRES) with the help of a formal statistical validation process, was released in 2010 (Table II). The resulting articles were reviewed for eligibility on the basis of their relevance. Data were organized and evaluated by using the following categories: author, title, year, number, study setting, and study design.

ETIOLOGY

The exact cause of IgAV remains unknown. Current evidence suggests that the confluence of antigen exposure in a genetically susceptible individual leads to the deposition of IgA1-dominant immune complexes in target organs.¹¹ Many cases of IgAV in adults are idiopathic; however, infections and drugs are well-described precipitating events. In a recent systematic study on drug-induced IgAV, antibiotics, particularly beta-lactams, were found to

be the most commonly implicated drug predisposing to IgAV in adults. Vaccines, tumor necrosis factor α blockers, antihypertensives, anticoagulants, nonsteroidal anti-inflammatory drugs, and other analgesics were also common.¹² Importantly, glomerulonephritis is less common in drug-induced cases because symptoms often resolve quickly after drug

discontinuation, with only a minority of patients requiring immunosuppressive agents.¹² Interestingly, evidence suggests that a broader range of infections precede IgAV in adults. In a recent study, infections such as pneumonia, pyelonephritis, epididymitis, and cellulitis were found to be present in adults 4 weeks before their IgAV diagnosis.¹³ Obtaining a history of previous illness or infections is essential, especially because patients

may have a less complicated course of IgAV if it has been provoked by an infection that resolves, as opposed to idiopathic IgAV.

History and physical examination

Clinical criteria. In 2010, the new EULAR/PRINTO/PRES classification criteria for diagnosing IgAV in pediatric patients were found to have improved sensitivity and specificity compared with the previously used American College of Rheumatology criteria. In 2016, Hocevar et al¹⁴ trialed these diagnostic criteria in an adult cohort and found a sensitivity of 100% and a specificity of 87%. The EULAR/PRINTO/PRES criteria was also validated in a recent study of IgAV in adults with an overall sensitivity of 99% ($N = 85$).¹⁵ It is important to note that constitutional symptoms, such as fever, weight loss, and fatigue, are not included in the EULAR criteria. Constitutional symptoms are important to assess in adults because they are more commonly seen in this cohort.¹⁶ Although the EULAR/PRINTO/PRES criteria are useful in diagnosing IgAV in adults, several studies have stressed the need for a specific criterion for adults.

Cutaneous findings. Symmetric palpable purpura, often with localized subcutaneous edema, is the most common presentation of skin eruption observed in adults with IgAV.^{8,17} It is most often located on the lower limbs; however, purpura on the trunk and upper extremities is not uncommon and the rash may even extend to involve a large surface area.^{10,17} Compared with children, the rash of IgAV in

CAPSULE SUMMARY

- Protocols related to the diagnosis and management of adult patients with IgA vasculitis have not been clearly defined in part because of the lack of randomized control trials in this population.
- This review analyzes and summarizes the available literature to develop more extensive recommendations related to IgA vasculitis in adults.

Abbreviations used:

IgAV:	IgA vasculitis
EULAR:	European Alliance of Associations for Rheumatology
PRINTO:	Pediatric Rheumatology International Trials Organization
PRES:	Pediatric Rheumatology European Society
LCV:	leukocytoclastic vasculitis
DIF:	direct immunofluorescence
GI:	gastrointestinal
IgAV-N:	IgA vasculitis nephropathy

adults is more likely to have variations such as bullae, pustules, and necrotic or hemorrhagic purpura.^{10,17,18} Lesions can be asymptomatic, painful, or pruritic.^{19,20}

Diagnosis. Biopsies of IgAV typically reveal leukocytoclastic vasculitis (LCV) primarily affecting the small superficial vessels. Lymphocytic vasculitis and perivascular inflammation, which are other phases in the LCV process, can also be seen.²¹⁻²⁴ Because LCV is not specific for IgAV, direct immunofluorescence (DIF) is often ordered in conjunction. Most cases of IgAV in adults are positive for IgA deposition; however, a subset of IgAV in adults may yield a negative DIF.^{25,26} This may be related to the time of biopsy relative to lesion onset because IgA can degrade in older necrotic lesions.²⁵ Biopsy recommendations are shown in Fig 1. DIF should be performed in newer lesions because as more time passes from lesion onset, the likelihood of a false negative increases.^{24,27} In contrast, hematoxylin and eosin staining should be performed for the samples obtained from established lesions because fully evolved lesions are more likely to have all the diagnostic features of LCV.²⁷ This is a controversial point because some publications advocate for obtaining lesional samples over perilesional samples for DIF. In contrast, others recommend perilesional biopsies for DIF and lesional samples for hematoxylin and eosin staining.^{22,24,28,29} Additional studies comparing lesional and perilesional biopsies for DIF are needed to determine whether sampling location could account for negative DIF results.²⁵ Lastly, despite all these considerations, DIF may still be negative. For this reason, it is helpful to carefully consider the clinical history and presentation when there is high suspicion for IgAV in adult patients, even in the setting of a negative DIF. Although predominant IgA deposition is not an essential criterion of the EULAR criteria, confirmation biopsy has been proposed given that the cutaneous presentation is more likely to be atypical in adults.¹⁰ Furthermore, if there is high clinical suspicion, a

full panel DIF may not be needed. This is an important consideration given that a standard DIF panel costs around \$350 to \$450 in the United States.^{26,29} It has been previously asserted that DIF results are rarely contributory except in the setting of IgAV, and some have ascertained that DIF is best utilized when IgA is the sole immunoreactant or, in some cases, in combination with immunoglobulin M.²⁹ This strategy may be appropriate in certain situations and can be cost saving.

Management of cutaneous lesions. The cutaneous manifestations of IgAV in adults are often reported as self-limited, with resolution typically around 2 to 3 weeks.^{10,30} However, in several studies and reviews, some skin eruptions associated with IgAV in adults were found to be refractory and challenging to treat.³¹ Unfortunately, there is no specific treatment for skin purpura, and most recommendations are based on clinical experience.^{24,31} For noncomplicated cutaneous manifestations, rest, elevation, compression stockings, and analgesia are recommended.^{8,19,20} Patients may try topical steroids as well. The use of oral corticosteroids in treating the cutaneous manifestations of IgAV is a matter of debate; some reviews note that they are ineffective for skin purpura,⁸ whereas others report that they may be required for painful or ulcerative disease and that they help prevent new lesion formation.³² There is a broad range of treatments for severe, refractory, or relapsing skin eruptions, which stresses the need for large randomized control trials to clarify recommendations. For now, if resting and analgesia are ineffective in managing the cutaneous symptoms, patients can try topical steroids and colchicine 1 mg/d in patients without gastrointestinal (GI) symptoms, or even a low dose prednisone taper. Covering necrotic or hemorrhagic lesions with petrolatum can facilitate healing. Patients who respond incompletely to steroids or who cannot taper without disease flare may try steroid-sparing agents such as dapsone, colchicine, or azathioprine because these medications have been attempted with some benefit in these situations.³² Despite this, a recent review from the Center for Vasculitis Care and Research at Cleveland Clinic found that skin lesions in adults with IgAV are frequently chronic, difficult, and even refractory to multiple immunosuppressive therapies. They suggest a combination of glucocorticoids and an immunosuppressive agent, such as rituximab or mycophenolate mofetil, to control refractory skin lesions in adults.¹⁰ Ultimately, the use of any therapy must be weighed against the patient's comorbidities and symptoms.

Table I. Differences in IgA vasculitis between children and adults

Parameter	Children	Adults
Incidence	10-20 per 100,000 ¹⁹ with peak incidence around ages of 4-6 years, and 90% of cases occurring under the age of 10 years. ¹	0.8-5.1 per 100,000 with increased frequency in the fifth and sixth decades of life. ² Male-to-female ratio of 1.5. ²⁰
IgAV-N incidence	IgAV-N occurs in 20%-54% of IgAV in children.	Occurs in 45%-85% of IgAV cases in adults. More severe with lower remission rates. ³³ Adults have an 11% risk of ESRD and a 13% risk of severe renal failure. ⁴⁴
Natural history	Generally benign and self-limited, with symptoms resolving within 1 month. 94% of children have complete recovery by 2 years. ¹ Corticosteroid dependence and refractory disease more frequent as onset age increases. ³	Roughly three-fourths of patients will have some type of systemic involvement. ^{4,18} Renal involvement at disease onset and when disease fully established more common. ⁴¹
Precipitating factors	Precipitating factor such as infection and/or medication identified in around 50% of cases. ^{5,41} Upper respiratory tract infection especially common, more common in fall and winter. ^{2,6,41}	More often idiopathic, with precipitating factors identified in around a quarter of cases. ⁴¹ Drug implicated cases have been reported in the range of 12.5%-26%, whereas preceding infections have been described in 23%-35% of cases. ^{9,43}
Prognosis	Long-term complications and relapses are rare, with a favorable outcome seen in 95% of the pediatric population. ¹⁰	Relapses are frequent (30%) and most of the time cutaneous (90%). ⁷ Recalcitrant disease is significantly more common than in children, especially in adults with renal manifestations. ¹³ Spontaneous remission more likely in patients who have milder disease. ⁴⁴ Increased mortality in older patients with IgAV. ^{45,48}

ESRD, End-stage renal disease; IgAV, IgA vasculitis; IgAV-N, IgA vasculitis nephropathy.

Systemic workup and management

Renal involvement. Patients with IgAV usually develop renal manifestations within a few weeks after the initial presentation; however, this can be delayed several months.³³ Microscopic or macroscopic hematuria with or without red blood cell casts is the earliest and most sensitive test suggestive of IgA vasculitis nephropathy (IgAV-N).⁸ Other manifestations include proteinuria that ranges from mild to severe. The incidence of acute kidney injury according to Kidney Disease Improving Global Outcomes guidelines³⁴ can reach up to 32% in adults at the time of diagnosis but is rare in children.³⁵⁻³⁷ Hypertension is typically noted in one-third of cases.⁸ Chronic kidney disease (stages 3-5), according to the Kidney Disease Improving Global Outcomes classification,³⁸ is a common, long-term complication, with 10% to 30% of patients with IgAV-N developing end-stage renal disease at 15 years follow-up.^{39,40}

Because the majority of patients with IgAV-N manifest symptoms early, immediate screening is

critical and should include urinalysis, serum creatinine with estimated glomerular filtration rate, and blood pressure monitoring. The timeline for follow-up testing is detailed in Fig 2. Monitoring should be extended as long as clinical or biologic abnormalities persist.

Evidence-based management of IgAV-N is limited. Currently, there are no randomized control trials to demonstrate the effectiveness of steroids in preventing IgAV-N in adults or children. In fact, the 2021 Kidney Disease Improving Global Outcomes guidelines have recommended against using glucocorticoids to prevent nephritis.

Patients with elevated blood pressure and/or proteinuria >0.5 g/d should be treated on the basis of the recommendations in Fig 2. Decision to manage these patients is up to the individual clinician, and subspecialty referrals can be made earlier on the basis of comfort level.

GI involvement. GI involvement has been reported in 37% to 65% of IgAV cases in adults. The most common symptom is colicky abdominal

Table II. European Alliance of Associations for Rheumatology/Pediatric Rheumatology International Trials Organization/ Pediatric Rheumatology European Society classification criteria for IgA vasculitis*

Criterion	Definition
Purpura (mandatory)	Purpura (commonly palpable or in crops) or petechiae, with lower limb predominance, not related to thrombocytopenia. [†]
Abdominal pain	Diffuse abdominal colicky pain with acute onset assessed by history and physical examination; may include intussusception and gastrointestinal bleeding.
Histopathology	Typically leukocytoclastic vasculitis with predominant IgA deposits or proliferative glomerulonephritis with predominant IgA deposits.
Arthritis or arthralgias	Arthritis of acute onset defined as joint swelling or joint pain with limitation on motion; arthralgia of acute onset defined as joint pain without joint swelling or limitation on motion.
Renal involvement	Proteinuria >0.3 g/24 h or >30 mg/mmol or urine albumin/creatinine ratio on a spot morning sample; hematuria or red blood cell casts: >5 red blood cells/high power field or red blood cells casts in the urinary sediment or ≥ 2+ on dipstick.

*The presence of purpura with lower limb predominance and at least 1 of the other 4 criteria yields a sensitivity of 100% and a specificity of 87%.

[†]For purpura with atypical distribution, a demonstration of an IgA deposit in a biopsy specimen is required.

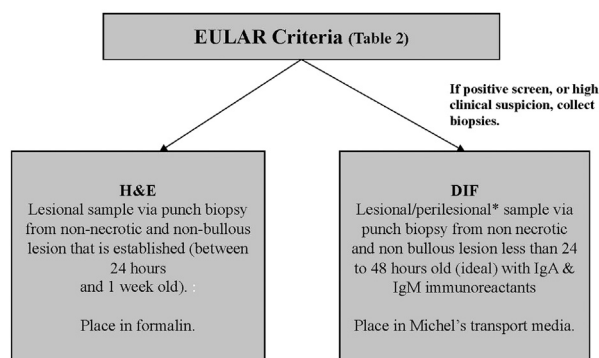


Fig 1. Biopsy recommendations for the workup of IgA vasculitis in adults. *DIF*, Direct immunofluorescence; *EULAR*, European Alliance of Associations for Rheumatology; *H&E*, hematoxylin and eosin; *IgM*, immunoglobulin M. *Further study is required to determine the optimal location for DIF biopsy.

pain,^{9,17,41,42} followed by hematochezia, diarrhea, nausea, and vomiting.^{42,43} These symptoms are related to vasculitis-induced bowel ischemia and edema.⁸ Severe GI involvement, often defined as severe bloody diarrhea, ileus, or the need for surgical intervention, is rare. Ileus is reported 6.5% to 9% of the time, whereas surgical intervention is reported 2% to 4% of the time.^{9,42} Mortality from IgAV-related GI involvement is rare (0.7%-1%)^{14,42} and most commonly because of mesenteric ischemia or sepsis-related bowel perforation. Bloody stool or microcytic anemia warrants further investigation. Baseline laboratory and management recommendations are shown in Fig 3. Intestinal bleeding and perforation are potential complications, and 1 study recommends that any evidence of GI involvement be

worked up with computed tomography scans and/or GI endoscopies ($N = 137$).⁴² Others have proposed checking plasma factor XIII activity and fecal occult blood test in patients with abdominal symptoms.¹³ If there is no GI involvement, patients should monitor for these symptoms and immediately report them if identified. Abdominal involvement is more common once the disease is fully established.⁴¹ Prior literature suggests that the majority of nonsevere GI involvement spontaneously improve.⁴² For this reason, glucocorticoids, factor XIII, and other immunosuppressants are not appropriate to initiate; however, they may have a role in more serious complications, such as an acute surgical abdomen.

Joint involvement. IgAV-associated joint involvement in adults has been reported in 30% to 60% of cases.^{44,45} It is transient, migratory, and overall nondestructive.^{20,21} The knees and ankles are the most commonly affected joints.^{13,43} Assessing for joint involvement when taking a patient's history may be complicated given that many older patients will likely have arthritis or arthralgias at baseline. The EULAR/PRINTO/PRES classification criteria define arthritis or arthralgias as those conditions that have an acute onset; however, an exact time frame is not described. Similarly, many previous studies have not elucidated a time frame when inquiring about joint involvement. For this reason, in patients with a history of arthritis, it may be helpful to ask whether there has been an acute onset, worsening, or migration of the pain.

Pain management. Although nonsteroidal anti-inflammatory drugs have been used in the past for pain control in IgAV, recently, several reviews have recommended avoiding these drugs because of a risk

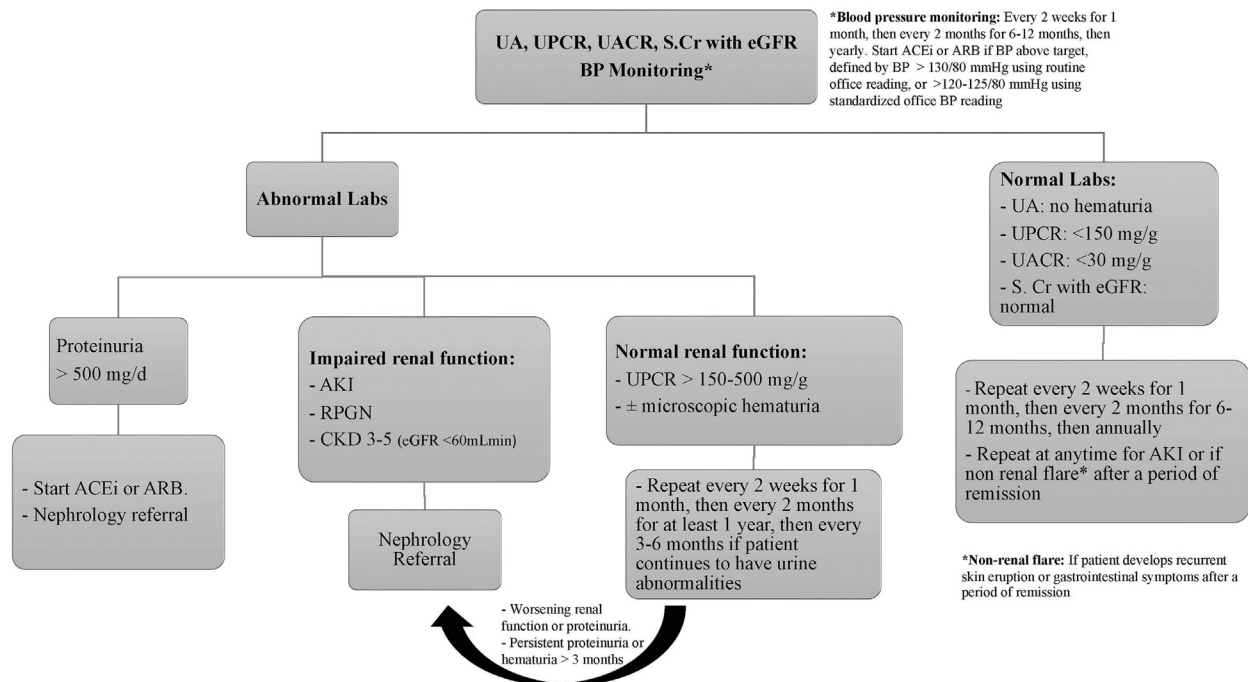


Fig 2. Screening protocol for renal involvement in adults with IgA vasculitis. *ACEi*, Angiotensin converting enzyme inhibitor; *AKI*, acute kidney injury; *ARB*, angiotensin II receptor blocker; *BP*, blood pressure; *CKD*, chronic kidney disease; *eGFR*, estimated glomerular filtration rate; *RPGN*, rapidly proliferative glomerulonephritis; *S.Cr*, serum creatinine; *UA*, urinalysis; *UACR*, urine albumin-creatinine ratio; *UPCR*, urine protein-creatinine ratio.

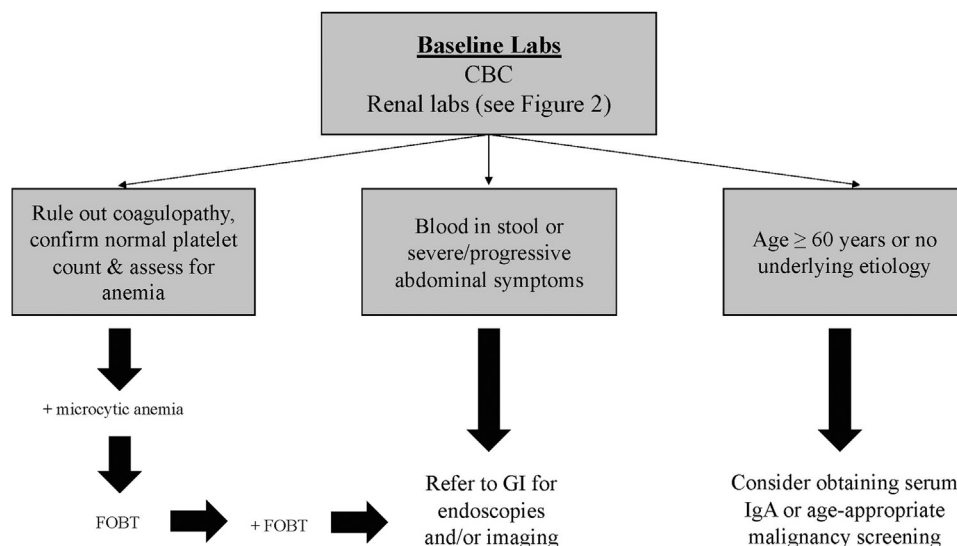


Fig 3. Suggested management guidelines for IgA vasculitis in adults. *CBC*, Complete blood cell count; *FOBT*, fecal occult blood test; *GI*, gastrointestinal.

of renal involvement and GI bleeding.^{10,20} Therefore, oral acetaminophen is an appropriate option for treating arthralgias⁴⁶ and possibly mild abdominal pain. For severe or refractory pain, oral steroids may be trialed.

Malignancy. The relationship between IgAV in adults and underlying malignancy is difficult to reconcile. Several studies, because of their different timeframes and screening methods, have reported varying results. Incidence rates have ranged from 2.5% (*N* = 81;

$N = 85$)^{2,15} to 10% ($N = 260$).^{44,47} Most cancers associated with IgAV are solid organ, primarily mucosal, which argues for a related pathogenesis given the IgA mucosal connection.⁴⁷ In addition, when cancers are diagnosed in patients with IgAV, they are typically found in the 6 months preceding or following IgAV diagnosis.⁴⁷ Interestingly, 1 consistent finding is the identification of higher serum IgA levels in patients with IgAV with malignancy.^{13,47} Hankard et al⁴⁷ found that adults with malignancy-associated IgAV had median serum IgA levels of approximately 4.5 mg/dL compared with 3.6 mg/dL in patients without associated cancer ($P < .0083$, $N = 30$). For this reason, checking the serum IgA level has been proposed. Studies have also found that adult patients with IgAV with associated cancers tend to be older, and screening has been recommended in older and elderly patients.^{13,17} Lastly, because IgAV in adults can be related to an underlying etiology, such as infection or new medication use, cancer screening in patients without an identifiable underlying etiology should be considered.

Overall prognosis. Deciphering the true mortality rate for IgAV in adults is complex given that studies vary in treatment, follow-up duration, and design/setting. Mortality rates range anywhere from 2.4% in a study without a matched group⁹ to 51.3% in a strictly hospitalized adult population with IgAV with a reference group.⁴⁸ There is a risk of life or organ-threatening manifestations during the acute phase of the disease—most notably from intestinal ischemia.¹⁴ Although a rare complication, pulmonary hemorrhage is associated with high mortality and morbidity. Hemoptysis, drop in hemoglobin, and chest infiltrates are the most common presenting findings.⁴⁹ Therefore, patients with hemoptysis should be sent for chest x-ray. Relapse rates in IgAV range between 15% and 30%; however, this data's accuracy has been questioned given varying definitions.¹⁶ In most studies, relapse is defined as the reappearance of clinical signs of IgAV after a symptom-free period of at least 1 month.⁵⁰ Several studies have attempted to identify predictors of relapse; however, the results have been divergent.^{16,41,51}

CONCLUSION

IgAV is a complex disease and should be medically approached as a systemic process that warrants thorough clinical and laboratory assessment. This is essential to identify patients with extracutaneous involvement who require specialized care and are at risk of complications. Because IgAV in adults is uncommon relative to pediatric IgAV, the literature has historically focused on the pediatric end of the spectrum. Fortunately, this gap

in the literature has been identified, and there is an ongoing effort to carry out randomized control trials in adults with IgAV to help direct their management.

REFERENCES

1. Oni L, Sampath S. Childhood IgA vasculitis (Henoch Schonlein purpura)-advances and knowledge gaps. *Front Pediatr*. 2019;7:257.
2. Hočevar A, Rotar Z, Ostrovšnik J, et al. Incidence of IgA vasculitis in the adult Slovenian population. *Br J Dermatol*. 2014;171(3):524-527.
3. Liao CH, Tsai M, Yang YH, Chiang BL, Wang LC. Onset age is a risk factor for refractory pediatric IgA vasculitis: a retrospective cohort study. *Pediatr Rheumatol Online J*. 2020;18(1):86.
4. Poterucha TJ, Wetter DA, Gibson LE, Camilleri MJ, Lohse CM. Correlates of systemic disease in adult Henoch-Schönlein purpura: a retrospective study of direct immunofluorescence and skin lesion distribution in 87 patients at Mayo Clinic. *J Am Acad Dermatol*. 2012;67(4):612-616.
5. Wang JJ, Xu Y, Liu FF, et al. Association of the infectious triggers with childhood Henoch-Schonlein purpura in Anhui province, China. *J Infect Public Health*. 2020;13(1):110-117.
6. Nossent J, Raymond W, Keen H, Inderjeeth C, Preen DB. Hospitalisation rates and characteristics for adult and childhood immunoglobulin A vasculitis in Western Australia. *Intern Med J*. 2019;49(4):475-481.
7. Pillebout EA-V, Alexandra. Efficacy of colchicine to prevent skin relapses in adult IgA vasculitis. National Library of Medicine; 2019.
8. Audemard-Verger A, Pillebout E, Guillevin L, Thervet E, Terrier B. IgA vasculitis (Henoch-Schönlein purpura) in adults: diagnostic and therapeutic aspects. *Autoimmun Rev*. 2015;14(7):579-585.
9. Hočevar A, Rotar Ž, Jurčić V, Čučnik S, Tomsič M. Patient age, gender and extent of purpura may suggest short-term outcomes in adults with IgA vasculitis. *Rheumatology (Oxford)*. 2015;54(7):1330-1332.
10. Yaseen K, Herlitz LC, Villa-Forte A. IgA vasculitis in adults: a rare yet challenging disease. *Curr Rheumatol Rep*. 2021;23(7):50.
11. Heineke MH, Ballering AV, Jamin A, Ben Mkaddem S, Monteiro RC, Van Egmond M. New insights in the pathogenesis of immunoglobulin A vasculitis (Henoch-Schönlein purpura). *Autoimmun Rev*. 2017;16(12):1246-1253.
12. Rasmussen C, Tisseyre M, Garon-Czmlil J, et al. Drug-induced IgA vasculitis in children and adults: revisiting drug causality using a dual pharmacovigilance-based approach. *Autoimmun Rev*. 2021;20(1):102707.
13. Hitomi K, Izaki S, Teraki Y, et al. Characterization of adult-type IgA vasculitis (Henoch-Schönlein purpura): a retrospective study of 122 cases. *Open Dermatol J*. 2014;8:51-59.
14. Hočevar A, Rotar Z, Kežar N, Tomsic M. A model predicting short term severity of IgA vasculitis in adults. *J Clin Exp Dermatol Res*. 2017;8(3):397.
15. Van de Perre E, Jones RB, Jayne DRW. IgA vasculitis (Henoch-Schönlein purpura): refractory and relapsing disease course in the adult population. *Clin Kidney J*. 2021;14(8):1953-1960.
16. Gazel U, Colak S, Sari A, et al. Damage assessment in adult IgA vasculitis. Cross-sectional results of a multicentre cohort. *Clin Exp Rheumatol*. 2020;38(suppl 124 2):155-160.
17. Jithpratuck W, Elshenawy Y, Saleh H, Youngberg G, Chi DS, Krishnaswamy G. The clinical implications of adult-onset Henoch-Schonlein purpura. *Clin Mol Allergy*. 2011;9(1):9.

18. Hočevar A, Tomšič M, Jurčić V, Perdan Pirkmajer K, Rotar Ž. Predicting gastrointestinal and renal involvement in adult IgA vasculitis. *Arthritis Res Ther*. 2019;21(1):302.
19. Fraticelli P, Benfaremo D, Gabrielli A. Diagnosis and management of leukocytoclastic vasculitis. *Intern Emerg Med*. 2021;16(4):831-841.
20. Maritati F, Canzian A, Fenaroli P, Vaglio A. Adult-onset IgA vasculitis (Henoch-Schönlein): update on therapy. *Presse Med*. 2020;49(3):104035.
21. Hetland LE, Susrud KS, Lindahl KH, Bygum A. Henoch-Schönlein purpura: a literature review. *Acta Derm Venereol*. 2017;97(10):1160-1166.
22. Nandeesh B, Tirumalae R. Direct immunofluorescence in cutaneous vasculitis: experience from a referral hospital in India. *Indian J Dermatol*. 2013;58(1):22-25.
23. Hočevar A, Rotar Z, Jurčić V, et al. IgA vasculitis in adults: the performance of the EULAR/PRINTO/PRES classification criteria in adults. *Arthritis Res Ther*. 2016;18:58.
24. Shavit E, Alavi A, Sibbald RG. Vasculitis-what do we have to know? A review of literature. *Int J Low Extrem Wounds*. 2018;17(4):218-226.
25. Linskey KR, Kroshinsky D, Mihm MC Jr, Hoang MP. Immunoglobulin-A-associated small-vessel vasculitis: a 10-year experience at the Massachusetts General Hospital. *J Am Acad Dermatol*. 2012;66(5):813-822.
26. Poudel P, Adams SH, Mirchia K, Jain H, Eranki A. IgA negative immunofluorescence in diagnoses of adult-onset Henoch-Schönlein purpura. *Proc (Bayl Univ Med Cent)*. 2020;33(3):436-437.
27. Elston DM, Stratman EJ, Miller SJ. Skin biopsy: biopsy issues in specific diseases. *J Am Acad Dermatol*. 2016;74(1):1-16.
28. Flood D, Barber B, Mileta NR. Diagnosing IgA vasculitis in the active duty population: the importance of early diagnosis and proper biopsy site selection. *Mil Med*. 2018;183(9-10):e663-e666.
29. Feasel P, Billings SD, Bergfeld WF, Piliang MP, Fernandez AP, Ko JS. Direct immunofluorescence testing in vasculitis-a single institution experience with Henoch-Schönlein purpura. *J Cutan Pathol*. 2018;45(1):16-22.
30. Bouillier K, Audia S, Devilliers H, et al. Etiologies and prognostic factors of leukocytoclastic vasculitis with skin involvement: a retrospective study in 112 patients. *Medicine (Baltimore)*. 2016;95(28):e4238.
31. Sugino H, Sawada Y, Nakamura M. IgA vasculitis: etiology, treatment, biomarkers and epigenetic changes. *Int J Mol Sci*. 2021;22(14):7538.
32. Micheletti RG, Pagnoux C. Management of cutaneous vasculitis. *Presse Med*. 2020;49(3):104033.
33. Pillebout E, Sunderkötter C. IgA vasculitis. *Semin Immunopathol*. 2021;43(5):729-738.
34. Kidney Disease: Improving Global Outcomes (KDIGO) Acute Kidney Injury Work Group. KDIGO Clinical Practice Guideline for Acute Kidney Injury. *Kidney International Supplements*. 2012;2(1):8-12.
35. Berthelot L, Jamin A, Viglietti D, et al. Value of biomarkers for predicting immunoglobulin A vasculitis nephritis outcome in an adult prospective cohort. *Nephrol Dial Transplant*. 2018;33(9):1579-1590.
36. Pillebout E, Jamin A, Ayari H, et al. Biomarkers of IgA vasculitis nephritis in children. *PLoS One*. 2017;12(11):e0188718.
37. Pillebout E, Thervet E, Hill G, Alberti C, Vanhille P, Nochy D. Henoch-Schönlein purpura in adults: outcome and prognostic factors. *J Am Soc Nephrol*. 2002;13(5):1271-1278.
38. Work Group Membership. *Kidney Int Suppl (2011)*. 2012;2(1):2.
39. Coppo R, Mazzucco G, Cagnoli L, Lupo A, Schena FP. Long-term prognosis of Henoch-Schönlein nephritis in adults and children. Italian Group of Renal Immunopathology Collaborative study on Henoch-Schönlein purpura. *Nephrol Dial Transplant*. 1997;12(11):2277-2283.
40. Coppo R, Andrulli S, Amore A, et al. Predictors of outcome in Henoch-Schönlein nephritis in children and adults. *Am J Kidney Dis*. 2006;47(6):993-1003.
41. Calvo-Río V, Loricera J, Mata C, et al. Henoch-Schönlein purpura in northern Spain: clinical spectrum of the disease in 417 patients from a single center. *Medicine (Baltimore)*. 2014;93(2):106-113.
42. Audemard-Verger A, Pillebout E, Amoura Z, et al. Gastrointestinal involvement in adult IgA vasculitis (Henoch-Schönlein purpura): updated picture from a French multicentre and retrospective series of 260 cases. *Rheumatology (Oxford)*. 2020;59(10):3050-3057.
43. Kang Y, Park JS, Ha YJ, et al. Differences in clinical manifestations and outcomes between adult and child patients with Henoch-Schönlein purpura. *J Korean Med Sci*. 2014;29(2):198-203.
44. Audemard-Verger A, Terrier B, Dechartres A, et al. Characteristics and management of IgA vasculitis (Henoch-Schönlein) in adults: data from 260 patients included in a french multicenter retrospective survey. *Arthritis Rheumatol*. 2017;69(9):1862-1870.
45. Audemard-Verger A, Pillebout E, Baldolli A, et al. Impact of aging on phenotype and prognosis in IgA vasculitis. *Rheumatology (Oxford)*. 2021;60(9):4245-4251.
46. Reamy BV, Servey JT, Williams PM. Henoch-Schönlein purpura (IgA vasculitis): rapid evidence review. *Am Fam Physician*. 2020;102(4):229-233.
47. Hankard A, Michot JM, Terrier B, et al. New insights on IgA vasculitis with underlying solid tumor: a nationwide French study of 30 patients. *Clin Rheumatol*. 2021;40(5):1933-1940.
48. Nossent J, Raymond W, Keen HI, Preen D, Inderjeeth C. Morbidity and mortality in adult-onset IgA vasculitis: a long-term population-based cohort study. *Rheumatology (Oxford)*. 2021;61(1):291-298.
49. Rajagopala S, Shobha V, Devaraj U, D'Souza G, Garg I. Pulmonary hemorrhage in Henoch-Schönlein purpura: case report and systematic review of the English literature. *Semin Arthritis Rheum*. 2013;42(4):391-400.
50. Villatoro-Villar M, Crowson CS, Warrington KJ, Makol A, Ytterberg SR, Koster MJ. Clinical characteristics of biopsy-proven IgA vasculitis in children and adults: a retrospective cohort study. *Mayo Clin Proc*. 2019;94(9):1769-1780.
51. Byun JW, Song HJ, Kim L, Shin JH, Choi GS. Predictive factors of relapse in adult with Henoch-Schönlein purpura. *Am J Dermatopathol*. 2012;34(2):139-144.