

# Electrodiagnostic Assessment of Uncommon Mononeuropathies



Ghazala Hayat, MD<sup>a,\*</sup>, Jeffrey S. Calvin, MD<sup>b</sup>

## KEYWORDS

- Axillary neuropathy • Musculocutaneous neuropathy • Suprascapular neuropathy
- Sciatic neuropathy • Obturator neuropathy • Proximal neuropathies of limbs
- Uncommon neuropathies

## KEY POINTS

- Uncommon upper and lower extremities mononeuropathies may be challenging to diagnose because they may mimic disorders involving cervical or lumbosacral roots, plexopathies, or non-neuromuscular disorders.
- Electrodiagnostic studies play an important role in the diagnosis, localization, and prognosis of uncommon mononeuropathies.
- Knowledge of anatomy of nerves in the upper and lower extremities that are not routinely examined and performance of appropriate electrodiagnostic testing.
- In these technically difficult electrodiagnostic studies monitoring for technical problems is critical for accurate performance and interpretation of the studies.

## INTRODUCTION

Carpal tunnel syndrome (CTS), ulnar neuropathy at the elbow, and peroneal neuropathy are the most common mononeuropathies; however other individual nerves in the upper extremities (UE) and lower extremities (LE) may also be injured by various processes. These uncommon mononeuropathies may be less readily diagnosed owing to unfamiliarity with the presentations and vague symptoms. Electrodiagnostic (EDX) studies are essential in the evaluation of uncommon mononeuropathies and can assist in localization and prognostication. However, they can also be challenging, because stimulation at the proximal sites is difficult and well-validated reference values are not available. This article reviews the EDX assessment of several uncommon UE and LE mononeuropathies.

---

The authors have no conflicts of interest to disclose.

<sup>a</sup> Saint Louis University School of Medicine, Saint Louis, MO, USA; <sup>b</sup> Department of Neurology, Saint Louis University School of Medicine, Saint Louis, MO, USA

\* Corresponding author.

E-mail address: [ghazala.hayat@health.slu.edu](mailto:ghazala.hayat@health.slu.edu)

Neurol Clin 39 (2021) 957–981

<https://doi.org/10.1016/j.ncl.2021.06.005>

[neurologic.theclinics.com](http://neurologic.theclinics.com)

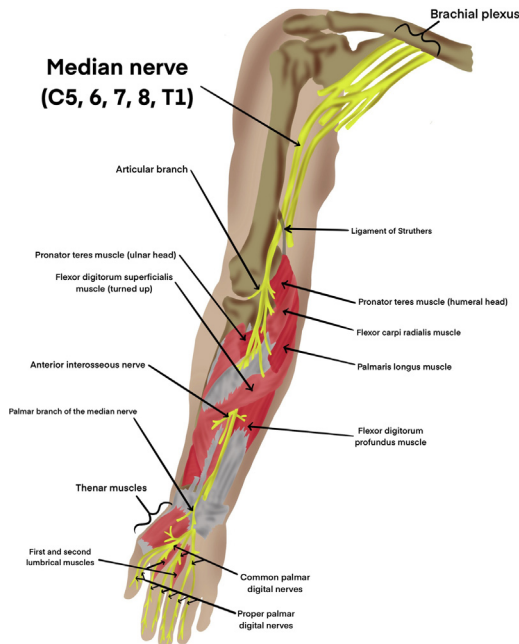
0733-8619/21/© 2021 Elsevier Inc. All rights reserved.

## PROXIMAL MEDIAN NEUROPATHY

Disorders involving the median nerve proximal to the wrist are much less common than median neuropathy at the wrist or CTS.<sup>1</sup> In a series from Cleveland Clinic, only 0.2% of patients referred for EDX had findings of a proximal median neuropathy.<sup>2</sup> The median nerve comprises of branches from the C5 to T1 roots derived from medial and lateral cords of the brachial plexus.<sup>3</sup> The nerve enters the arm in the axilla at the inferior margin of the teres major muscle, passes lateral to the brachial artery and between the biceps brachii and brachialis muscles (Fig. 1). It runs medial to the brachial artery in the distal arm into the cubital fossa, passing between the heads of the pronator teres (PT), and travels between the flexor digitorum superficialis (FDS) and flexor digitorum profundus (FDP) muscles. In the cubital fossa, it gives off branches to the flexor carpi radialis (FCR), palmaris longus (PL), and FDS muscles. The anterior interosseous branches from the median nerve in the upper forearm, innervating the flexor pollicis longus (FPL), lateral one-half of the FDP, and the pronator quadratus (PQ). In the forearm, the median nerve also gives off sensory branches, including the palmar cutaneous branch in the distal forearm, supplying sensation to the thenar eminence. It then enters the hand in the carpal tunnel, and supplies the muscles of the thenar eminence, as well as giving off digital branches to the thumb, index, middle, and lateral ring fingers.

### Etiologies and Sites of Compression

Proximal median neuropathy can occur from diverse etiologies, including trauma, external compression from casting, venipuncture, tumors or hematoma, or as part of a more diffuse process such as Parsonage–Turner syndrome or multifocal motor neuropathy with conduction block.<sup>1,4</sup> Nerve entrapment can occur (1) in the upper



**Fig. 1.** Median nerve anatomy.

arm from a bony spur originating from the humeral shaft just proximal to the medial epicondyle, and a fibrous structure (ligament of Struthers) connecting the spur to the medial epicondyle<sup>4-6</sup>; (2) by a fibrous band (lacertus fibrosus) that runs between the forearm flexor muscles and the biceps tendon; (3) within the PT muscle, particularly with anatomic variants of additional fibrous bands within the muscle; or (4) beneath the sublimus bridge of the FDS muscle.

### Clinical Features

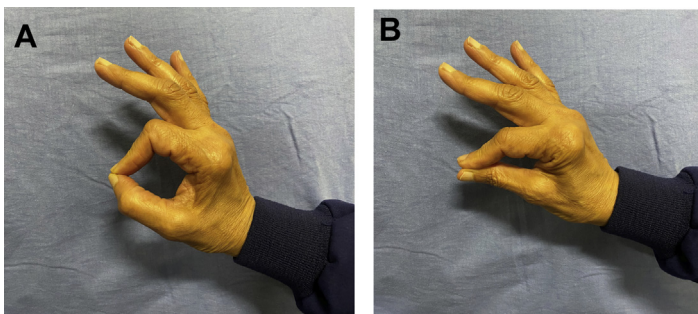
The clinical features of proximal median neuropathies depend on the etiology and the specific site of the lesion.<sup>2,7</sup> In proximal lesions, sensory disturbance usually involves the entire median distribution, including the hand, and sensory loss of the proximal thenar eminence indicates a more proximal lesion than the wrist. The distribution of weakness also depends on the site of the lesion and may involve median innervated forearm and/or hand muscles.

Entrapment at the ligament of Struthers produces a syndrome characterized by pain and paresthesia in the volar surface of the forearm and the median innervated digits that is exacerbated by elbow extension or forearm supination. These positioning maneuvers may also attenuate the radial pulse because the brachial artery runs under the ligament of Struthers in the neurovascular bundle with the median nerve. Subtle sensory loss may occur over the thenar eminence and weakness may be seen in the median innervated muscles in the forearm. Features in pronator syndrome are nonspecific and often includes pain in the forearm that radiates proximally. A positive Tinel sign may be present over the PT muscle. Symptoms may be exacerbated by pronation–supination of the forearm. Mild weakness of the median-innervated muscles is not uncommon, but severe weakness is rare.

The anterior interosseous nerve (AION) syndrome presents with unique clinical features of weakness of thumb flexion, finger flexion for digits 2 and 3, and pronation, resulting in a “teardrop” shape when attempting to make an “OK” sign<sup>8,9</sup> (Fig. 2A, B). Although there may be deep forearm pain or subjective sensory symptoms, cutaneous sensation remains intact.

### Electrophysiologic Features

EDX studies are useful to localize the site of lesion along the median nerve and exclude other localizations<sup>2</sup> (Table 1). In processes characterized by axon degeneration, the median motor nerve conduction studies recording from the abductor pollicis brevis



**Fig. 2.** Demonstration of clinical findings in anterior interosseous nerve syndrome. (A) Normal “OK” sign. (B) In AION syndrome, weakness of flexor pollicis longus and flexor digitorum profundus would produce a teardrop sign.

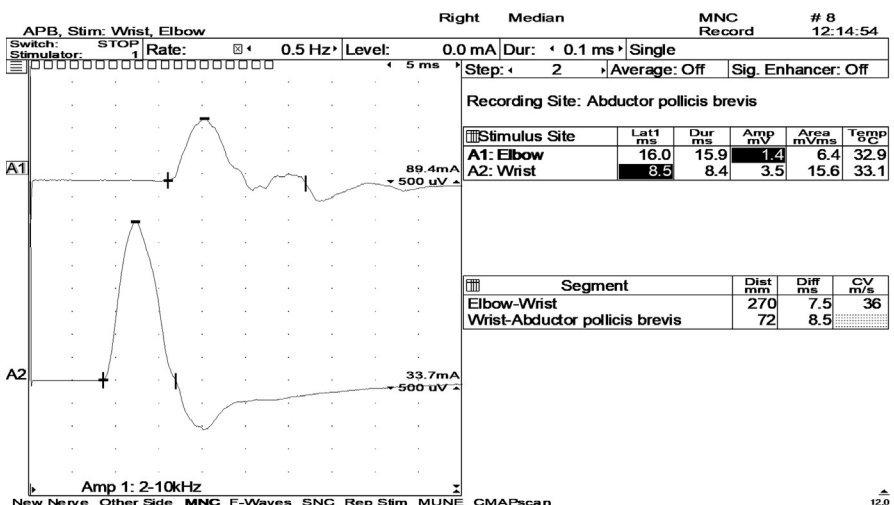
| Site                                 | Nerve Conduction Studies |                        | Needle EMG     |              |        |
|--------------------------------------|--------------------------|------------------------|----------------|--------------|--------|
|                                      | Median Motor (APB)       | Median Sensory (Index) | Thenar Muscles | FPL, PQ, FDP | PT     |
| Ligament of Struthers                | ABN                      | ABN                    | ABN            | ABN          | ABN    |
| PT                                   | ABN                      | ABN                    | ABN            | ABN          | Normal |
| Anterior interosseous nerve syndrome | Normal                   | Normal                 | Normal         | ABN          | Normal |

*Abbreviations:* ABN, abnormal; APB, abductor pollicis brevis; FDP, flexor digitorum profundus digits 2/3; FPL, flexor pollicis longus; PQ, pronator quadratus.

or lumbricals may demonstrate low compound muscle action potential (CMAP) amplitudes. When focal demyelination in the proximal nerve is present, conduction block (CB) or abnormal temporal dispersion may be present in the forearm<sup>2</sup> (Fig. 3). If entrapment at the ligament of Struthers is suspected, stimulation can also be performed in the axilla. Although less commonly performed, median motor nerve conduction study recording from the flexor pollicis longus can be performed and reference values have been established.<sup>10</sup> Median F waves may be prolonged in proximal median neuropathies, but these are nonspecific and nonlocalizing.

The median antidromic sensory nerve conduction study is a technically reliable sensory study to assess the median nerve. Recording is routinely made from the index finger, but can be performed from the most symptomatic digit, and a comparison with the unaffected side is important to assess for a relative amplitude reduction, particularly in milder cases. In proximal lesions, the distal latencies are not usually significantly prolonged, although mild prolongation can occur secondary to axonal loss.

Because focal CB is uncommon and nerve conduction studies alone may not precisely localize the site of injury along the nerve, needle electromyography (EMG) may



**Fig. 3.** Median motor nerve conduction study demonstrating partial CB and abnormal temporal dispersion in a proximal median mononeuropathy.

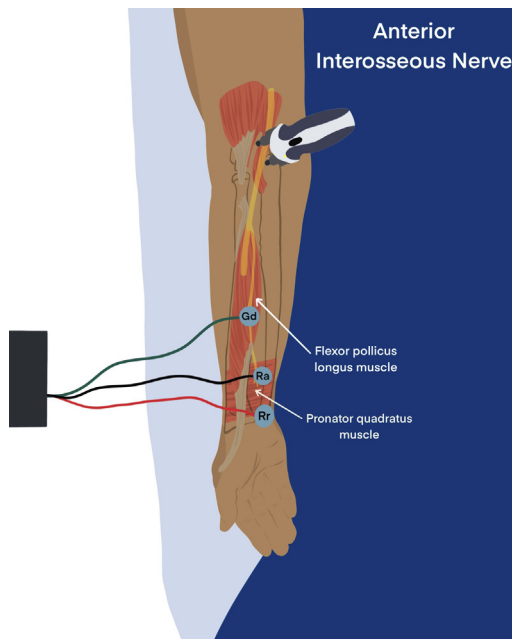
help to more precisely identify localization.<sup>2</sup> The proximal site of injury can often be identified based on the proximal extent of muscles involved. If all muscles, including the PT, are abnormal, the lesion is at or proximal to ligament of Struthers. Muscles supplied by other nerves should also be tested to exclude brachial plexopathy or radiculopathy. The findings on needle EMG reflect the underlying pathophysiology, severity, and chronicity. Fibrillation potentials, reduced recruitment, and long duration motor unit potentials indicate axonal loss and reinnervation. With focal demyelination, decreased recruitment may be the only finding. Specific conditions may demonstrate certain EDX patterns of findings.

### **Pronator syndrome**

In the pronator syndrome, the median nerve is intermittently compressed as it courses through the PT muscle. Rarely, focal demyelination at the site of compression results in CB with abnormal temporal dispersion or slowed conduction velocity between the wrist and the elbow. The median motor distal motor latency (DML) is normal, but the median minimal F waves latency may be prolonged. The sensory nerve conduction study (SNCS) show decreased sensory nerve action potentials (SNAP) amplitudes and normal latency. When severe, EMG demonstrates abnormalities in nearly all median innervated muscles, although the PT is typically spared, because the branch to the muscle is proximal to the median nerve compression as it courses through the muscle. Needle EMG may be normal when only intermittent compression occurs.

### **Anterior Interosseous syndrome**

In AION syndrome, the routine median motor nerve conduction study (MNCS) and SNCS are normal. The median motor nerve conduction study recorded from the pronator quadratus muscle may demonstrate a low CMAP amplitude relative to the unaffected side<sup>11,12</sup> (Fig. 4). EMG demonstrates abnormalities in the PQ, FPL, and FDP (digits II and III). In addition to EDX testing, neuromuscular ultrasound examination may be a complementary test to help to confirm a proximal median neuropathy. In



**Fig. 4.** Anterior interosseous nerve conduction study setup.

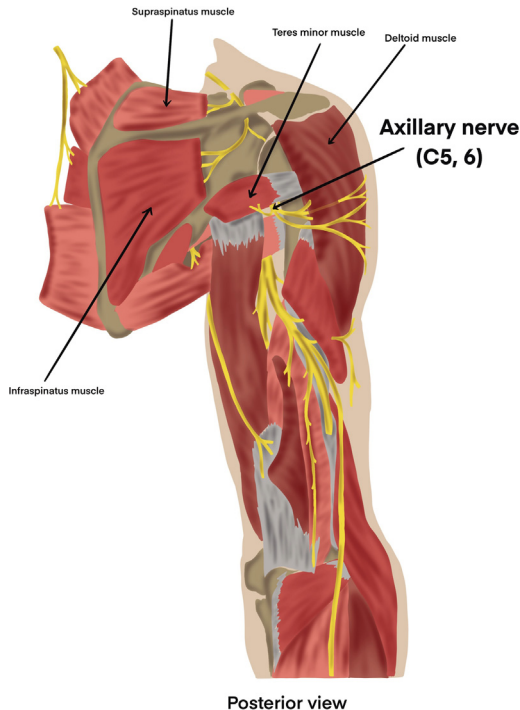
a small study of 5 patients with AION syndrome, ultrasound examination demonstrated focal swelling with an hourglass-like constriction of nerve fascicles in several patients.<sup>13</sup>

### AXILLARY NEUROPATHY

The axillary nerve arises from the posterior cord of the brachial plexus with fibers derived from the C5 and C6 roots.<sup>3</sup> The nerve winds from anterior to posterior around the neck of the humerus, where it may be prone to injury. It passes through the quadrilateral space in company with the posterior humeral circumflex artery and then divides into anterior, posterior, and collateral branches (**Fig. 5**). The anterior branch provides motor innervation to the deltoid and gives off cutaneous branches that supply the skin overlying the deltoid. The posterior branch supplies the teres minor (TM) and posterior deltoid muscles, and the superior lateral cutaneous nerve supplies the skin over the inferior posterior deltoid and the skin over the long head of the triceps brachii (TB). The collateral branch supplies the long head of the TB muscle.

#### *Etiologies and Clinical Features*

Axillary neuropathies most often occur from trauma, including traction at the shoulder, blunt trauma to the shoulder region, dislocation of the humerus at the scapula, or fracture of the surgical neck of the humerus.<sup>14–16</sup> The quadrilateral space syndrome is an uncommon entrapment neuropathy that occurs when the axillary nerve and the posterior humeral circumflex artery become trapped in the quadrilateral space by fibrous tissue accumulation, muscular hypertrophy, tumor, or hematoma.<sup>17,18</sup>



**Fig. 5.** Axillary nerve anatomy.

Axillary neuropathy usually manifests with pain or numbness on the lateral arm and weakness of arm abduction beyond 15°. The initial vague symptoms of shoulder pain and weakness can be misdiagnosed as a primary musculoskeletal problem.<sup>14</sup> The quadrilateral space syndrome may be suggested by point tenderness in the posterior quadrilateral space and pain exacerbated by shoulder flexion, abduction, or external rotation.<sup>17</sup>

### **Electrophysiologic Features**

EDX testing can help to confirm an axillary neuropathy and exclude an upper trunk brachial plexopathy or C5 and C6 radiculopathy<sup>14–19</sup> (Table 2). The only expected abnormal MNCS is the axillary motor nerve conduction study recording from the deltoid (Fig. 6). Because reference values are not well-defined, a greater than 50% decrease in the CMAP amplitude compared with the contralateral side is generally considered abnormal. Although there is no SNCS that test the axillary nerve, other sensory nerve conduction studies (eg, radial or lateral antebrachial cutaneous) are helpful to exclude radial nerve or brachial plexus lesions.

Needle EMG demonstrates abnormalities in the deltoid, TM, or both. Examination of all 3 heads of the deltoid may be useful, because certain fascicles or branches of the axillary nerve may be more affected than others. Additionally, other C5 and C6, non-axillary muscles should be examined. Needle EMG will characterize severity and chronicity of the nerve injury and may include fibrillation potentials, decreased recruitment, and/or long duration motor unit potential.<sup>14,19</sup> There are no published series of EDX findings in patients with axillary mononeuropathies; therefore, the sensitivity of identifying abnormalities on axillary motor nerve conduction study or on needle EMG of individual muscles is unknown.

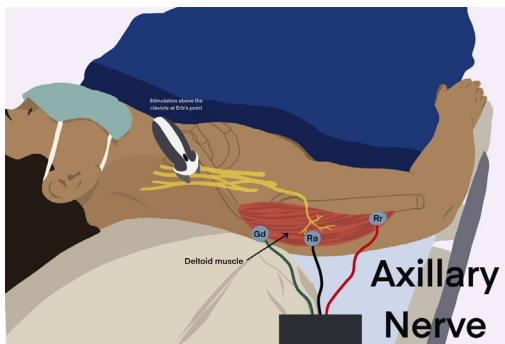
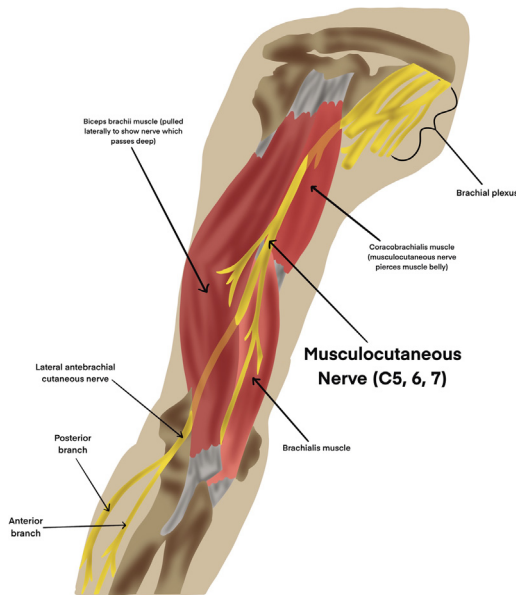


Fig. 6. Axillary motor nerve conduction study setup.

### **MUSCULOCUTANEOUS NEUROPATHY**

The musculocutaneous nerve arises from the termination of the lateral cord of the brachial plexus and consists of fibers derived from the C5 to C7 roots.<sup>3</sup> It courses through the anterior arm, giving off branches to the coracobrachialis, brachialis, and biceps brachii (BB) muscles (Fig. 7). It terminates about 2 cm above the elbow as the lateral antebrachial cutaneous nerve, innervating the skin of the lateral cubital and lateral forearm regions.





**Fig. 7.** Musculocutaneous nerve anatomy.

### ***Etiology and Clinical Features***

Causes of musculocutaneous mononeuropathies include traumatic injury, strenuous physical activity or exercise, external compression from casting, trauma to the arm or axillary region, surgery, compression by tumor or hematoma, or involvement from inflammatory conditions (eg, Parsonage Turner syndrome).<sup>20-23</sup> Patients present with weakness involving elbow flexion and possibly mild weakness of elbow supination or arm flexion.<sup>20</sup> Sensory symptoms, when present, involve the lateral cubital and forearm regions and may be reproducible with flexion of the arm against resistance. If the lesion is near the coracoid process, Tinel's sign may be present at the coracoid process.

### ***Electrophysiologic Features***

EDX studies can help to confirm a musculocutaneous neuropathy, exclude other mimickers, and determine the severity and degree of recovery<sup>20,22</sup> (see **Table 2**) (**Fig. 8**). Although most injuries produce axonal loss and low musculocutaneous CMAP amplitudes, focal demyelination with CB or abnormal dispersion may occasionally be seen. In a review of 32 patients with musculocutaneous neuropathy or isolated lateral antebrachial cutaneous neuropathy, the musculocutaneous CMAP amplitude and lateral antebrachial SNAP amplitudes were low or absent in the majority, but were normal in some.<sup>24</sup>

In musculocutaneous mononeuropathy, EMG abnormalities are present in the BB and brachialis, without involvement of other C5 and C6 UE muscles. The coracobrachialis muscle is more difficult to examine, but may also show abnormalities.

### **SUPRASCAPULAR NEUROPATHY**

The suprascapular nerve arises from the upper trunk of the brachial plexus and is formed by the ventral rami of C5 and C6.<sup>3</sup> It runs along the superior border of the scapula to the suprascapular notch just below the superior transverse scapular ligament, entering the suprascapular fossa of the posterior scapula giving off branches to the supraspinatus muscle. It passes under the supraspinatus, curves near the lateral border of the scapular spine, and through the spinoglenoid notch to enter the infraspinous fossa of the scapula, giving branches to the infraspinatus muscle (**Fig. 9**). It supplies sensation to the acromioclavicular and glenohumeral joints.



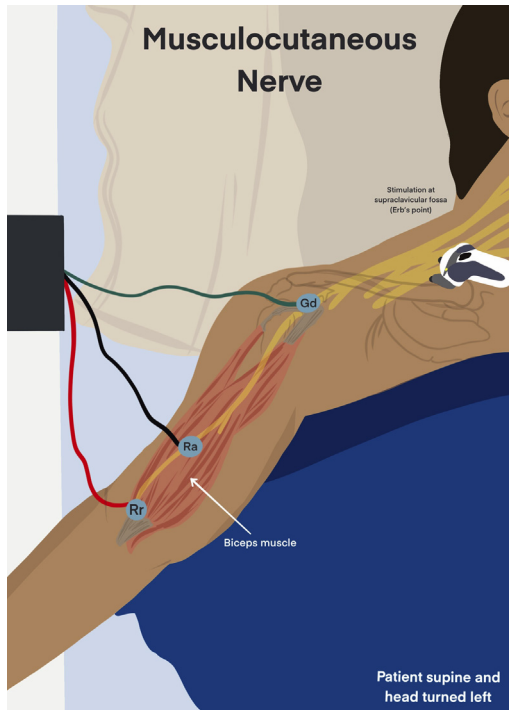


Fig. 8. Musculocutaneous nerve conduction study setup.

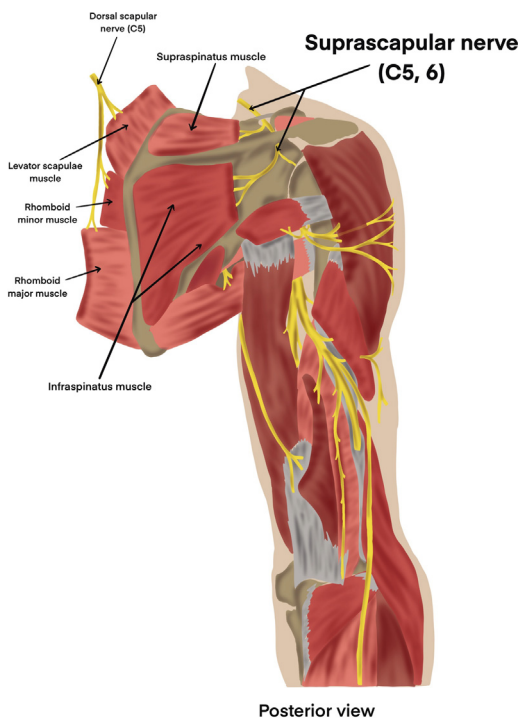


Fig. 9. Suprascapular nerve anatomy.

### ***Etiology and Clinical Features***

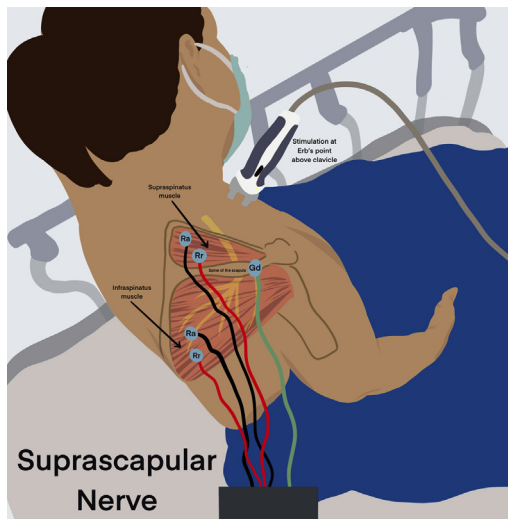
Suprascapular neuropathies are rare.<sup>25</sup> Etiologies include repetitive overhead activities (occupational or recreational), sports (such as volleyball, pitching in baseball, tennis, swimming, or weight-lifting), traction owing to a rotator cuff tear, direct trauma, or compression from a mass lesion at the suprascapular notch or the spinoglenoid notch.<sup>25–28</sup>

Patients with suprascapular neuropathies present with vague symptoms of shoulder pain and weakness of first 15° of shoulder abduction and external rotation of the humerus. Atrophy of the supraspinatus and infraspinatus muscles may be present on examination.<sup>25</sup> Because patients with rotator cuff disease may present with similar symptoms and signs, EDX testing provides important information about the integrity of the nerve.

### ***Electrophysiologic Features***

The EDX abnormalities in suprascapular neuropathies are limited to suprascapular nerve conduction studies and needle EMG abnormalities in the infraspinatus and supraspinatus muscles<sup>26</sup> (Fig. 10) (see Table 2). The suprascapular motor nerve conduction study, recording from the supraspinatus and/or infraspinatus, shows variable CMAP amplitude reduction. A side-to-side CMAP amplitude difference of 50% or greater is considered abnormal (Fig. 11). In a study that included 57 patients with isolated suprascapular neuropathies, the CMAP amplitude did not predict recovery, because there was no significant amplitude difference in patients with and without recovery.<sup>29</sup> Although there are no SNCS to test the suprascapular nerve, other SNCS in the UE are important to exclude an upper trunk brachial plexopathy.

On needle EMG, abnormalities isolated to the supraspinatus and/or infraspinatus, in the absence of abnormalities in other C5 and C6 muscles, confirm a suprascapular neuropathy.<sup>26</sup> Abnormality of both muscles indicates a lesion at the suprascapular notch, whereas abnormality of the infraspinatus alone suggests localization to the spinoglenoid notch. The ability of needle EMG to predict recovery is limited.<sup>29</sup> However, in a small study of 9 patients with paralabral cysts causing a suprascapular

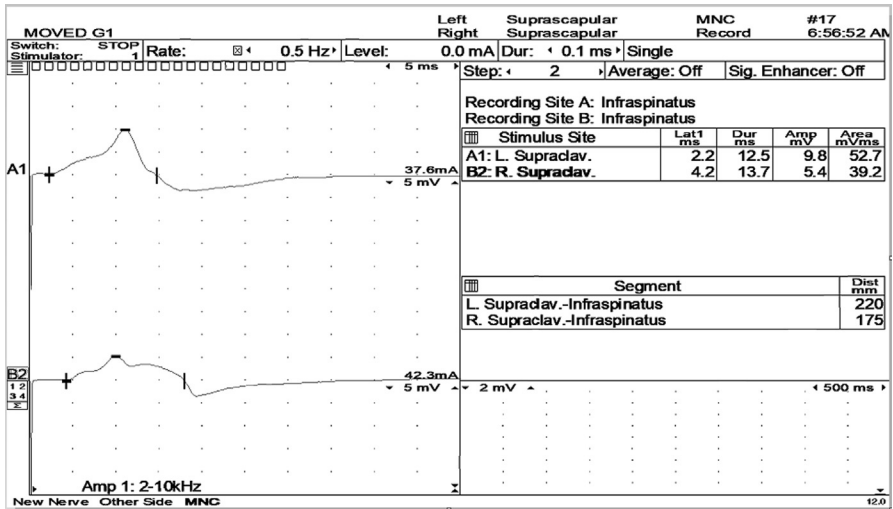


**Fig. 10.** Suprascapular nerve conduction study setup.

**Table 2**  
EDX features of axillary, musculocutaneous, and suprascapular mononeuropathies compared with C5 and C6 radiculopathies and upper trunk brachial plexopathy

| Site                        | Nerve Conduction Studies |                        |                     |        | Needle EMG          |        |                                 |             |
|-----------------------------|--------------------------|------------------------|---------------------|--------|---------------------|--------|---------------------------------|-------------|
|                             | Axillary Motor           | Musculocutaneous Motor | Suprascapular Motor | LAC    | Deltoid/Teres Minor | Biceps | Suprascapular and Infraspinatus | Paraspinals |
| Axillary nerve              | ABN                      | Normal                 | Normal              | Normal | ABN                 | ABN    | Normal                          | Normal      |
| Musculocutaneous nerve      | Normal                   | ABN                    | Normal              | ABN    | Normal              | Normal | Normal                          | Normal      |
| Suprascapular nerve         | Normal                   | Normal                 | ABN                 | Normal | Normal              | Normal | ABN                             | Normal      |
| Upper trunk brachial plexus | ABN                      | ABN                    | ABN                 | ABN    | ABN                 | ABN    | ABN                             | Normal      |
| C5-6 Root                   | ABN                      | ABN                    | ABN                 | Normal | ABN                 | ABN    | ABN                             | ABN         |

*Abbreviations:* ABN, abnormal; LAC, lateral antebrachial cutaneous sensory study.



**Fig. 11.** Suprascapular motor nerve conduction study in a patient with a right suprascapular mononeuropathy. The CMAP is 9.8 on the left (*top trace*) and 5.4 on the right (*bottom trace*).

neuropathy, all patients demonstrated recovery by EMG after decompressive surgery.<sup>30</sup> Furthermore, in some patients with suprascapular mononeuropathy, needle EMG may identify abnormalities indicating a concomitant axillary mononeuropathy, particularly in traumatic cases.<sup>29</sup>

## FEMORAL NEUROPATHY

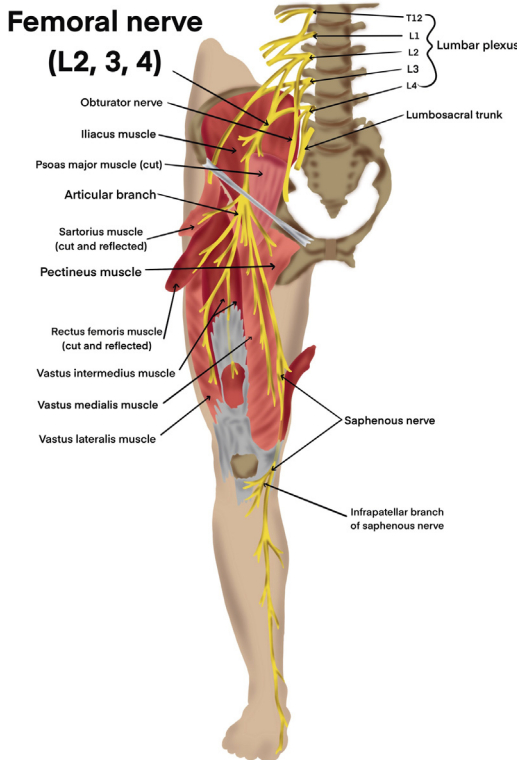
The femoral nerve is the largest branch of the lumbar plexus and is comprised of L2 to L4 nerve roots.<sup>3</sup> The nerve enters Scarpa's triangle after passing beneath the inguinal ligament, lateral to the femoral artery. In the anterior thigh, it travels in a groove between the iliacus and psoas major muscles, outside of the femoral sheath and lateral to the femoral artery. In the thigh, it divides into the anterior and posterior divisions. The anterior division gives off branch to the sartorius muscle and intermediate and medial femoral cutaneous nerves. The posterior division gives off motor branches to the quadriceps (rectus femoris, vastus medialis, vastus intermedius, and vastus lateralis) articularis genus muscles, and saphenous sensory nerve (**Fig. 12**).

### *Etiologies and Clinical Features*

The femoral nerve can be injured from trauma, surgery (abdominal, pelvic, orthopedic), after femoral nerve block or femoral artery puncture, tumor or hematoma (in the abdomen, pelvis, or anterior thigh), compression from abdominal aortic aneurysm, or diabetes.<sup>31–35</sup> Entrapment most commonly occurs under the iliopsoas tendon, the inguinal ligament, or at the adductor canal.<sup>36</sup> Femoral neuropathy presents with variable weakness of hip flexion and knee extension and sensory symptoms in the anterior and medial thigh and anteromedial leg.<sup>31</sup>

### *Electrophysiologic Features*

EDX studies are important to confirm a femoral mononeuropathy and distinguish it from a lumbar (L2–L4) radiculopathy or plexopathy<sup>37</sup> (**Table 3**). A femoral MNCS

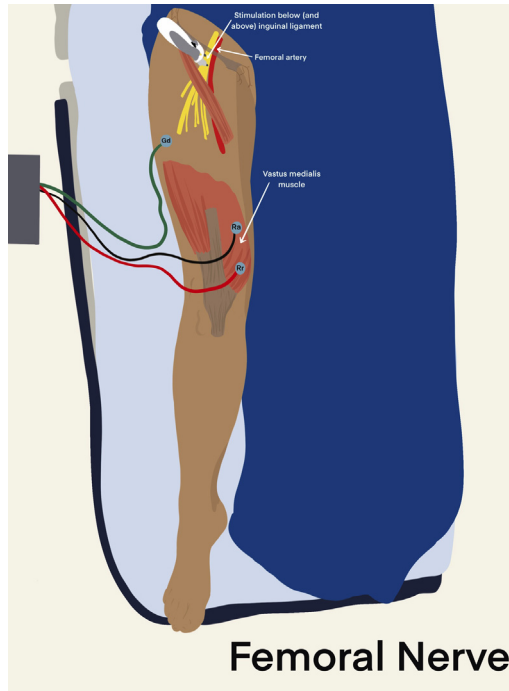


**Fig. 12.** Femoral nerve anatomy.

(recording from the rectus femoris or vastus medialis) can be technically difficult owing to the deep location of the nerve during stimulation (Fig. 13). Side-to-side comparisons to assess for a 50% or greater decrease in the CMAP amplitude is necessary. The saphenous SNCS is the only testable sensory branch of the femoral nerve, but is also a technically difficult nerve conduction studies. Therefore, the diagnosis often relies on needle EMG. On needle EMG, femoral muscles and nonfemoral (eg, obturator innervated) L2 to L4 muscles should be examined to exclude lumbar radiculopathy.<sup>37</sup> The findings in the iliopsoas and quadriceps muscles can localize the lesion in relation to the inguinal ligament.

| Table 3<br>EDX features of obturator and femoral mononeuropathies, L2 and L3 radiculopathies, and lumbar plexopathy |                          |                   |            |            |                 |             |
|---|--------------------------|-------------------|------------|------------|-----------------|-------------|
| Site  | Nerve Conduction Studies |                   | Needle EMG |            |                 |             |
|   | Femoral Motor            | Saphenous Sensory | Iliopsoas  | Quadriceps | Adductor Longus | Paraspinals |
| Obturator nerve   | Normal                   | Normal            | Normal     | Normal     | ABN             | Normal      |
| Femoral nerve   | ABN                      | ABN               | ABN        | ABN        | Normal          | Normal      |
| Lumbar plexus   | ABN                      | ABN               | ABN        | ABN        | ABN             | Normal      |
| L2–L3 root  | ABN                      | Normal            | ABN        | ABN        | ABN             | ABN         |

*Abbreviations:* ABN, abnormal; LAC, lateral antebrachial cutaneous sensory study.



**Fig. 13.** Femoral motor nerve conduction study setup.

### **OBTURATOR NEUROPATHY**

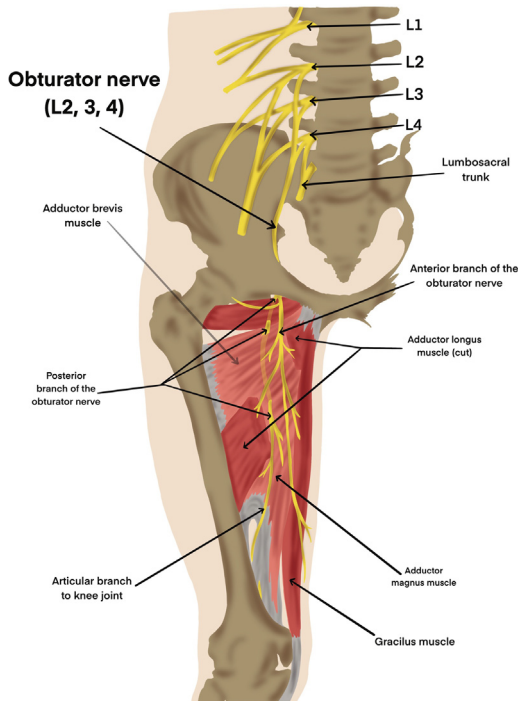
The obturator nerve arises from the lumbar plexus and is derived from the L2 to L4 roots.<sup>3</sup> It passes through the fibers of the psoas major muscles, emerging at the medial border near the brim of the pelvis. It passes near the common iliac arteries, then along the lateral wall of the lesser pelvis, superior and anterior to the obturator vessels to the upper portion of the obturator foramen. It enters the thigh via the obturator canal and divides into anterior and posterior branches, giving branches to the adductor muscles; external obturator, adductor longus, adductor brevis, adductor magnus, gracilis, and variably to the pectineus muscle. The nerve provides sensory innervation to the medial thigh (**Fig. 14**).

#### ***Etiologies and Clinical Features***

The obturator nerve may be injured from direct trauma, pelvic surgery, obstetric delivery (particularly with forceps use), tumor or hematoma, entrapment at the obturator canal, or entrapment at the adductor muscle fascia.<sup>36,38–42</sup> Obturator neuropathies often presents with vague symptoms of pain and dysesthesias in the medial thigh or groin.<sup>38–40</sup> Weakness of leg adduction may not be noticed by the patient. When entrapped at the adductor muscle fascia, abduction of the thigh may exacerbate pain and other sensory symptoms.

#### ***Electrophysiologic Features***

Obturator neuropathy can be confirmed by needle EMG, but there are no reliable nerve conduction studies to study the nerve. Needle EMG will demonstrate



**Fig. 14.** Obturator nerve anatomy.

abnormalities in the adductor longus and magnus, but not L2 to L4 muscles supplied by the femoral nerve<sup>39</sup> (see [Table 3](#)). EDX testing is important to obtain precise localization; in one study, 39% of patients who were referred for a suspected obturator neuropathy were found to have a different disorder.<sup>40</sup>

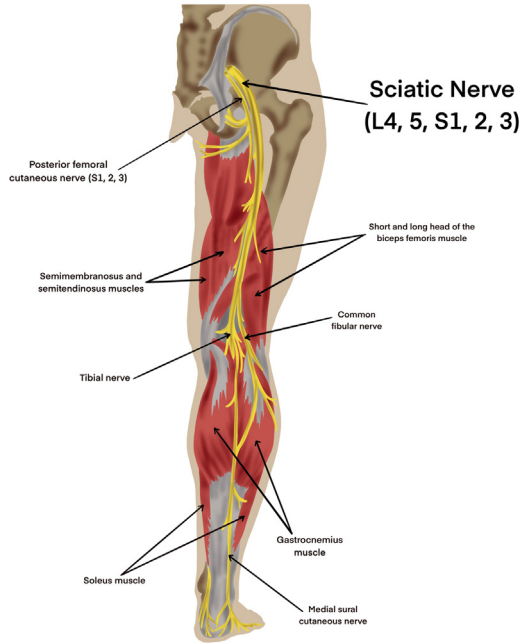
## SCIATIC NEUROPATHY

The sciatic nerve arises from the lower portion of the lumbosacral plexus (with L4–L5, S1–S3 root innervation).<sup>3</sup> It originates in front of the piriformis muscle, passes through the muscle, and courses through the greater sciatic foramen to exit the pelvis ([Fig. 15](#)). It travels inferiorly in the posterior compartment of the thigh superficial to the adductor magnus muscle to the popliteal fossa, where it divides into the common fibular (peroneal) and the tibial nerves. It gives off motor branches to the hamstrings (biceps femoris, semitendinosus, and semimembranosus) and the adductor magnus. It provides sensory innervation to the skin over the buttocks and posterior thigh, and to the lower leg and foot (except for the anteromedial ankle) through its terminal branches.

### ***Etiology and Clinical Features***

Pain in the sciatic nerve distribution is commonly referred to as “sciatica,” but this term encompasses many localizations, including lumbosacral radiculopathy. Although sciatica is common and affects between approximately 1% and 40% of people at some point in their life, direct injury or involvement of the sciatic nerve is rare.<sup>43</sup> Etiologies of sciatic neuropathy include direct trauma (eg, penetrating trauma of the buttock or posterior thigh), femur fracture, after gluteal intramuscular injections, hip





**Fig. 15.** Sciatic nerve anatomy.

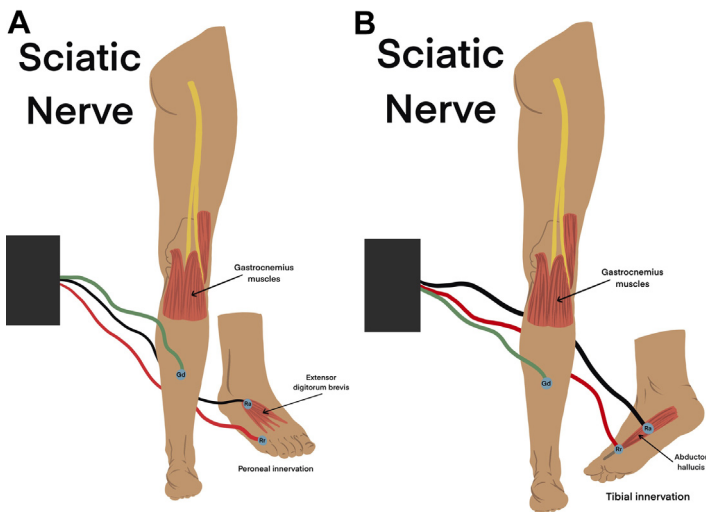
dislocation, hip surgery (eg, hip replacement), and hardware degradation and disintegration within the hip. It can also present during cesarean section or vaginal delivery owing to positioning (greater thigh flexion is associated with a greater risk for sciatic nerve traction), or compression by a tumor or hematoma.<sup>44–51</sup> In a recent study of 109 patients from a single institution with sciatic neuropathy from nonpenetrating trauma, 56% were related to LE injury such as hip replacement, 15% related to compression, and a small percentage related to inflammation, radiation, ischemia, or other causes.<sup>52</sup> The sciatic nerve may also rarely be entrapped as it courses through the piriformis muscle, resulting in piriformis syndrome.<sup>50</sup> Piriformis syndrome may result from an overuse injury, anatomic variation, piriformis muscle spasms, or by pseudoaneurysm of the inferior gluteal artery.<sup>51,53,54</sup>

Sciatic neuropathy often presents with nonspecific painful sensory symptoms and weakness.<sup>45,55</sup> Sensory features consist of pain overlying the ipsilateral buttock and posterior thigh, as well as numbness or paresthesia. Some weakness of knee flexion may also occur. More complete or severe sciatic neuropathy may present with weakness and sensory disturbance involving the foot as well as the hamstring region, which can mimic fibular (peroneal) and tibial mononeuropathies. In sciatic neuropathy, peroneal fibers are more susceptible to stretch injury than tibial fibers. Sensory features may involve the entire foot and leg, except the anteromedial ankle (saphenous distribution). Piriformis syndrome typically presents as pain in the buttock or hip area, radiating pain or numbness that can extend into the calf, nonspecific weakness that can affect part or all of the leg, ankle, and foot owing to involvement of peroneal and tibial fibers.<sup>51,53,54</sup>

### **Electrophysiologic Features**

Given the clinical similarities of sciatic neuropathy and lumbosacral radiculopathy, EDX is useful to assist in localization, as well as determine the chronicity and severity

of the injury<sup>52,55,56</sup> (Table 4). Abnormalities in the peroneal, tibial, or both MNCS are typical (Fig. 16A, B). The sural and superficial peroneal SNAP and the peroneal motor study recording from the extensor digitorum brevis (EDB) have been shown to be more sensitive compared with the tibial motor study; only 60% of patients had abnormalities in both peroneal and tibial CMAPs and sural and superficial peroneal sensory nerve action potentials.<sup>52</sup> F waves and H reflexes may be prolonged or absent, but these are nonspecific and nonlocalizing, because they can also be abnormal in radiculopathies and plexopathies.<sup>57</sup> H reflex latency may show changes with provocative tests in piriformis syndrome.<sup>54</sup> Abnormal SNAP responses help to distinguish sciatic neuropathy, in which the superficial peroneal, sural, and/or plantar responses are abnormal, from a lumbosacral radiculopathy (in which SNAP are normal). However, abnormal sensory nerve action potentials can also occur with lumbosacral plexus localization. Because low motor and sensory nerve conduction studies amplitudes may also be seen in a polyneuropathy, side-to-side comparison is important when a sciatic neuropathy is suspected.

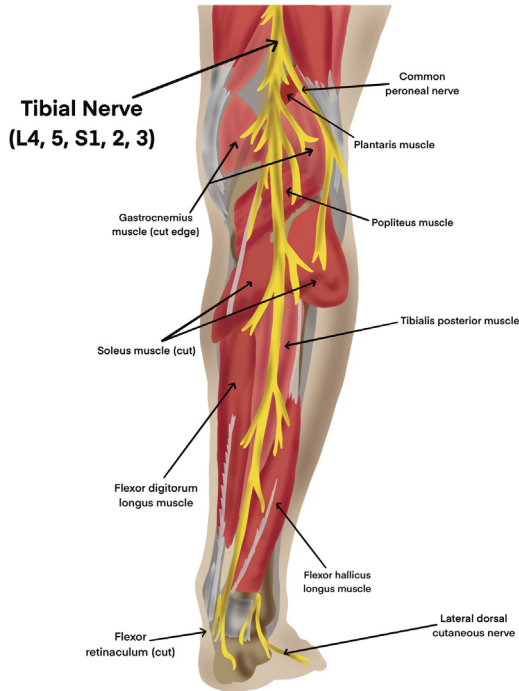


**Fig. 16.** Nerve conduction studies to test the motor branches of the sciatic nerve. (A) Recording from the extensor digitorum brevis muscle. (B) Recording from the abductor hallucis.

Needle EMG demonstrates abnormalities to a variable degree in muscles supplied by the peroneal and tibial nerves in the lower leg, biceps femoris, but sparing muscles supplied by the superior and inferior gluteal innervated muscle (eg, gluteus medius or tensor fasciae latae, and gluteus maximus) muscles in the lower leg have been shown to be abnormal more frequently than hamstring muscles, with abnormalities in the hamstring muscles being present approximately 45% of the time.<sup>52</sup> Abnormalities are more coming in peroneal-innervated muscles in nearly all patients with sciatic neuropathies but in tibial-innervated muscles in 74% to 84% of patients.<sup>56</sup>

### TIBIAL NEUROPATHY

The tibial nerve arises from the sciatic nerve in the popliteal fossa.<sup>3</sup> It courses through the popliteal fossa giving off branches to the gastrocnemii, soleus, plantaris, and



**Fig. 17.** Tibial nerve anatomy.

popliteus muscles as well as sensory branches to the lower one-half of the posterior leg and the lateral border of the foot to the tip of the fifth toe (**Fig. 17**). At the inferior border of the popliteal fossa, the nerve courses deep to the tendinous arch of the soleus and enters the posterior leg. It continues inferiorly and medially, reaching the posteromedial aspect of the ankle between the medial malleolus and the calcaneus. In the leg, it gives off branches to the tibialis posterior (TP), FDL, flexor hallucis longus, and deep portion of the soleus. It terminates deep in the flexor retinaculum, dividing into the medial and lateral plantar and medial and lateral calcaneal nerves (**Fig. 18**). The medial and lateral plantar nerves supply the skin of the medial and lateral sole, respectively, and provide innervation to many of the intrinsic foot muscles (**Fig. 19**).

### ***Etiology and Clinical Features***

Etiologies of tibial neuropathies include direct trauma, ischemia, and masses (eg, Baker's cyst, tumor, or hematoma). Tarsal tunnel syndrome (TTS) is a rare tibial entrapment neuropathy at the flexor retinaculum at the ankle, and may result from osseous compression (owing to bone spurs, fracture fragments, tarsal coalition), mass lesions (ganglia, nerve sheath tumors, fibrous tissue, hypertrophic muscles, accessory muscles), congenital foot deformities, or systemic diseases (diabetes, vasculitis, rarely uremia).<sup>58–61</sup>

Proximal tibial mononeuropathies at the popliteal fossa or leg have variable presentations.<sup>58</sup> Lesions in the popliteal fossa or above the leg present with weakness of ankle plantarflexion, inversion, toe flexion, and sensory deficits in the lower portion of the posterior leg and the lateral side of the foot to the end of the fifth toe, and bottom of the foot. Tarsal tunnel syndrome most commonly presents with foot and ankle pain

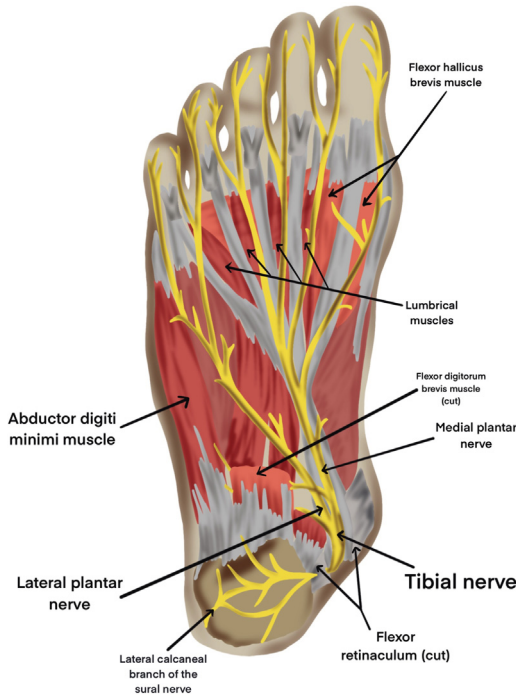


Fig. 18. Anatomy of the distal branches of the tibial nerve.

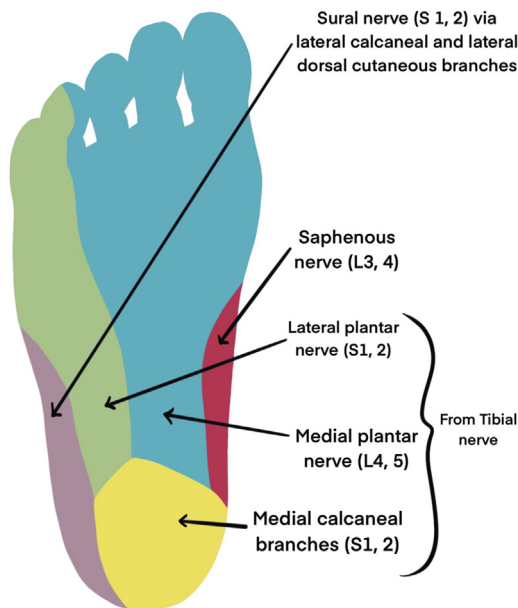


Fig. 19. Sensory dermatomes of the bottom of the foot.

| Site                      | Nerve Conduction Studies |              |        |                        | Needle EMG          |                       |  |            |                                 |
|---------------------------|--------------------------|--------------|--------|------------------------|---------------------|-----------------------|--|------------|---------------------------------|
|                           | Peroneal Motor           | Tibial Motor | Sural  | Medial/Lateral Plantar | Tibial Foot Muscles | Gastrocnemius, Soleus | Anterior Tibialis, Peroneal Foot Muscles | Hamstrings | Gluteus Medius, Gluteus Maximus |
| Sciatic nerve             | ABN                      | ABN          | ABN    | ABN                    | ABN                 | ABN                   | ABN                                      | ABN        | Normal                          |
| Tibial nerve at the knee  | Normal                   | ABN          | ABN    | ABN                    | ABN                 | ABN                   | Normal                                   | Normal     | Normal                          |
| Tibial nerve at the ankle | Normal                   | ABN          | Normal | ABN                    | ABN                 | Normal                | Normal                                   | ABN        | Normal                          |
| Sacral plexus             | ABN                      | ABN          | ABN    | ABN                    | ABN                 | ABN                   | ABN                                      | ABN        | ABN                             |

*Abbreviation:* ABN, abnormal.

that is burning in character and exacerbated by weight bearing and worse at night.<sup>58,59</sup> Perimalleolar pain, numbness, and paresthesia, as well as atrophy of intrinsic foot muscles may be present.

### Electrophysiologic Features

EDX testing is helpful to confirm the diagnosis and exclude alternative pathologies such as polyneuropathy, S1 radiculopathy, sciatic neuropathy, and lumbosacral plexopathy<sup>62</sup> (see [Table 4](#)). Tibial motor nerve conduction study can be recorded from the abductor hallucis and abductor digiti minimi pedis ([Fig. 20](#)). Transtarsal medial and lateral plantar mixed nerve conduction studies will often demonstrate low amplitudes, and the sural amplitude may be variably affected because the sural is composed of branches from the fibular/peroneal and tibial nerves.

Needle EMG demonstrates abnormalities in tibial innervated foot muscles at any site of injury to the tibial nerve, but abnormalities in these muscles are difficult to interpret in older individuals. More proximal muscles, such as the gastrocnemii and TP help to determine the proximal extent of the injury. A 2005 American Association of Neuro-muscular and Electrodiagnostic Medicine practice parameter reviewed the literature to assess the role of EDX studies in TTS.<sup>62</sup> Although the number of high-quality studies was limited, SNCS and mixed nerve conduction studies abnormalities were present in 85% to 93% of patients with the lateral plantar sensory response more commonly absent than the medial plantar response. Prolonged tibial DML to the AH were only present in 21% to 52% of individuals, indicating that MNCS are less sensitive than sensory nerve conduction studies in the diagnosis of tarsal tunnel syndrome. There

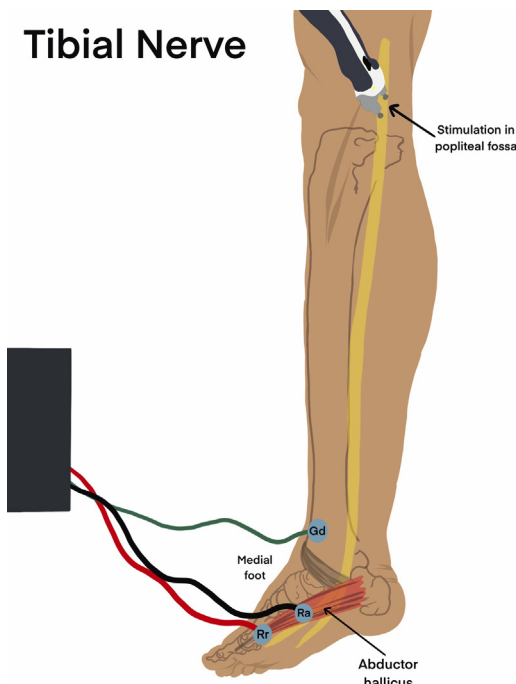


Fig. 20. Tibial motor nerve conduction study setup.

were no studies that directly assessed the utility of needle EMG in the evaluation of TTS. In the presence of significant polyneuropathy, the diagnosis of TTS may be difficult to confirm; prolonged latencies are more common, but low amplitudes can occur.<sup>59,62</sup>

## SUMMARY

Electrodiagnosis is an important tool that complements the clinical assessment of patients with suspected uncommon mononeuropathies. Knowledge of the anatomy and understanding the pattern of findings on nerve conduction studies and needle EMG help to diagnoses these conditions and exclude more common mimickers. The EDX often requires technically difficult or less commonly performed studies, making diagnosis more challenging.

## CLINICS CARE POINTS

- Detailed knowledge of neuroanatomy is crucial for diagnosis of uncommon neuropathies. Brief neuromuscular examination before the electrodiagnostic study will help to tailor the study and make the correct diagnosis.
- Contralateral studies are usually very helpful to diagnose mild to moderate uncommon neuropathies.
- Detailed electromyography can localize the lesion when the nerves are not easily accessible for conduction studies

## ACKNOWLEDGMENTS

Illustrations by Ms Danielle Rinck.

## REFERENCES

1. Dang AC, Rodner CM. Unusual compression neuropathies of the forearm, part II: median nerve. *J Hand Surg Am* 2009;34(10):1915–20.
2. Gross PT, Jones HR. Proximal median neuropathies: electromyographic and clinical correlation. *Muscle Nerve* 1992;15:390–5.
3. Standing S. *Gray's anatomy: the anatomical basis of clinical practice*. 41st edition. Elsevier Limited; 2016.
4. Campbell WW, Landau ME. Controversial entrapment neuropathies. *Neurosurg Clin N Am* 2008;19(4):597–608.
5. Dawson DM, Hallet M, Wilbourn AJ. *Entrapment neuropathies*. third ed. Philadelphia: Lippincott; 1999.
6. Kumar GR. A study of the incidence of supracondylar process of the humerus. *J Anat Soc India* 2008;57(2):111–5.
7. Gross PT, Tolomado EA. Proximal median neuropathies. *Neurol Clin* 1999;17(3):425–45.
8. Schantz K, Riegels-Nielsen P. The anterior interosseous nerve syndrome. *J Hand Surg* 1992;17(5).
9. Pham M, Bäumer P, et al. Anterior interosseous nerve syndrome: fascicular motor lesions of median nerve trunk. *Neurology* 2014;82(7):598–606.



10. Vuvic S, Yiannikas C. Anterior interosseous nerve conduction study: normative data. *Muscle Nerve* 2007;35:119–21.
11. Rosenberg JN. Anterior interosseous/median nerve latency ratio. *Arch Phys Med Rehabil* 1990;71:228–30.
12. Nakano KK, Lundergan C, Okihiro MM. Anterior interosseous nerve syndromes: diagnostic methods and alternative treatments. *Arch Neurol* 1977;34:477–80.
13. Noda Y, Sekiguchi K, Tokuoaka H, et al. Ultrasonographic findings of proximal median neuropathy: a case series of suspected distal neuralgic amyotrophy. *J Neurol Sci* 2017;377:1–5.
14. Steinmann SP, Moran EA. Axillary nerve injury: diagnosis and treatment. *J Am Acad Orthop Surg* 2001;9(5):328–35.
15. Davidson LT, Carter GT, et al. Iatrogenic axillary neuropathy after intramuscular injection of the deltoid muscle. *Am J Phys Med Rehabil* 2007;86(6):507–11.
16. Paladini D, Dellantonio R, et al. Axillary neuropathy in volleyball players: report of two cases and literature review. *J Neurol Neurosurg Psychiatry* 1996;60:345–7.
17. Cahill BR, Palmer RE. Quadrilateral space syndrome. *J Hand Surg* 1983;8(1):65–9.
18. Linker CS, Helms CA, Fritz RC. Quadrilateral space syndrome: findings at MR imaging. *Radiology* 1993;188(3).
19. De Laat EAT, Visser CPJ, et al. Nerve lesions in primary shoulder dislocations and humeral neck fractures: a prospective clinical and EMG study. *J Bone Joint Surg Br* 1994;76-B(3):381–3.
20. Beslega D, Castellano V, et al. Musculocutaneous neuropathy: case report and discussion. *HSS J* 2010;6:112–6.
21. Mastaglia FL. Musculocutaneous neuropathy after strenuous physical activity. *Med J Aust* 1986;145(3–4):153–4.
22. Yilmaz C, Eskandari MM, Colak M. Traumatic musculocutaneous neuropathy: a case report. *Arch Orthop Trauma Surg* 2005;125:414–6.
23. Juel VC, Kiely JM, et al. Isolated musculocutaneous neuropathy caused by a proximal humeral exostosis. *Neurology* 2000;54(2):494.
24. O’Gorman CM, Kassardjian C, Sorenson EJ. Musculocutaneous neuropathy. *Muscle Nerve* 2018;58:726–9.
25. Boykin RE, Friedman DJ, et al. Suprascapular neuropathy. *J Bone Joint Surg* 2010;92(13):2348–64.
26. Anthony R, Rotenberg D, Bach BR Jr. Suprascapular neuropathy. *J Am Acad Orthop Surg* 1999;7(6):358–67.
27. Ferretti A, Cerullo G, Russo G. Suprascapular neuropathy in volleyball players. *J Bone Joint Surg* 1987;69-A(2):260–3.
28. Ringel SP, Treihaf M, Carr M. Suprascapular neuropathy in pitchers. *Am J Sports Med* 1990;18(1):80–6.
29. Memon AB, Dymm B, Ahmad BK, et al. Suprascapular neuropathy: a review of 87 cases. *Muscle Nerve* 2019;60:250–3.
30. Feinberg JH, Mehta P, Gulotta LV, et al. Electrodiagnostic evidence of suprascapular nerve recovery after decompression. *Muscle Nerve* 2019;59:247–9.
31. Kuntzer T, Mell GV, Regil F. Clinical and prognostic features in unilateral femoral neuropathies. *Muscle Nerve* 1998;20(2):205–11.
32. Moore AE, Stringer MD. Iatrogenic femoral nerve injury: a systematic review. *Surg Radiol Anat* 2011;33:649–58.
33. Coppack SW, Watkins PJ. The natural history of diabetic femoral neuropathy. *Q J Med* 1991;79(1):307–13.

34. Rosenblum J, Schwarz GA, Bendler E. Femoral neuropathy - a neurological complication of hysterectomy. *JAMA* 1966;195(6):409-14.
35. Merchant RF, Cafferata HT, DePalma RG. Ruptured aortic aneurysm seen initially as acute femoral neuropathy. *Arch Surg* 1982;117(6):811-3.
36. Martin R, Martin HD, Kivlan BR. Nerve entrapment in the hip region: current concepts review. *Int J Sports Phys Ther* 2017;12(7):1163-73.
37. Jillapalli D, Shefner JM. Electrodiagnosis in common mononeuropathies and plexopathies. *Semin Neurol* 2005;25(2):196-203.
38. Craig A. Entrapment neuropathies of the lower extremity. *PM R* 2013;5(5 suppl):S31-40.
39. Tipton JS. Obturator neuropathy. *Curr Rev Musculoskelet Med* 2008;1:234-7.
40. Sorenson EJ, Chen JJ, Daube JR. Obturator neuropathy: causes and outcome. *Muscle Nerve* 2002;25(4):605-7.
41. Harvey G, Bell S. Obturator neuropathy: an anatomic perspective. *Clin Orthop Relat Res* 1999;363:203-11.
42. Warfield CA. Obturator neuropathy after forceps delivery. *Obstet Gynecol* 1984;64(3 suppl):47S-8S.
43. Cook CE, Taylor J, et al. Risk factors for the first time incidence sciatica: a systematic review. *Physiother Res Int* 2013;19(2):65-78.
44. Valat J-P, Genevay S, et al. Sciatica. *Best Pract Res Clin Rheumatol* 2010;24(2):241-52.
45. Yuen EC, So YT. Sciatic neuropathy. *Neurol Clin* 1999;17(3):617-31.
46. Roy S, Levine AB, et al. Intraoperative positioning during Cesarean as a cause of sciatic neuropathy. *Obstet Gynecol* 2002;99(4):652-3.
47. McQuarrie HG, Harris JW, et al. Sciatic neuropathy complicating vaginal hysterectomy. *Am J Obstet Gynecol* 1972;113(2):223-32.
48. Fleming RE Jr, Michelsen CB. Sciatic paralysis: a complication of bleeding following hip surgery. *J Bone Joint Surg* 1979;61-A(1):37-9.
49. Plewnia C, Wallace C, Zochodne D. Traumatic sciatic neuropathy: a novel cause, local experience, and a review of the literature. *J Trauma Acute Care Surg* 1999;47(5):986.
50. Parziale JR, Hudgins TH, Fishman LM. The piriformis syndrome. *Am J Orthop (Belle Mead NJ)* 1996;25(12):819-23.
51. Papadopoulos SM, McGillicuddy JE, Albers JW. Unusual cause of "piriformis muscle syndrome." *Arch Neurol* 1990;47:1144-6.
52. Cherian RP, Li Y. Clinical and electrodiagnostic features of nontraumatic sciatic neuropathy. *Muscle Nerve* 2019;59(3):309-14.
53. Papadopoulos SM, McGillicuddy JE, Messina LM. Pseudoaneurysm of the inferior gluteal artery presenting as sciatic nerve compression. *Neurosurgery* 1989;24:926-8.
54. Fishman LM, Zybert PA. Electrophysiologic evidence of piriformis syndrome. *Arch Phys Med Rehabil* 1992;73:359-64.
55. Yuen EC, Olney RK, So YT. Sciatic neuropathy: clinical and prognostic features in 73 patients. *Neurology* 1994;44(9):1669.
56. Yuen EC, So YT, Olney RK. The electrophysiologic features of sciatic neuropathy in 100 patients. *Muscle Nerve* 1995;18(4):414-20.
57. Goodgold J. H reflex. *Arch Phys Med Rehabil* 1976;57:407.
58. Drees C, Wilbourn AJ, Stevens HGJ. Main trunk tibial neuropathies. *Neurology* 2002;59(7):1082-4.
59. Oh SJ, Meyer RD. Entrapment neuropathies of the tibial (posterior tibial) nerve. *Neurol Clin* 1999;17(3):593-615.

60. Lee J-H, Jun J-B, et al. Posterior tibial neuropathy by a Baker's cyst: case report. *Korean J Intern Med* 2000;15(1):96–8.
61. Dimberg EL, Rubin DI, et al. Popliteus muscle hemorrhage as a rare cause of proximal tibial neuropathy. *J Clin Neurosci* 2014;21(3):520–1.
62. Patel AT, Gaines K, et al. Usefulness of electrodiagnostic techniques in the evaluation of suspected tarsal tunnel syndrome: an evidence-based review. *Muscle Nerve* 2005;32:236–40.