

A Clinical Approach to Disease of Peripheral Nerve



Rajeev Motiwala, MD

KEYWORDS

- Pattern of neuropathy • Symptoms of peripheral neuropathy
- Clinical examination in patients with suspected neuropathy • Screening • Referral

KEY POINTS

- Understand patterns of neuropathy and how they influence clinical evaluation.
- Review screening measures for neuropathy.
- Emphasize important features of history in patients with possible neuropathy.
- Learn about critical examination elements while approaching patients with suspected neuropathy.
- Recognize situations when urgent evaluation or specialty referral would be appropriate.



Video content accompanies this article at <http://www.geriatric.theclinics.com>.

INTRODUCTION

Peripheral neuropathy is one of the most common neurologic problems encountered by primary care physicians and geriatricians in particular. The prevalence in general population is about 2.4%, and it increases with age to approximately 8% in those older than 55 years.^{1,2}

These are conditions affecting peripheral nerves resulting in a variety of symptoms and signs, including pain, paresthesia (subjective complaint of tingling, numbness, crawling), impaired sensation, weakness, and alteration in gait.

It is important to remember that these symptoms can also result from involvement of other anatomic sites of the nervous system.

- Sensory symptoms can be caused by neuropathy, plexopathy, radiculopathy, myelopathy, and diseases involving central sensory pathways.
- Motor weakness can be caused by myopathy, neuromuscular junction disorder, neuropathy, plexopathy, radiculopathy, and diseases affecting anterior horn cells and motor pathways in the spinal cord or more central regions.

Department of Neurology, NYU Grossman School of Medicine, 222 East 41st Street, 9th Floor, New York, NY 10017, USA

E-mail address: rajeev.motiwala@nyulangone.org

Clin Geriatr Med 37 (2021) 197–208

<https://doi.org/10.1016/j.cger.2021.01.009>

geriatric.theclinics.com

0749-0690/21/© 2021 Elsevier Inc. All rights reserved.

A comprehensive history and physical examination often provide clues that the presenting problem is likely to be related to neuropathy.

Physicians dealing with geriatric population are faced with the following challenges:

1. When to suspect neuropathy based on symptoms
2. Routinely screen asymptomatic patients who have conditions such as diabetes mellitus, which put them at higher risk, and how to screen these patients quickly
3. How to counsel and treat patients with neuropathy
4. When to refer patients for subspecialty evaluation

PATTERN OF NEUROPATHY

The clinical presentation will vary depending on the pattern of neuropathy. Length-dependent neuropathies involve the longest nerve fibers first and tend to affect distal lower extremities at the onset. Non-length-dependent neuropathies can involve fibers regardless of length, and the symptoms can involve proximal and distal body parts, trunk, and face. If large fibers are involved predominantly, weakness and ataxia can result. Involvement of small fibers will cause pain and allodynia (pain elicited by non-noxious stimuli) without significant weakness. The most common pattern of neuropathy is characterized by length-dependent involvement of predominantly sensory fibers, both small and large. One or more large peripheral nerves can be involved, leading to asymmetric weakness and sensory loss as seen in mononeuritis simplex or multiplex. Autonomic fibers can be affected in addition to other nerve fibers, or they can be affected predominantly in isolation, resulting in specific features such as orthostatic hypotension, abnormalities of sweating, abnormalities of sphincter function, and sexual function.

It may be useful to conceptualize neuropathy based on anatomic pattern (**Fig. 1**) and size of nerve fibers involved (**Fig. 2**), and this will account for variability in symptoms and signs between different patients.^{3,4}

Historical elements that are important to address in a patient with suspected neuropathy:

1. Onset and time course:³⁻⁵
 - Acute onset and rapid progression may be seen in conditions such as Guillain-Barré syndrome, toxicity of chemotherapy, critical illness, vasculitis, infections.

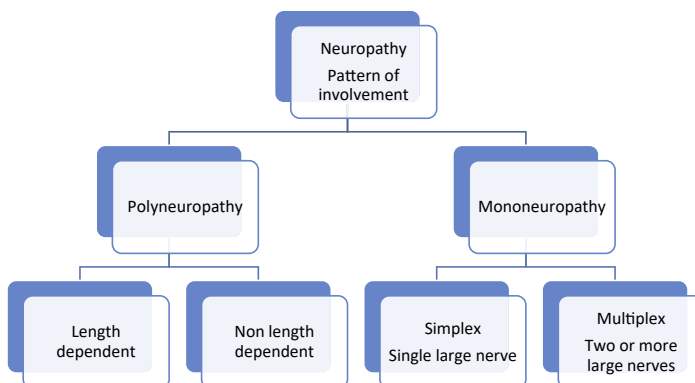


Fig. 1. Classification of neuropathy based on anatomic pattern.

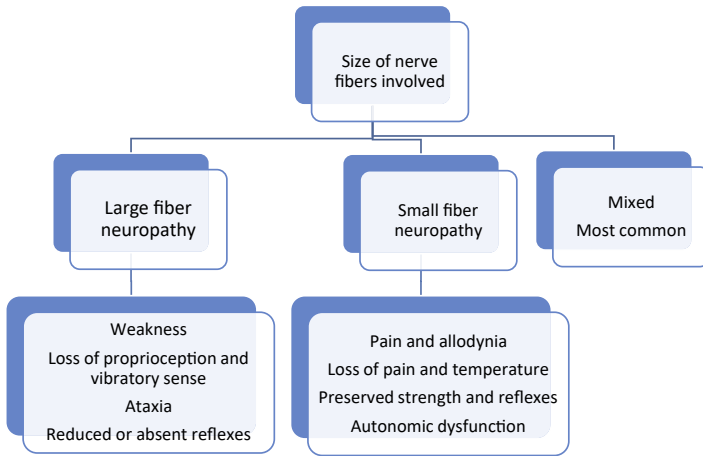


Fig. 2. Classification of neuropathy based on size of nerve fibers involved.

- Subacute onset and progression can be seen in chronic inflammatory demyelinating neuropathy, paraneoplastic neuropathy, and nutritional deficiency states.
 - Chronic or insidious onset with slow progression is the most common presentation in an outpatient setting. Causative conditions include diabetes, chronic alcohol use, and hereditary neuropathy (often unsuspected).
2. Associated comorbidities often provide a clue to the possible cause of neuropathy, and many of these conditions can be uncovered by comprehensive medical history:
 - Diabetes mellitus
 - History of chronic alcohol use
 - Other metabolic conditions such as thyroid disease and renal failure
 - Recent change in diet, weight loss, gastrointestinal disorders, and bariatric surgery leading to vitamin deficiencies, particularly vitamin B12 (cyanocobalamin) and vitamin B1 (thiamine)
 - History of underlying malignancy or treatment with chemotherapeutic agents
 - Human immunodeficiency virus (HIV) infection
 - Skin rash, arthritis, and known rheumatologic or autoimmune disease
 - History of possible environmental or occupational exposure (heavy metals, pesticides)
 3. Many medications can cause or contribute to development of neuropathy. Some notable common offending agents include the following:⁶
 - Antimicrobials: fluoroquinolones, metronidazole, nitrofurantoin, isoniazid, ethambutol, linezolid
 - Chemotherapeutic agents: vincristine, docetaxel, paclitaxel, oxaliplatin, thalidomide, bortezomib
 - Cardiovascular agent: amiodarone
 - Pyridoxine (vitamin B6): high doses often self-administered from health food sources
 - Nucleoside reverse-transcriptase inhibitors (antiretroviral agents) used for treatment of HIV infection: zalcitabine, didanosine, stavudine, lamivudine (newer agents are less likely to be responsible)
 - Statins: the association is not strong for clinically significant neuropathy but well described

- Immunosuppressants: biologics, interferons, leflunomide
 - Others: phenytoin, levodopa, disulfiram
4. Family history of neuropathy: patients with hereditary neuropathy would be expected to present at a younger age. However, it is not rare for patients to present later in life, particularly with milder forms of neuropathy. It is thought that some of the previously undiagnosed or cryptogenic cases may belong to this group.

SYMPTOMS OF PERIPHERAL NEUROPATHY

A typical patient with neuropathy is likely to report tingling and numbness in feet, recurrent episodes of sharp pain in toes, and mild lack of balance. The symptoms tend to evolve as the condition progresses.

The symptoms of peripheral neuropathy can be broadly conceptualized in many ways:

1. Symptoms related to involvement of sensory fibers, motor fibers, and autonomic fibers
2. Symptoms caused by involvement of small nerve fibers and large nerve fibers
3. Positive and negative symptoms depending on presumed mechanism of uninhibited activity or reduced activity of nerve fibers

Different symptoms of neuropathy can be attributed to involvement of sensory fibers, motor fibers, and autonomic fibers within the peripheral nerves (**Table 1**). Trophic changes are believed to be related to a variety of factors, including loss of neurotrophic factors. Many neuropathies result in dysfunction of all types of fibers, but some conditions can result in greater involvement of one subset over others.

Positive symptoms may result from uninhibited or abnormal spontaneous nerve activity, and these may include pain, cramps, and twitching. The type of pain can be quite variable. Neuropathic pain is described as burning, sharp, electric shock-like, but it can also be reported as deep aching pain. It is often useful to ask the patients to localize the pain whether it is on the surface or deep seated. In most length-dependent neuropathies the patients may initially complain that their feet feel as if

Table 1	
Symptoms of neuropathy	
Sensory	Numbness or loss of sensation Pain, tingling, burning feet Allodynia: pain elicited by a stimulus that generally should not induce pain Hyperalgesia: pain response is exaggerated after a stimulus that is capable of eliciting pain Paresthesia: tingling, crawling sensation described by the patient Unsteady gait and falls
Motor	Weakness: difficulty gripping objects, tendency to trip easily Loss of muscle mass Muscle twitching Muscle cramps
Autonomic	Postural dizziness and syncope Sexual dysfunction: erectile dysfunction, retrograde ejaculation Bladder involvement Easy satiety, constipation, or diarrhea Dryness of mouth, eyes, and skin
Trophic	Skin and joint changes Skin discoloration, callus, skin ulcers, enlarged joints (Charcot joints)

they are wrapped in stockings. The pain of neuropathy is often more noticeable at rest and during night.

Negative symptoms reflect reduced nerve activity and result in loss of sensation, weakness, ataxia, and atrophy. Patients with distal sensory loss may complain about delayed wound healing and tendency to lose balance after closing eyes or in dark surroundings.

The patients with distal weakness may develop hammer toes and complain of reduced grip strength. When the weakness spreads more proximally, they may report difficulty getting out of low chairs and problems climbing stairs. Recurrent tripping while stepping off curbs may reflect partial foot drop. More chronic conditions can result in deformities such as pes cavus.

Patients with mononeuropathy such as median neuropathy at wrist or carpal tunnel syndrome will complain about pain and nocturnal paresthesia in the affected hand. The symptoms of ulnar neuropathy may include tingling along the inner aspect of forearm and fourth and fifth fingers with numbness of those fingers. These symptoms may be triggered by elbow movements. A patient with radial nerve palsy may wake up with a wrist drop. Peroneal or fibular neuropathy can result in a foot drop but the patient may report slapping gait or tendency for the ankle to “turn” easily.

CLINICAL EXAMINATION IN PATIENTS WITH SUSPECTED NEUROPATHY

This is likely to vary depending on whether the intention is to screen patients for neuropathy who have known conditions such as diabetes mellitus or to evaluate patients presenting with clinical symptoms suggesting peripheral neuropathy.

Screening can be performed by using 2 or more tests:⁷

- Light touch perception using 10-g Semmes-Weinstein monofilament examination (cotton swab or cotton wisp is often substituted in clinical practice)
- Superficial pain or pinprick perception using a sharp pin or sharp end of a wooden stick
- Vibration testing with a 128 Hz tuning fork.
- Testing of ankle deep tendon reflexes

Annual screening is important in patients with known diabetes. Clanging tuning fork test may be used to replace the 10-g monofilament test as the recommended technique for detection of diabetic polyneuropathy.⁸ It is important to remember age-related decline in vibration sense and ankle reflexes in patients older than 65 years.^{9,10} These findings in otherwise healthy elderly people can obscure distinction from polyneuropathy.¹¹ An elderly individual with no symptoms and no risk factors for neuropathy is unlikely to have polyneuropathy simply based on the findings of decreased distal vibratory sensation and depressed or absent ankle reflexes. Positive findings on these screening tests should prompt further diagnostic workup.

The physical examination can help confirm the diagnosis of neuropathy suspected based on history and also provide more detailed information on what nerve fiber types may be affected (**Table 2**). Most nonneurologists do not feel comfortable performing a formal neurologic examination, but focusing on various test maneuvers that allow assessment of different components of the peripheral nerves may be useful. The examination also helps rule out other causes of weakness or sensory loss such as myopathy, radiculopathy, and central disorders. Presence of spasticity and hyperreflexia as seen in patients with upper motor neuron disorders would direct the examiner away from peripheral neuropathy as being the principal diagnosis.

1. Motor examination

Table 2 Summary of physical findings depending on type of nerve fibers involved	
Type of Peripheral Nerve Fibers Involved	Signs
Sensory	Glove and stocking sensory loss Sensory ataxia Positive Romberg sign Reduced or absent reflexes Pseudoathetosis
Motor	Distal weakness Atrophy and fasciculations in some cases Reduced or absent reflexes
Autonomic	Orthostatic hypotension Skin changes Abnormal sweating patterns Hyperemia or pallor
Trophic	Callus Painless ulcers in neuropathic joints Skin thinning and color changes Loss of hair in distal legs Nail changes

2. Sensory examination
3. Reflexes
4. Gait, Romberg sign
5. Assessment of autonomic dysfunction
6. Relevant cerebellar and cranial nerve examination
7. General examination

MOTOR EXAMINATION

Inspection

The classic teaching is that motor examination starts with inspection. In chronic neuropathies, one may expect to find signs of muscle atrophy in distal muscles. The small muscles of feet may develop atrophy, and there may be prominence of intermetatarsal spaces in feet, loss of prominence of extensor digitorum brevis muscle bulk over lateral aspect of dorsum of foot, and loss of plantar muscle fullness. In the upper extremities, there may be loss of muscle mass in the first web space over the dorsal aspect of hand and flattening of thenar and hypothenar muscle prominences. Intermittent spontaneous muscle twitching or fasciculations can be seen in some patients with neuropathy, although this finding is more prominent in anterior horn cell disorders.

Tone

The muscle tone is evaluated most commonly by moving different joints passively and judging resistance to passive range of motion. There will be reduced resistance and “floppiness” when tone is reduced in the presence of significant neuropathy.

Strength

It is useful to determine if the muscle weakness is symmetrical or asymmetrical. If it is asymmetrical, does it correspond to a single large nerve distribution? In length-dependent neuropathies, the weakness first involves distal muscles of lower extremities. Proximal muscle involvement in addition to distal muscle weakness in early stages can be seen with inflammatory neuropathies such as acute inflammatory demyelinating polyneuropathy and chronic inflammatory demyelinating polyneuropathy.

There are limitations to confrontational strength testing. The muscle strength often depends on patient's age, overall body habitus, conditioning, presence or absence of pain, and relative strength compared with the examiner. Incorporating functional testing may reveal specific functional disabilities along with subtle weakness that is often missed on confrontational strength testing. The patient may be asked to stand up from a seated position without support of the chair or perform knee bends to assess the proximal lower extremity strength. Walking on heels can allow detection of mild ankle dorsiflexor muscle weakness. Walking on toes can detect subtle ankle plantar flexor muscle weakness.

SENSORY EXAMINATION

Sensory symptoms and sensory findings often precede motor weakness in most common neuropathies. The sensory examination in its full extent involves testing of primary sensory modalities of light touch, pain, temperature, vibration, and proprioception (joint position). Testing of cortical sensory modalities includes evaluation of graphesthesia, stereognosis, and presence of sensory hemineglect. A detailed examination can become fairly tedious, and patient cooperation is paramount. A tailored approach based on patient's symptoms and the purpose of examination (screening or diagnostic) can guide the practitioner. In a patient with no sensory complaints, testing with a cotton wisp, pin, and tuning fork in feet may suffice.

It is important to remember that "large fibers" convey sensation of fine light touch, vibration, and proprioception (joint movement). These sensory modalities are tested with the help of a cotton wisp, tuning fork, and passive joint movements. "Small fibers" typically carry impulses from receptors responsible for perception of crude touch, pain, and temperature. These sensations are tested by response to sensation of cold and pin prick.

In most peripheral neuropathies, the sensory findings are prominent distally in lower extremities and then spread proximally as the condition progresses. Fingers can be involved after the symptoms have spread up to knees or lower thighs. It is useful to start sensory examination distally and compare distal segments with proximal segments, one side with the other side, and lower extremities with upper extremities. The classic pattern of sensory loss in peripheral neuropathy is "glove and stocking" type. It is important to remember that the sensation may not be absent and may simply show relative reduction in intensity and "distal to proximal gradient." It is unusual to find a sensory level on the trunk with loss of sensation below that level—this finding should raise consideration for an alternative localization such as spinal cord disease.

Light touch can be tested by using a cotton wisp or cotton swab starting distally and comparing distal segment with proximal and one side with the other. Sensation of pain is also assessed in a similar fashion using the sharp end of a stick, a safety pin, or a medipin. These are discarded after single use. Sensory examination over trunk can be reserved for patients who report sensory symptoms in that area or if the sensory

loss in lower extremities extends up to the groin. Patients with diabetic truncal neuropathy may have sensory loss over contiguous thoracic dermatomes. Sensation of cold is often assessed by applying the cool metallic surface of tuning fork to skin. The tuning fork can be run under cold water first to enhance sensitivity.

Vibration sense is best tested using a 128-Hz frequency tuning fork. The examiner should lightly tap the end of the tuning fork and place it against bony prominences, inner part of first metatarsophalangeal joint, or medial malleolus in the lower extremity and knuckles in the upper extremity. The examiner can serve as control, and if the patient reports not feeling vibration at all or reports that it stops before the examiner stops feeling it, some degree of vibratory loss is confirmed. If the vibration sense is absent distally, more proximal bony prominences should be assessed until a relatively normal sensation is detected. In one study, the mean duration of vibration sensation was 10.2 seconds and results of monofilament testing were abnormal only in those patients whose vibration perception was less than or equal to 4 seconds. The same study showed that “clanging tuning fork” test can detect diabetic peripheral neuropathy earlier and more accurately than 10-g monofilament test, and it should be used as the recommended technique for detection of diabetic peripheral neuropathy.⁸

Joint position sense is tested by moving interphalangeal joints of fingers and toes through a small range of movement while supporting the base of the digit proximally. If the joint position is absent in distal joints, more proximal joints should be tested. Patients who have significant proprioceptive loss may show presence of abnormal movements in the fingers of outstretched hands when their eyes are closed—this is called pseudoathetosis.¹²

Sensory loss in a pattern that differs from the typical distal or length-dependent pattern should prompt consideration of other diagnoses. If the sensory loss is in a dermatomal pattern, one may suspect radiculopathy. If the sensory loss conforms to a large peripheral nerve, a diagnosis of mononeuropathy should be entertained. For example, sensory loss along the lateral aspect of forearm and thumb would suggest C6 radiculopathy, and sensory loss over lateral aspect of leg and dorsum of foot may be consistent with peroneal neuropathy or L5 radiculopathy.

REFLEXES

The deep tendon reflexes are normal in patients with small fiber neuropathy. They are diminished or absent in patients with large fiber neuropathy, as an intact reflex arc is essential. The reflex arc includes sensory fibers, synapse within the spinal segment, and motor pathway. The reflexes will first be affected distally in a length-dependent fashion. The ankle reflexes will be diminished or absent. A significant asymmetry of reflexes is unusual and should suggest other associated condition. The patients in this age group may have coexisting radiculopathy, which would cause asymmetrical loss of reflexes or a condition such as cervical spondylotic myelopathy that may lead to relative preservation or prominence of deep tendon reflexes even in the face of neuropathy.

GAIT

Examination of gait can assess several neurologic functions. It is possible to judge balance by observing tandem gait, proximal lower extremity strength as indicated by stability of pelvis and hip musculature, and distal lower extremity strength as demonstrated by ability to walk on heels and toes. The patients may report their subjective experience by describing that when they walk barefoot there is a sensation of

walking on cracked glass or as if they are walking on cotton wool. The patients sometimes refer to unsteadiness as dizziness, and it is important to encourage them to explain in more detail what they are actually experiencing.

Abnormal gait is an important cause of frequent falls in the elderly.^{13,14} There are several mechanical and neurologic causes of abnormal gait, and peripheral neuropathy is an important cause. There are different gait patterns depending on the predominant deficit, proprioceptive loss, motor weakness, or presence of pain (**Table 3**).

Romberg sign is a test of proprioception, but it is often assessed during gait examination. Before the patient is asked to walk, it is useful to have them stand with feet close together after assuring a steady base. The patient is then asked to close their eyes, and the examiner stands close by to provide support if necessary. The patient may sway or lose balance and fall if Romberg sign is positive. This finding suggests proprioceptive loss, and when visual compensation is removed, the deficit becomes obvious. If the patient cannot stand with feet close together with eyes open, as in case of cerebellar disorders, Romberg test cannot be performed.

AUTONOMIC FUNCTION

A detailed assessment of autonomic function is outside the scope of a routine office examination. Some of the simple tests include checking for presence of orthostatic hypotension, abnormal sweating pattern, and changes in skin color or temperature. A drop in systolic blood pressure greater than 20 mm Hg and or diastolic blood pressure greater than 10 mm Hg in 3 minutes after assuming an upright position indicates orthostatic hypotension.¹⁵ In patients with autonomic neuropathy (they may have evidence of more generalized neuropathy in addition), there may be lack of compensatory tachycardia.

OTHER NEUROLOGIC EXAMINATION

Patients with neuropathy can have abnormalities in other aspects of the neurologic examination also. Patients with Guillain-Barré syndrome often have bilateral facial weakness. Diabetic neuropathy may be associated with pupillary abnormalities. Cerebellar examination is important to distinguish sensory ataxia from cerebellar ataxia. Dysarthria and nystagmus can be seen with cerebellar disorders and not with neuropathy.

Type of Gait	Description	Cause
Ataxic	Unsteady, wide based	Large fiber or proprioceptive loss
Stomping	The foot is raised higher than normal, and it is brought down harder	Often a component of ataxic gait due to loss of proprioception
Steppage gait	The ankle hangs with toes pointing down, the leg has to be lifted higher for toes to clear the ground	Weakness of ankle dorsiflexion
Antalgic gait	Cautious, slow, often unable to walk barefoot due to pain in soles	Small fiber involvement with hyperalgesia of soles

GENERAL EXAMINATION

A thorough general examination may reveal abnormalities in patients with neuropathy. Some examples are presence of orthostatic hypotension, suggesting autonomic involvement, glossitis in vitamin B12 deficiency, skeletal deformities such as pes cavus and scoliosis in hereditary neuropathy, skin rash in patients with vasculitis, and connective tissue disorders.

RECOMMENDED “BARE MINIMUM” EXAMINATION IN PATIENTS WITH SUSPECTED NEUROPATHY

As demonstrated in [Video 1](#),

- Check at least one proximal muscle group in upper extremities by asking them to raise both arms fully against gravity and resistance.
- Check distal muscles in upper extremity by confirming that the hand grip is strong and symmetric on both sides.
- Check gait. Is the gait steady and narrow based? Can the patient stand up without assistance and walk on heels, toes, and perform tandem gait? This will also allow assessment of proximal and distal lower extremity muscle strength.
- Check sensation in feet; vibration and pin prick.
- Check ankle reflexes.

HOW CAN INITIAL EVALUATION POINT TOWARD POSSIBLE CAUSE OF NEUROPATHY IN PATIENTS?

Further workup of neuropathy will be addressed in subsequent chapters. It is clear that a shotgun approach to diagnosis with a large number of blood tests and electrodiagnostic studies is not cost-effective in most patients with neuropathy. The initial clinical evaluation, assessment of risk factors, and recognizing specific patterns of neuropathy can be of tremendous help.

- An acute or subacute onset suggests immune-mediated or infectious process.
- A chronic or insidious onset indicates metabolic, toxic, or hereditary cause.
- Diabetes mellitus is possibly the most common cause of neuropathy in geriatric population. Neuropathic symptoms may be seen in patients with impaired glucose tolerance before development of overt diabetes.^{16,17}
- A comprehensive evaluation that includes medical history, neurologic examination, simple screening laboratory tests, and electrodiagnostic studies yields an etiologic diagnosis in 74% to 82% of patients with polyneuropathy.¹⁸
- Small fiber neuropathy can be idiopathic but it is also common in diabetic patients.
- Prominent autonomic component suggests diabetes, amyloidosis, and autoimmune causes.

PATIENTS WITH SUSPECTED NEUROPATHY WHO SHOULD BE CONSIDERED FOR NEUROLOGIC CONSULTATION AND ADDITIONAL DIAGNOSTIC STUDIES

- Acute onset
- Rapidly progressive
- Severe functional limitation
- Significant asymmetry
- Pure or predominant motor symptoms
- Pure or predominant autonomic symptoms

- Bulbar symptoms including difficulties in speech, swallowing, and breathing
- Mononeuropathy multiplex

TREATMENT

The various aspects of specific treatment depending on the cause of neuropathy will be addressed in subsequent chapters. The treatment rationale is guided by the following principles:

- It is critical to identify those patients who need specialty referral, urgent intervention, or hospitalization, for example, patients with Guillain-Barré syndrome.
- Specific treatment measures include optimizing blood glucose control in patients with diabetes, reducing or removing exposure to offending agents such as alcohol, correction of vitamin deficiency, and addressing metabolic factors such as hypothyroidism.
- Demyelinating neuropathies in particular may be amenable to immunomodulatory therapies.
- Symptomatic treatment includes use of various agents to control neuropathic pain.
- Proper foot care, fall prevention, physical therapy, occupational therapy, use of orthotics, and other assistive devices for ambulation are often the most important long-term and ongoing interventions that can improve the quality of life.

CLINICS CARE POINTS

- The prevalence in general population is about 2.4%, and it increases with age to approximately 8% in those older than 55 years.
- Neuropathies can be length dependent with distal predominance, non-length dependent or can involve individual large nerves as in mononeuropathy simplex and mononeuropathy multiplex.
- Clinical symptoms and physical findings vary depending on whether small nerve fibers, large nerve fibers, or both types of nerve fibers are involved.
- Screening for presence of neuropathy can be accomplished quickly by testing feet with light touch, pin prick, or 128-Hz tuning fork and by checking ankle reflexes. Testing of vibratory sense is the most single reliable test.
- The onset, time course, associated medical conditions, medications, and family history are important historical elements.
- A comprehensive examination in patients suspected to have neuropathy includes motor examination, sensory examination, reflexes, and gait assessment in addition to pertinent elements of rest of the nervous system and general physical examination.
- It is important to recognize conditions that may potentially progress rapidly or require specific therapeutic intervention.

ACKNOWLEDGMENTS

Arielle Kurzweil, MD, Associate Professor of Neurology, NYU Grossman School of Medicine. Hao Huang, MD, Fellow, Headache Medicine, Department of Neurology, NYU Grossman School of Medicine.

DISCLOSURE

The author has no disclosures.

SUPPLEMENTARY DATA

Supplementary data related to this article can be found online at <https://doi.org/10.1016/j.cger.2021.01.009>.

REFERENCES

1. Martyn CN, Hughes RAC. Epidemiology of peripheral neuropathy. *J Neurol Neurosurg Psychiatry* 1997;62(4):310–8.
2. Italian General Practitioner Study Group (IGPSG). Chronic symmetric symptomatic polyneuropathy in elderly: a field screening investigation in two Italian regions, I: prevalence and general characteristics of the sample. *Neurology* 1995;45(10):1832–6.
3. Hughes RAC. Peripheral neuropathy. *BMJ* 2002;324:466–9.
4. England JD, Asbury AK. Peripheral neuropathy. *Lancet* 2004;363:2151–61.
5. Watson JC, Dyck PJB. Peripheral neuropathy: a practical approach to diagnosis and symptom management. *Mayo Clinic Proc* 2015;90(7):940–51.
6. Jones MR, Urits I, Wolf J, et al. Drug-induced peripheral neuropathy: a narrative review. *Curr Clin Pharmacol* 2020;15:38–48.
7. Perkins BA, Olaleye D, Zinman B, et al. Simple screening tests for peripheral neuropathy in diabetes clinic. *Diabetes Care* 2001;24(2):250–6.
8. Oyer D, Saxon D, Shah A. Quantitative assessment of diabetic peripheral neuropathy with use of the clanging tuning fork test. *Endocr Pract* 2007;13(1):5–10.
9. Odenheimer G, Funkenstein HH, Beckett L, et al. Comparison of neurologic changes in 'successfully aging' persons vs the total aging population. *Arch Neurol* 1994 Jun;51(6):573–80.
10. Gladstone DJ, Black SE. The neurological examination in aging, dementia and cerebrovascular disease. *Geriatrics and Aging*. 2002;5(7):36–43.
11. Vrancken AF, Kalmijn S, Brugman F, et al. The meaning of distal sensory loss and absent ankle reflexes in relation to age. A meta-analysis. *J Neurol* 2006;253:578–89.
12. Lo YL. See S. Pseudoathetosis. *N Engl J Med* 2010;363(19):e29.
13. Verghese J, Ambrose AF, Lipton RB, et al. Neurological gait abnormalities and risk of falls in older adults. *J Neuro* 2010;257(3):392–8.
14. Pirker W, Katzenschlager R. Gait disorders in adults and the elderly. *Wien Klin Wochenschr* 2017;129(3):81–95.
15. Lanier JB, Mote MB, Clay EC. Evaluation and management of orthostatic hypotension. *Am Fam Physician* 2011;84(5):527–36.
16. Singleton JR, Smith AG, Broomberg MB. Increased prevalence of impaired glucose tolerance in patients with painful sensory neuropathy. *Diabetes care* 2001;24(8):1448–53.
17. Singleton JR, Smith AG, Broomberg MB. Painful sensory polyneuropathy associated with impaired glucose tolerance. *Muscle Nerve* 2001;24(9):1225–8.
18. England JD, Gronseth GS, Franklin G, et al. Practice Parameter: evaluation of distal symmetric polyneuropathy: role of laboratory and genetic testing (an evidence based review): report of the American Academy of Neurology, American association of neuromuscular and electrodiagnostic medicine, and American Academy of Physical Medicine and Rehabilitation. *Neurology* 2009;72(2):185–92.