# Update on the Treatment of Giant Cell Arteritis and Polymyalgia Rheumatica

Sarah El Chami, MBBS[a], Jason M. Springer, MD, MS[b,*]

**KEYWORDS**

• Giant cell arteritis • Polymyalgia rheumatica • Large vessel vasculitis
• Temporal arteritis • Tocilizumab

**KEY POINTS**

- Frequently, polymyalgia rheumatica (PMR) and giant cell arteritis (GCA) overlap in the same patient. PMR may be a forme fruste of GCA.
- Although the cranial phenotype is the most common phenotype of GCA, other phenotypes exist and need to be recognized.
- Temporal artery biopsy remains the gold standard for diagnosis of GCA with new roles for cranial imaging in diagnosis and management.
- Screening for large vessel involvement should be performed in all cases of GCA, as it is often asymptomatic and associated with a poorer prognosis.
- Glucocorticoids remain the cornerstone of treatment in both GCA and PMR with an emerging role for steroid-sparing agents. The results of a randomized controlled trial demonstrated tocilizumab to be effective in the treatment of GCA.

## GIANT CELL ARTERITIS

### *Introduction*

Giant cell arteritis (GCA) is the most common form of primary systemic vasculitis in North America with an incidence greater than 17 per 100,000 in those older than 50 years. This disease almost always affects individuals older than 50 years with a peak incidence in the 70- to 79-year age group. The incidence of GCA increases with latitude in the Northern hemisphere. GCA much more commonly affects women (3:1 ratio of women to men) and Caucasian populations, with a low incidence in black, Hispanic, and Asian populations.[1] Early recognition and prompt treatment of GCA is crucial to prevent catastrophic ischemic complications.

This article originally appeared in the Medical Clinics of North America, Volume 105, Issue 2, March 2021.
[a] The University of Kansas Health System, 4000 Cambridge Street, MS 2026, Kansas City, KS 66160, USA; [b] Vanderbilt University Medical Center 1161 21st Avenue South, T-3113 Medical Center North Nashville, TN 37232-2681, USA
* Corresponding author.
*E-mail address:* jason.springer@vumc.org

Rheum Dis Clin N Am 48 (2022) 493–506
https://doi.org/10.1016/j.rdc.2022.02.007 **rheumatic.theclinics.com**
0889-857X/22/© 2022 Elsevier Inc. All rights reserved.

Descargado para Eilyn Mora Corrales (emorac17@gmail.com) en National Library of Health and Social Security de ClinicalKey.es por Elsevier en mayo 24, 2022. Para uso personal exclusivamente. No se permiten otros usos sin autorización. Copyright ©2022. Elsevier Inc. Todos los derechos reservados.

### *Clinical Phenotypes*

de Boysson and colleagues[2] identified 4 clinical patterns of GCA in a retrospective analysis of 693 patients with GCA. The cranial phenotype, constituting 80% of cases, presents with temporal headache, temporal artery abnormalities (eg, tenderness or decrease pulsation), jaw/tongue claudication, and/or scalp tenderness. This phenotype has the highest risk of early ocular ischemic events. The presence of intracranial involvement is not characteristic of GCA and should prompt consideration of an alternative diagnosis. Another pattern includes large vessel involvement (ie, the aorta and its major branches), present in 9% of cases. Common clinical features include limb claudication, asymmetric peripheral pulses, lightheadedness, hypertension, subclavian steal syndrome, aortic aneurysms, and aortic valve regurgitation. The third group, representing about 9% of patients, presents with fever of unknown origin and elevated inflammatory markers. The final group includes patients who clinically seem to have isolated polymyalgia rheumatica (PMR) but have evidence of asymptomatic vasculitis on arterial biopsy or imaging. However, it is recognized that these phenotypes are not mutually exclusive, with a subset of patients demonstrating overlapping clinical features.

### *Diagnosis*

The diagnosis of GCA can be confirmed by either a temporal artery biopsy (TAB) or imaging showing arteritis. However, both modalities can have false-negative results rendering it challenging to completely rule out the disease, especially when a high index of suspicion exists.

#### *Temporal artery biopsy*

Classic histologic changes include chronic granulomatous inflammation generally concentrated at the level of the internal elastic lamina, intimal hyperplasia, giant cell formation, fragmentation of the internal elastic lamina, and vessel wall necrosis. The inflammatory infiltrate consists of epithelioid histiocytes, multinucleated giant cells, T lymphocytes, and macrophages. The inflammatory infiltrate is thought to initially enter through the vasa vasorum and progress from the adventitia inwardly within the arterial wall.[3] Inflammation can progress in a patchy distribution along the artery, leaving some areas of the artery unaffected. Within this age group, polyarteritis nodosa– and antineutrophil cytoplasmic antibody–associated vasculitis can also cause inflammatory changes of the temporal artery or surrounding vessels, mimicking GCA pathologically. A fibrotic pattern, reflecting damage from prior inflammation, can be difficult to differentiate from normal arterial aging of the temporal artery.[4]

The temporal artery biopsy has been considered by many as the gold standard for diagnosis. However, because of the patchy nature of the inflammatory infiltrate, a negative biopsy does not rule out the disease. The sensitivity can vary depending on the center and prevalence of disease. One study showed that 87% of patients with negative biopsies were continued on glucocorticoids based on clinical concerns for GCA.[5] In the presence of a very high clinical suspicion, histologic confirmation may not be needed. The authors recommend obtaining temporal artery biopsies in patients with cranial symptoms suspicious for GCA when there is diagnostic uncertainty and/or an atypical presentation.

The length and laterality of the temporal artery biopsy is another important consideration. Postfixation lengths of at least 2 cm are ideal but can be difficult to achieve in clinical practice. A 2006 retrospective review of more than 1000 temporal artery biopsies suggested that even a 0.5 cm biopsy can be adequate.[6] The symptomatic side of the head should be the target of the biopsy. Obtaining bilateral temporal artery

Descargado para Eilyn Mora Corrales (emorac17@gmail.com) en National Library of Health and Social Security de ClinicalKey.es por Elsevier en mayo 24, 2022. Para uso personal exclusivamente. No se permiten otros usos sin autorización. Copyright ©2022. Elsevier Inc. Todos los derechos reservados.

biopsies can increase the yield modestly. Bilateral temporal artery biopsies have been estimated to have a discordance rate of 4.4%.[7] Based on the expertise of the center a contralateral biopsy could be considered, either done after a negative finding on frozen section of the initial biopsy or simultaneously. Procedural complications are rare but can include infection, nerve damage, bleeding, and scarring. Obtaining a TAB should be done as soon as feasible; however, several studies have shown that a biopsy remains useful even after several weeks of treatment. TAB results can change after initiation of glucocorticoid therapy showing atypical features or healing arteritis.[8]

### *Imaging*

**Cranial imaging** There is limited evidence supporting the use of head MRI for the diagnosis of GCA with cranial artery involvement. Bley and colleagues[9] have shown high-resolution contrast-enhanced MRI of the cranial arteries had a sensitivity of 81% and specificity of 97% based on the 1990 American College of Rheumatology (ACR) criteria (91% sensitivity and 73% specificity based on histologically confirmed cases). However, these results depend on the strength of the magnet (3 T preferred) and the protocol used.[10,11] The sensitivity is dramatically reduced when imaging is done after 5 to 10 days of starting glucocorticoids.[9,12]

Color doppler ultrasonography (CDUS) is a noninvasive means to assess cranial arteries in GCA. The presence of a halo sign, stenosis, or occlusion of the common temporal artery, its branches, or the facial artery can be used to support the diagnosis of GCA. However, the utility of CDUS for diagnosis of GCA highly depends on the experience of the ultrasonographer. In a large, prospective, multicenter study including 381 patients with newly suspected GCA, a training program for CDUS of the temporal and axillary arteries was implemented.[13] Using the 1990 ACR classification criteria and final clinical diagnosis, CDUS had a higher sensitivity (54% [95% confidence interval [CI] 48%–60%] vs 39% [95% CI 33%–46%]) but lower specificity (81% [95% CI 73%–88%] vs 100% [95% CI 97%–100%]) compared with temporal artery biopsy. Using an approach of first evaluating with CDUS followed by a temporal artery biopsy in those with negative CDUS, the sensitivity increased to 65% while maintaining a specificity of 81%, reducing the need for biopsies by 43%. Inter-rater agreement for CDUS was moderate ($r = 0.69$, 95% CI 0.48–0.75), but similar to the inter-rater agreement for pathology assessment ($r = 0.62$, 95% CI 0.49–0.76). Of note, CDUS was done within 7 days of starting glucocorticoids.

The sensitivity and specificity of high-resolution MRI and CDUS for diagnosis of cranial GCA seems to be comparable.[14] However, the utility of these imaging modalities depend on the availability of appropriate equipment, protocols, and center experience with these modalities. Thus, for many centers TAB remains the preferred diagnostic modality for patients with suspected GCA presenting with cranial manifestations.

**Large vessel imaging** GCA is known to involve a larger network of vessels outside of cranial vasculature (ie, the aorta and major branches). Large-artery complications, including thoracic or abdominal aortic aneurysm and/or dissection, are associated with a high mortality.[15] This mandates the need for early detection through screening with appropriate follow-up. The presence of physical examination abnormalities in patients with established large vessel vasculitis (eg, absent carotid or radial pulse, carotid or subclavian bruit, or systolic blood pressure difference of more than 10 mm Hg) has a sensitivity as low as 14% in detecting arterial abnormalities in large vessel vasculitis and should be supplemented by imaging.[16] The estimated rate of asymptomatic large vessel involvement is 30% to 80%.[17] Conventional angiography has been largely replaced by noninvasive imaging for screening purposes but still

Descargado para Eilyn Mora Corrales (emorac17@gmail.com) en National Library of Health and Social Security de ClinicalKey.es por Elsevier en mayo 24, 2022. Para uso personal exclusivamente. No se permiten otros usos sin autorización. Copyright ©2022. Elsevier Inc. Todos los derechos reservados.

appropriate for interventional procedures in cases of critical stenosis or aneurysmal dilation. Otherwise, there is not a clearly preferred modality for the evaluation of extracranial large vessel involvement.

Computed tomography angiography (CTA), PET/CT, and MR angiography (MRA) are all noninvasive modalities that can be used either for diagnosis or follow-up monitoring of large vessel disease (Fig. 1). CTA offers the advantage of giving a high degree of anatomic detail, but the radiation exposure may make this a less desirable option for long-term follow-up. PET/CT has the highest sensitivity of picking up aortic

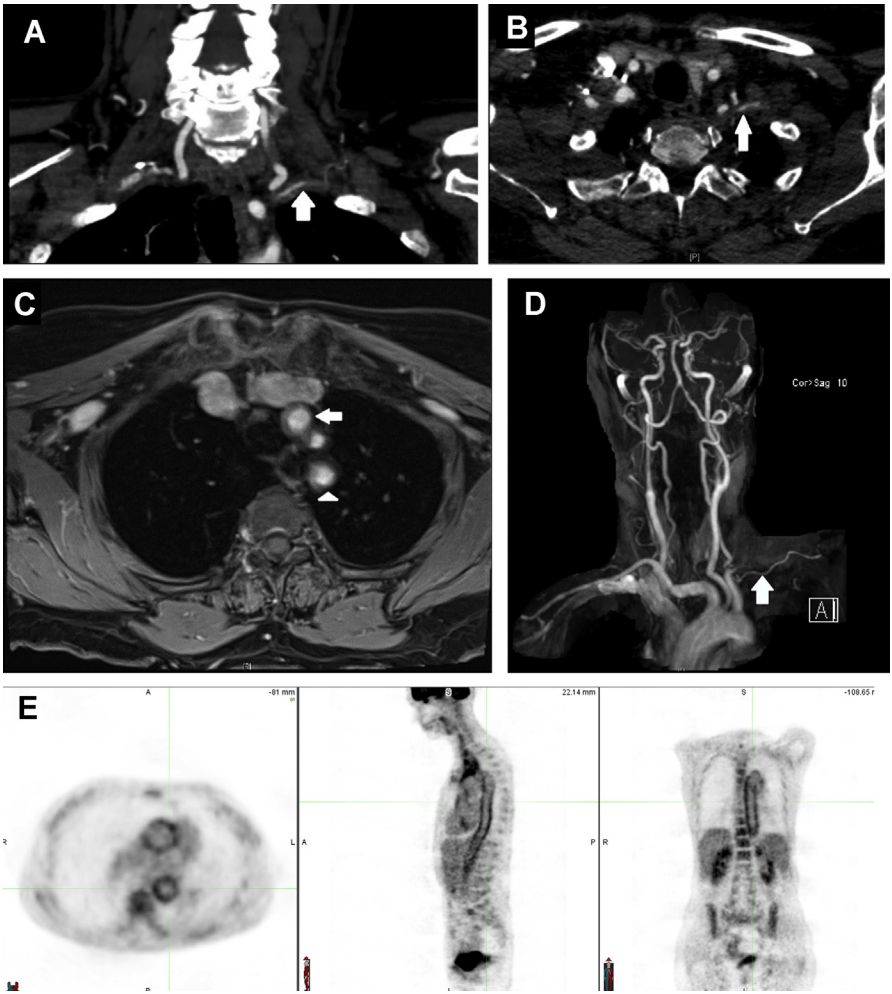


**Fig. 1.** A 64-year-old woman with predominantly large vessel involvement. CTA with and without contrast showing abrupt occlusion of the left subclavian artery (*arrow* in *A* and *B*). High-resolution MRI of the head and neck with and without contrast demonstrates mural thickening and contrast enhancement of the left brachiocephalic artery (*arrow* in *C*) and left subclavian artery (*arrowhead* in *C*). Left subclavian artery vessel wall occlusion with collateral formation (*arrow* in *D*). (*E*) Thoracic and abdominal aortitis in a separate patient as imaged by PET/CT.

Descargado para Eilyn Mora Corrales (emorac17@gmail.com) en National Library of Health and Social Security de ClinicalKey.es por Elsevier en mayo 24, 2022. Para uso personal exclusivamente. No se permiten otros usos sin autorización. Copyright ©2022. Elsevier Inc. Todos los derechos reservados.

inflammation, making it a good option to assist with the diagnosis of GCA; however, the uptake is not specific for GCA. Forms of secondary large vessel vasculitis (eg, syphilis, tuberculosis, sarcoidosis) and atherosclerosis can all mimic GCA on PET/CT. The high cost, limited accessibility, and radiation exposure make PET/CT a less desirable option for long-term follow-up of patients with large vessel involvement. MRA offers the advantage of good visualization of the arterial wall for inflammatory changes. Because of the lack of radiation exposure, it may be a preferable option for follow-up imaging for patients with known large vessel disease in centers with accessible equipment (3T magnet preferred) and experienced radiologists. The use of gadolinium-based contrast agents in patients with estimated glomerular filtration rate less than 30 mL/min/1.73 $m^2$ is associated with the development of nephrogenic systemic fibrosis. Although the use of newer contrast agents has substantially decreased that risk, clinician should still use caution in patient with chronic renal insufficiency.

CDUS can provide information on some of the more superficial large arteries (eg, subclavian, axillary, abdominal aortic, and common femoral arteries), with the highest sensitivity in the subclavian and axillary arteries.[18] However, in this setting CDUS has multiple limitations including inability to visualize many large arteries, the time-intensive nature of examination, and the dependence of the expertise of the sonographer. CDUS may be a valuable alternative in patients unable or with contraindications to other imaging modalities (eg, chronic renal insufficiency).

The choice and frequency of large vessel imaging depend on the clinical setting. In patients with known large vessel involvement, follow-up imaging is recommended. Although the optimal frequency is not established, the authors recommend obtaining imaging every 6 to 12 months until vascular stability has been established. In patients without known large vessel involvement, baseline imaging is recommended with follow-up imaging based on suspicious clinical features (eg, extremity claudication, unexplained elevations in inflammatory markers, and asymmetrical pulses and/or blood pressure). Given the known increased mortality of thoracic aortic aneurysm and dissection, yearly echocardiogram and chest radiograph to screen for these potential complications should be considered in all patients with GCA if more advanced imaging is not already being done (**Table 1**).

## *Glucocorticoid Effects on Diagnostic Modalities*

Although glucocorticoids can decrease the sensitivity of many diagnostic modalities, prompt treatment should not be withheld in those with a high clinical suspicion while waiting for completion of diagnostic testing. A large retrospective study that included 535 patients with GCA demonstrated a similar rate of positive biopsies in untreated and treated patients even after 14 days of therapy.[8] Glucocorticoids can quickly affect finding on imaging. Thus, noninvasive imaging modalities are best done within 4 to 5 days of starting glucocorticoids to pick up acute inflammation.[12,19]

### *Laboratory studies*

Unfortunately, there are no biomarkers that are specific to the diagnosis of GCA. Erythrocyte sedimentation rate (ESR) and C-reactive protein (CRP) are typically elevated but not specific. In a large retrospective study that included 177 patients with biopsy proven GCA, elevated CRP and elevated ESR provided a sensitivity of 87% and 84%, respectively, for a positive TAB. On the other hand, the presence of normal ESR and CRP did not exclude the diagnosis of GCA, as 4% of these patients had normal ESR and CRP.[20] Patients can also have anemia of chronic disease or elevated alkaline phosphatase.

Descargado para Eilyn Mora Corrales (emorac17@gmail.com) en National Library of Health and Social Security de ClinicalKey.es por Elsevier en mayo 24, 2022. Para uso personal exclusivamente. No se permiten otros usos sin autorización. Copyright ©2022. Elsevier Inc. Todos los derechos reservados.

**Table 1**
**Comparison of noninvasive diagnostic imaging modalities in giant cell arteritis**

| Imaging Modality | Advantages | Disadvantages |
|---|---|---|
| CTA | • Noninvasive<br>• Accessible<br>• High anatomic detail<br>• Information on vessel wall inflammation | • Radiation exposure<br>• Need for iodinated contrast<br>• Limitation in use with patient with renal insufficiency |
| PET/CT | • Noninvasive<br>• Highest sensitivity for vessel wall inflammation | • High cost<br>• Accessibility<br>• Radiation exposure<br>• Uptake is not specific for vasculitis |
| MRI/MRA<br>Cranial MRI<br>Large vessel MRA | • Noninvasive<br>• No radiation exposure<br>• Evaluates both vessel wall inflammation and structure | • High cost<br>• Limited use in those with renal impairment or metal implants<br>• Difficult in claustrophobic patients<br>• Need for radiologist expertise |
| CDUS<br>Cranial<br>Large vessel | • Noninvasive<br>• No radiation exposure<br>• Low cost<br>• Evaluates both vessel wall structure and inflammation<br>• Limited evaluation of large vessels | • Operator dependent<br>• Not ideal for visualization of thoracic aorta |
| Echocardiogram | • Noninvasive<br>• No radiation exposure<br>• Low cost<br>• Screening for ascending thoracic aortic aneurysms | • Limited to evaluation of the aortic root<br>• Advanced imaging required if abnormal |
| Chest radiograph | • Noninvasive<br>• Minimal radiation exposure<br>• Low cost<br>• Screening for thoracic aortic aneurysm | • No detail on vessel wall.<br>• Limited to thoracic aorta.<br>• Advanced imaging required if abnormal<br>• Findings might not correlate with final diagnosis |

Descargado para Eilyn Mora Corrales (emorac17@gmail.com) en National Library of Health and Social Security de ClinicalKey.es por Elsevier en mayo 24, 2022. Para uso personal exclusivamente. No se permiten otros usos sin autorización. Copyright ©2022. Elsevier Inc. Todos los derechos reservados.

## *Treatment of Giant Cell Arteritis*

### *Glucocorticoids*

Prompt initiation of glucocorticoids is required to prevent the dreaded ischemic complications including irreversible vision loss. There are conflicting reports behind the use of intravenous, "pulse" glucocorticoids. A double-blinded placebo-controlled study including 27 patients with biopsy-proven GCA showed induction with methylprednisolone, 15 mg/kg/d, for 3 days permits a shorter course of therapy, higher sustained remission, and lower median dose of steroids compared with placebo.[21] On the other hand, another randomized multicenter prospective trial showed no added benefit of using a single infusion of 240 mg intravenous methylprednisolone, a much lower dose, in terms of time needed to taper off glucocorticoids, mean cumulative prednisone dose, or steroid-related side effects.[22] In the setting of vision loss due to ischemic complications the authors recommend the use of intravenous pulse glucocorticoids followed by oral, as endorsed by both the European League Against Rheumatism and the British Society for Rheumatology.[23,24] Vision loss in patients with GCA is most commonly from arteritic anterior ischemic optic neuropathy (AAION), which, compared with nonarteritic anterior ischemic optic neuropathy, rarely improves. AAION can involve the contralateral eye. Hence, it is imperative to promptly start glucocorticoid treatment to prevent contralateral eye involvement.

Patients require initial high doses of oral glucocorticoids, typically followed by a prolonged taper with a mean duration of treatment ranging from 31 to 40 months.[25,26] Alternate day dosing of oral glucocorticoids is not recommended, as patients can become symptomatic on days not taken.[27] The frequent relapses and glucocorticoid-related side effects with glucocorticoid monotherapy has led to the investigation of other immunosuppressive medications to limit the cumulative glucocorticoid exposure.

### *Tocilizumab*

A phase II randomized, double-blind, placebo-controlled trial supported intravenous tocilizumab for the treatment of GCA. Patients in the treatment group received 13 infusions of intravenous tocilizumab (8 mg/kg, once monthly) along with a standardized prednisone taper. Eighty percent of patients in the tocilizumab group tapered prednisone to 0 mg by 52 weeks compared with 20% of patients in the placebo group, and the cumulative dose of prednisone was significantly higher in the placebo group at week 52 (67 mg/kg difference). There were no infusion-related adverse events, and the overall adverse events were similar in the 2 groups. Serious adverse events were higher in the placebo group. Neutropenia was an adverse event noted in tocilizumab group (4 patients) but not in the placebo group. No relapses occurred in the tocilizumab group by 52 weeks.[28]

In a phase III randomized double-blinded placebo-controlled trial 251 patients with GCA were randomized to 4 groups: 2 arms receiving tocilizumab, 162 mg, weekly or every other week injections combined with a 26-week prednisone taper and 2 placebo groups that received a prednisone taper over 26 or 52 weeks. The tocilizumab groups had a superior glucocorticoid-free remission compared with either of the control groups. Neutropenia was slightly higher in the tocilizumab group; otherwise, the rate of adverse events did not differ between the 2 groups. There were no bowel wall perforations seen; however, patients at higher risk (ie, prior history of diverticulitis or gastrointestinal perforation) were excluded given previous data of increased risk of lower gastrointestinal perforation with tocilizumab treatment in patients with rheumatoid arthritis.[29] Patients in the placebo groups received almost double the cumulative glucocorticoid dose. Weekly tocilizumab resulted in greater disease control compared

Descargado para Eilyn Mora Corrales (emorac17@gmail.com) en National Library of Health and Social Security de ClinicalKey.es por Elsevier en mayo 24, 2022. Para uso personal exclusivamente. No se permiten otros usos sin autorización. Copyright ©2022. Elsevier Inc. Todos los derechos reservados.

with every other week; however, both tocilizumab groups fared better than placebo groups.[30] There have been isolated reports of patients found to have active arteritis by biopsy despite apparent good disease control with tocilizumab, which has raised concern by some that tocilizumab may be blunting clinical symptoms without fully controlling the underlying disease process.[31]

The optimal duration of tocilizumab treatment remains unknown. A 2-year extension of the phase III trial demonstrated that a significant number of patients relapsed after stopping tocilizumab after 1 year. However, patients who developed a relapse responded to retreatment with tocilizumab.[32] Based on these data, the authors suggest continuing tocilizumab treatment of at least 2 years. This decision needs to be determined on case-by-case basis while weighing risks versus benefits of continued therapy in individual patients.

Although both intravenous and subcutaneous routes of treatment with tocilizumab can be effective treatment options, there are important points to keep in mind before initiating treatment. Tocilizumab has a blunting effect on the acute phase response of the liver making the sedimentation rate and CRP less reliable biomarkers. A careful assessment of the risks and benefits should be exercised in patients at higher risk of bowel perforation (eg, prior history of diverticulitis or gastrointestinal perforation). Many patients can develop significant hypercholesterolemia with a mean increase in nonfasting total cholesterol level by 35 mg/dL at 12 months; however, subsequent cholesterol levels generally remain stable. The increase in the cholesterol level is not paralleled with an increase in cardiovascular events.[33] Tocilizumab prescribing information recommend assessing lipid parameters approximately 4 to 8 weeks following initiation of therapy, then at approximately 24-week intervals.

### *Other agents*

There are conflicting reports regarding the use of methotrexate (MTX) in the treatment of GCA. Three randomized double-blind placebo-controlled trials were published on treatment with methotrexate (MTX) in GCA between 2001 and 2002.[34–36] The differences in results may be explained by the duration of MTX treatment, with the steroid-sparing effects seen most prominently in those treated for at least 24 months (compared with 12–17 months). A meta-analysis of the abovementioned trials concluded the addition of MTX reduces the risk of first relapse by 35% and that of second relapse by 51%. This was associated with a reduction in cumulative prednisone dose and a higher probability of achieving sustained remission.[37] The authors recommend the use of MTX as a second-line option in those patients with relapsing/refractory disease or with contraindications to tocilizumab, such as hypersensitivity reactions to tocilizumab or increased risk of GI perforation, at doses of at least 15 mg weekly (oral or subcutaneous) for at least 24 months.

Abatacept, a cytotoxic T-lymphocyte antigen 4 mimetic, and ustekinumab, an interleukin-12 (IL-12) and IL-23 inhibitor, have shown promising results in small clinical trials. Larger trials are warranted to further evaluate the effectiveness of both those treatments in GCA. Tumor necrosis factor (TNF) inhibitors have not been shown to have a benefit in GCA.

### *Adjunctive therapies*

There have been conflicting reports regarding the use of low-dose aspirin as a preventative measure against arterial complications in GCA. A retrospective study by Salvarani and colleagues[38] showed patients who were on antiplatelet or anticoagulation therapy had higher risk of developing cranial ischemic events. This may reflect the higher propensity for patients with more cardiovascular risk factor to receive aspirin.

Descargado para Eilyn Mora Corrales (emorac17@gmail.com) en National Library of Health and Social Security de ClinicalKey.es por Elsevier en mayo 24, 2022. Para uso personal exclusivamente. No se permiten otros usos sin autorización. Copyright ©2022. Elsevier Inc. Todos los derechos reservados.

Another retrospective study showed that low-dose aspirin decreases the rate of visual loss and cerebrovascular accidents in patients with GCA by 5 times.[39] Although there are no randomized trials addressing the use of aspirin in GCA, the authors recommend use of low-dose aspirin in patients without contraindications, such as the use of other antiplatelet or anticoagulant drugs. A retrospective study published in 2007 did not find evidence of statin benefit in decreasing the incidence of ischemic complications or disease outcome.[40]

## POLYMYALGIA RHEUMATICA

PMR is also more common in white individuals of northern European background, women and older individual, with a mean age around 74 years. Individuals of Asian, African American, American Indian, or other races were much less likely to be affected.[41] PMR is 2 to 3 times more common than GCA.[1,42] It is estimated that 40% to 60% of patients with GCA have PMR. Only 16% to 21% of patients with PMR have GCA, although large vessel involvement may be underrecognized.[41]

### *Diagnosis*

The diagnosis of PMR is largely clinical. The diagnosis of PMR should be suspected in individuals older than 50 years who present with pain and stiffness of the neck, shoulders or pelvic girdle areas, morning stiffness, and/or elevated inflammatory markers. The disease should be considered when symptom duration lasts more than 2 weeks. Prompt response to moderate doses of glucocorticoids (15–25 mg daily of prednisone or its equivalent) further supports the diagnosis. Common mimics to exclude include statin-induced myopathy, infections, malignancy, mechanical shoulder/hip pathology, inflammatory myopathies, fibromyalgia, hypothyroidism, GCA, and rheumatoid arthritis. In addition to a comprehensive physical examination, review of systems, and medication review, the authors recommend, the basic workup to include a complete blood count with differential, comprehensive metabolic panel, sedimentation rate, CRP, rheumatoid factor, anti-CCP, thyroid-stimulating hormone, serum/urine protein electrophoresis, creatine kinase, and infectious evaluation as appropriate. The association of PMR with distal extremity inflammatory arthritis has been described in the literature in up to 50% of the patients in some reports. Wrist synovitis, when present, can present with symptoms of carpal tunnel syndrome. The presence of significant distal inflammatory arthritis, especially with ankle and metatarsophalangeal joint involvement, should prompt consideration of an alternative diagnosis. In a similar fashion, in patients with PMR who are asymptomatic but have unexplained elevations in inflammatory markers, GCA should be considered.

### *Treatment of Polymyalgia Rheumatica*

#### *Glucocorticoids*

Glucocorticoids are the cornerstone of treatment of PMR. The treatment duration for PMR varies among patients, with a mean duration of around 20 months.[43] The recommended initial prednisone dose ranges between 12.5 and 25 mg/d. This dose could be tapered to 10 mg daily by 4 to 8 weeks if tolerated, then by 1 mg every 2 to 4 weeks thereafter. For relapses, the dose should be increased to the prerelapse dose then tapered more gradually.

#### *Steroid-sparing agents*

When compared with GCA, patients with PMR require smaller doses of glucocorticoids. The risk versus benefit of adding a steroid-sparing agent should be weighed against the risk of low-dose prednisone.

Descargado para Eilyn Mora Corrales (emorac17@gmail.com) en National Library of Health and Social Security de ClinicalKey.es por Elsevier en mayo 24, 2022. Para uso personal exclusivamente. No se permiten otros usos sin autorización. Copyright ©2022. Elsevier Inc. Todos los derechos reservados.

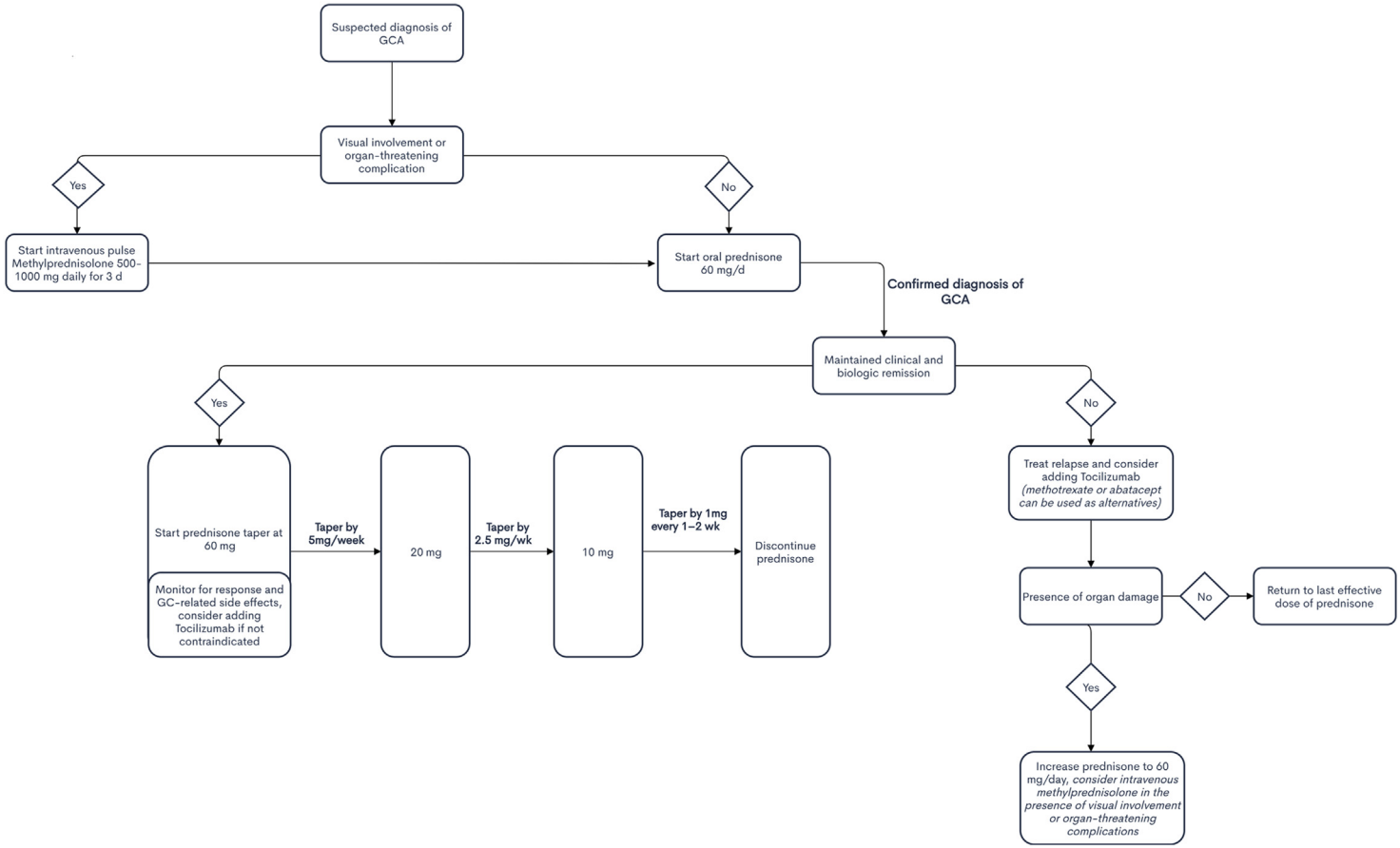


**Fig. 2.** GCA treatment algorithm.

Descargado para Eilyn Mora Corrales (emorac17@gmail.com) en National Library of Health and Social Security de ClinicalKey.es por Elsevier en mayo 24, 2022. Para uso personal exclusivamente. No se permiten otros usos sin autorización. Copyright ©2022. Elsevier Inc. Todos los derechos reservados.

Previous trials have shown mixed results with MTX treatment in PMR. All of them were small studies and used doses of MTX equal to or less than 10 mg/wk.[44–48] The first trial published in 1996 showed no steroid-sparing effect with the use of 7.5 mg weekly MTX.[46] Other trials showed a decrease in the cumulative dose of prednisone, duration of steroid treatment, and number of flare-ups in MTX groups.[45,47,48] There was no evidence that methotrexate decreased steroid-related side effects, although the studies were not powered adequately to detect that difference.[45,47] The authors recommend considering the use of methotrexate early on in patients at high risk of glucocorticoid-related side effect or in those with relapsing disease.

Limited data suggest that tocilizumab can be effective for isolated PMR[49] or in those with overlapping GCA.[30] TNF-inhibitors have not been found to be effective (**Fig. 2**).

## CLINICS CARE POINTS

- GCA and PMR are most common in individuals of northern European descent who are 50 years or older.
- At the time of confirmed diagnosis of GCA, screening for large vessel involvement should be completed with noninvasive imaging modalities. Follow-up imaging is recommended in cases of known large vessel complications, inability to taper glucocorticoids or persistently elevated inflammatory markers.
- The addition of tocilizumab to glucocorticoids has been demonstrated to be effective at preventing relapses and shortening the duration of glucocorticoid therapy in 2 large randomized controlled trials.
- The diagnosis of PMR is based on consistent clinical symptoms, including proximal muscle pain and stiffness in the hip and shoulder girdle regions, a rapid response to moderate-dose prednisone (15–25 mg daily) and exclusion of common mimics.
- Glucocorticoid monotherapy is the cornerstone of treatment in PMR, with doses greater than 25 mg daily of prednisone rarely needed.

## DISCLOSURE

The authors have nothing to disclose that is relevant to this article.

## REFERENCES

1. Gonzalez-Gay MA, Vazquez-Rodriguez TR, Lopez-Diaz MJ, et al. Epidemiology of giant cell arteritis and polymyalgia rheumatica. Arthritis Rheum 2009;61(10):1454–61.
2. de Boysson H, Liozon E, Ly KH, et al. The different clinical patterns of giant cell arteritis. Clin Exp Rheumatol 2019;37:57–60. Suppl 117 (2).
3. Hernandez-Rodriguez J, Murgia G, Villar I, et al. Description and Validation of Histological Patterns and Proposal of a Dynamic Model of Inflammatory Infiltration in Giant-cell Arteritis. Medicine (Baltimore) 2016;95(8):e2368.
4. Lie JT, Brown AL Jr, Carter ET. Spectrum of aging changes in temporal arteries. Its significance, in interpretation of biopsy of temporal artery. Arch Pathol 1970;90(3):278–85.
5. Bowling K, Rait J, Atkinson J, et al. Temporal artery biopsy in the diagnosis of giant cell arteritis: Does the end justify the means? Ann Med Surg (Lond) 2017;20:1–5.

Descargado para Eilyn Mora Corrales (emorac17@gmail.com) en National Library of Health and Social Security de ClinicalKey.es por Elsevier en mayo 24, 2022. Para uso personal exclusivamente. No se permiten otros usos sin autorización. Copyright ©2022. Elsevier Inc. Todos los derechos reservados.

6. Mahr A, Saba M, Kambouchner M, et al. Temporal artery biopsy for diagnosing giant cell arteritis: the longer, the better? Ann Rheum Dis 2006;65(6):826–8.
7. Durling B, Toren A, Patel V, et al. Incidence of discordant temporal artery biopsy in the diagnosis of giant cell arteritis. Can J Ophthalmol 2014;49(2):157–61.
8. Achkar AA, Lie JT, Hunder GG, et al. How does previous corticosteroid treatment affect the biopsy findings in giant cell (temporal) arteritis? Ann Intern Med 1994; 120(12):987–92.
9. Bley TA, Uhl M, Carew J, et al. Diagnostic value of high-resolution MR imaging in giant cell arteritis. AJNR Am J Neuroradiol 2007;28(9):1722–7.
10. Ghinoi A, Zuccoli G, Nicolini A, et al. 1T magnetic resonance imaging in the diagnosis of giant cell arteritis: comparison with ultrasonography and physical examination of temporal arteries. Clin Exp Rheumatol 2008;26(3 Suppl 49):S76–80.
11. Bley TA, Weiben O, Uhl M, et al. Assessment of the cranial involvement pattern of giant cell arteritis with 3T magnetic resonance imaging. Arthritis Rheum 2005; 52(8):2470–7.
12. Klink T, Geiger J, Both M, et al. Giant cell arteritis: diagnostic accuracy of MR imaging of superficial cranial arteries in initial diagnosis-results from a multicenter trial. Radiology 2014;273(3):844–52.
13. Luqmani R, Lee E, Singh S, et al. The Role of Ultrasound Compared to Biopsy of Temporal Arteries in the Diagnosis and Treatment of Giant Cell Arteritis (TABUL): a diagnostic accuracy and cost-effectiveness study. Health Technol Assess 2016;20(90):1–238.
14. Bley TA, Reinhard M, Hauenstein C, et al. Comparison of duplex sonography and high-resolution magnetic resonance imaging in the diagnosis of giant cell (temporal) arteritis. Arthritis Rheum 2008;58(8):2574–8.
15. Nuenninghoff DM, Hunder GG, Christianson TJ, et al. Mortality of large-artery complication (aortic aneurysm, aortic dissection, and/or large-artery stenosis) in patients with giant cell arteritis: a population-based study over 50 years. Arthritis Rheum 2003;48(12):3532–7.
16. Grayson PC, Tomasson G, Cuthbertson D, et al. Association of vascular physical examination findings and arteriographic lesions in large vessel vasculitis. J Rheumatol 2012;39(2):303–9.
17. de Boysson H, Aouba A. [The additional value of imaging (excluding Doppler) for the diagnosis and follow-up of giant cell arteritis]. Presse Med 2019;48(9): 931–40.
18. Loffler C, Hoffend J, Benck U, et al. The value of ultrasound in diagnosing extracranial large-vessel vasculitis compared to FDG-PET/CT: A retrospective study. Clin Rheumatol 2017;36(9):2079–86.
19. Hauenstein C, Reinhard M, Geiger J, et al. Effects of early corticosteroid treatment on magnetic resonance imaging and ultrasonography findings in giant cell arteritis. Rheumatology (Oxford) 2012;51(11):1999–2003.
20. Kermani TA, Schmidt J, Crowson CS, et al. Utility of erythrocyte sedimentation rate and C-reactive protein for the diagnosis of giant cell arteritis. Semin Arthritis Rheum 2012;41(6):866–71.
21. Mazlumzadeh M, Hunder GG, Easley KA, et al. Treatment of giant cell arteritis using induction therapy with high-dose glucocorticoids: a double-blind, placebo-controlled, randomized prospective clinical trial. Arthritis Rheum 2006;54(10): 3310–8.
22. Chevalet P, Barrier JH, Pottier P, et al. A randomized, multicenter, controlled trial using intravenous pulses of methylprednisolone in the initial treatment of simple

Descargado para Eilyn Mora Corrales (emorac17@gmail.com) en National Library of Health and Social Security de ClinicalKey.es por Elsevier en mayo 24, 2022. Para uso personal exclusivamente. No se permiten otros usos sin autorización. Copyright ©2022. Elsevier Inc. Todos los derechos reservados.

forms of giant cell arteritis: a one year followup study of 164 patients. J Rheumatol 2000;27(6):1484–91.
23. Hellmich B, Agueda A, Monti S, et al. 2018 Update of the EULAR recommendations for the management of large vessel vasculitis. Ann Rheum Dis 2020;79(1):19–30.
24. Mackie SL, Dejaco C, Appenzeller S, et al. British Society for Rheumatology guideline on diagnosis and treatment of giant cell arteritis. Rheumatology (Oxford) 2020;59(3):e1–23.
25. Behn AR, Perera T, Myles AB. Polymyalgia rheumatica and corticosteroids: how much for how long? Ann Rheum Dis 1983;42(4):374–8.
26. Hachulla E, Boivin V, Pasturel-Michon U, et al. Prognostic factors and long-term evolution in a cohort of 133 patients with giant cell arteritis. Clin Exp Rheumatol 2001;19(2):171–6.
27. Hunder GG, Sheps SG, Allen GL, et al. Daily and alternate-day corticosteroid regimens in treatment of giant cell arteritis: comparison in a prospective study. Ann Intern Med 1975;82(5):613–8.
28. Villiger PM, Adler S, Kuchen S, et al. Tocilizumab for induction and maintenance of remission in giant cell arteritis: a phase 2, randomised, double-blind, placebo-controlled trial. Lancet 2016;387(10031):1921–7.
29. Xie F, Yun H, Bernatsky S, et al. Brief Report: Risk of Gastrointestinal Perforation Among Rheumatoid Arthritis Patients Receiving Tofacitinib, Tocilizumab, or Other Biologic Treatments. Arthritis Rheumatol 2016;68(11):2612–7.
30. Stone JH, Tuckwell K, Dimonaco S, et al. Trial of Tocilizumab in Giant-Cell Arteritis. N Engl J Med 2017;377(4):317–28.
31. Unizony S, Arias-Urdaneta L, Miloslavsky E, et al. Tocilizumab for the treatment of large-vessel vasculitis (giant cell arteritis, Takayasu arteritis) and polymyalgia rheumatica. Arthritis Care Res (Hoboken) 2012;64(11):1720–9.
32. Stone JH, Bao M, Han J, et al. Long-Term Outcome of Tocilizumab for Patients with Giant Cell Arteritis: Results from Part 2 of the Giacta Trial. Ann Rheum Dis 2019;78:145–6.
33. Nishimoto N, Miyasaka N, Yamamoto K, et al. Long-term safety and efficacy of tocilizumab, an anti-IL-6 receptor monoclonal antibody, in monotherapy, in patients with rheumatoid arthritis (the STREAM study): evidence of safety and efficacy in a 5-year extension study. Ann Rheum Dis 2009;68(10):1580–4.
34. Spiera RF, Mitnick HJ, Kupersmith M, et al. A prospective, double-blind, randomized, placebo controlled trial of methotrexate in the treatment of giant cell arteritis (GCA). Clin Exp Rheumatol 2001;19(5):495–501.
35. Jover JA, Hernandez-Garcia C, Morado IC, et al. Combined treatment of giant-cell arteritis with methotrexate and prednisone. a randomized, double-blind, placebo-controlled trial. Ann Intern Med 2001;134(2):106–14.
36. Hoffman GS, Cid MC, Hellmann DB, et al. A multicenter, randomized, double-blind, placebo-controlled trial of adjuvant methotrexate treatment for giant cell arteritis. Arthritis Rheum 2002;46(5):1309–18.
37. Mahr AD, Jover JA, Spiera RF, et al. Adjunctive methotrexate for treatment of giant cell arteritis: an individual patient data meta-analysis. Arthritis Rheum 2007;56(8):2789–97.
38. Salvarani C, Della Bella C, Cimino L, et al. Risk factors for severe cranial ischaemic events in an Italian population-based cohort of patients with giant cell arteritis. Rheumatology (Oxford) 2009;48(3):250–3.
39. Nesher G, Berkun Y, Mates M, et al. Low-dose aspirin and prevention of cranial ischemic complications in giant cell arteritis. Arthritis Rheum 2004;50(4):1332–7.

Descargado para Eilyn Mora Corrales (emorac17@gmail.com) en National Library of Health and Social Security de ClinicalKey.es por Elsevier en mayo 24, 2022. Para uso personal exclusivamente. No se permiten otros usos sin autorización. Copyright ©2022. Elsevier Inc. Todos los derechos reservados.

40. Narvaez J, Bernad B, Nolla JM, et al. Statin therapy does not seem to benefit giant cell arteritis. Semin Arthritis Rheum 2007;36(5):322–7.
41. Salvarani C, Cantini F, Hunder GG. Polymyalgia rheumatica and giant-cell arteritis. Lancet 2008;372(9634):234–45.
42. Raheel S, Shbeeb I, Crowson CS, et al. Epidemiology of Polymyalgia Rheumatica 2000-2014 and Examination of Incidence and Survival Trends Over 45 Years: A Population-Based Study. Arthritis Care Res (Hoboken) 2017;69(8):1282–5.
43. Chuang TY, Hunder GG, Ilstrup DM, et al. Polymyalgia rheumatica: a 10-year epidemiologic and clinical study. Ann Intern Med 1982;97(5):672–80.
44. van der Veen MJ, Dinant HJ, van Booma-Frankfort C, et al. Can methotrexate be used as a steroid sparing agent in the treatment of polymyalgia rheumatica and giant cell arteritis? Ann Rheum Dis 1996;55(4):218–23.
45. Ferraccioli G, Salaffi F, De Vita S, et al. Methotrexate in polymyalgia rheumatica: preliminary results of an open, randomized study. J Rheumatol 1996;23(4):624–8.
46. Feinberg HL, Sherman JD, Schrepferman CG, et al. The use of methotrexate in polymyalgia rheumatica. J Rheumatol 1996;23(9):1550–2.
47. Cimmino MA, Salvarani C, Macchioni P, et al. Long-term follow-up of polymyalgia rheumatica patients treated with methotrexate and steroids. Clin Exp Rheumatol 2008;26(3):395–400.
48. Caporali R, Cimmino MA, Ferraccioli G, et al. Prednisone plus methotrexate for polymyalgia rheumatica: a randomized, double-blind, placebo-controlled trial. Ann Intern Med 2004;141(7):493–500.
49. Macchioni P, Boiardi L, Catanoso M, et al. Tocilizumab for polymyalgia rheumatica: report of two cases and review of the literature. Semin Arthritis Rheum 2013;43(1):113–8.

Descargado para Eilyn Mora Corrales (emorac17@gmail.com) en National Library of Health and Social Security de ClinicalKey.es por Elsevier en mayo 24, 2022. Para uso personal exclusivamente. No se permiten otros usos sin autorización. Copyright ©2022. Elsevier Inc. Todos los derechos reservados.