Oral Potentially Malignant Disorders

Current Knowledge and Future Directions

Omar Kujan, FFOMP (RCPA), FRCPath, MFDS RCPS (Glasg), BDS, MDSc, PhD

KEYWORDS

• Oral potentially malignant disorders • OPMDs • Oral cancer
• Malignant transformation • Diagnostic adjuncts • Management

KEY POINTS

- Oral potentially malignant disorders (OPMDs) present diverse clinical lesions and conditions with a potential risk of malignant transformation.
- Biopsy remains the gold standard for differentiating these lesions and grading epithelial dysplasia, a predictor of malignant transformation.
- It is essential for general dentists and specialists to maintain current knowledge for effective early detection and monitoring.
- With appropriate training, adjunctive tools and AI may aid OPMD diagnosis and biopsy site selection but should complement, not replace, clinical judgment and histopathological assessment.

INTRODUCTION

Oral potentially malignant disorders (OPMDs) are clinical lesions and conditions that have the potential to progress to oral squamous cell carcinoma (OSCC).[1] The understanding of OPMDs has significantly advanced over the years, improving knowledge about their nature, risk factors, and mechanisms of malignant transformation (MT). Early detection and management of these disorders are essential to reduce the prevalence of oral cancer, which continues to be a major contributor to morbidity and mortality worldwide.[2]

This review provides a detailed overview of OPMDs, covering the evolution of terminology, etiology, risk factors, lesion types, risk of MT, effectiveness of diagnostic adjuncts, and current management strategies. Through an in-depth discussion, this review aims to equip general dentists and specialists with the essential knowledge

Oral Pathology Discipline, UWA Dental School, The University of Western Australia, 17 Monash Avenue, Nedlands, Western Australia 6009, Australia
E-mail address: omar.kujan@uwa.edu.au

Dent Clin N Am 69 (2025) 327–346
https://doi.org/10.1016/j.cden.2025.03.001 **dental.theclinics.com**
0011-8532/25/© 2025 Elsevier Inc. All rights are reserved, including those for text and data mining, AI training, and similar technologies.

Descargado para Lucia Angulo (lu.maru26@gmail.com) en National Library of Health and Social Security de ClinicalKey.es por Elsevier en julio 10, 2025. Para uso personal exclusivamente. No se permiten otros usos sin autorización. Copyright ©2025. Elsevier Inc. Todos los derechos reservados.

Abbreviations	
AC	actinic keratosis
AI	artificial intelligence
CI	confidence interval
COE	conventional oral examination
MT	malignant transformation
NBI	narrow band imaging
OL	oral leukoplakia
OLLs	oral lichenoid lesions
OLP	oral lichen planus
OPMDs	oral potentially malignant disorders
OSCC	oral squamous cell carcinoma
OSF	oral submucous fibrosis
PVL	proliferative verrucous leukoplakia
VC	verrucous carcinoma
WHO	World Health Organization

for the early detection and effective management of these potentially high-risk disorders.

DEFINITION AND TERMINOLOGY EVOLUTION

The terminology for OPMDs has evolved over the years. Initially, terms such as "precancer," "premalignant," "precancerous lesions," or "precancerous conditions" were commonly used to describe these oral mucosal changes. However, these terms were found to be restrictive and misleading, as not all lesions inevitably progress to cancer, and some conditions affecting oral tissues contribute to carcinogenesis without presenting as specific lesions.[3] Hence, the term "oral potentially malignant disorders" was introduced to encompass a broad range of lesions and conditions that carry an increased risk of transformation into OSCC.[1,3] This terminology was adopted to provide a more accurate representation of the risk without implying an inevitable progression to malignancy. Importantly, the term "potentially premalignant oral epithelial lesions" has been proposed,[4] but it is not preferred due to its limited scope and the implication that all such lesions are premalignant, which does not align with the current understanding of the pathobiology of these disorders.[3,5] It is critical to note that the term "potentially malignant" better reflects the inherent risk associated with these lesions and conditions, acknowledging that MT is a possibility rather than a certainty. This shift in terminology helps set realistic expectations for both patients and practitioners, thereby guiding appropriate management strategies and surveillance. Nonetheless, future studies on the natural history of OPMDs may support a revised classification system that categorizes OPMDs based on their varying levels of malignant potential.[6] High-risk lesions, such as erythroplakia, nonhomogeneous leukoplakia, proliferative verrucous leukoplakia, and actinic keratosis, should be distinguished from those with lower or undefined risks, such as homogeneous leukoplakia, oral submucous fibrosis (OSF), and oral lichen planus (OLP).[6]

CLINICAL EPIDEMIOLOGY, ETIOLOGY, AND RISK FACTORS

As defined by the World Health Organization (WHO) collaborating center for oral cancer, OPMDs include a list of lesions and conditions presented in **Box 1**. It exhibits considerable global variations in prevalence and types, heavily influenced by cultural, lifestyle, and environmental factors. The global prevalence of OPMDs is 4.47%, ranging from 1% to 5%, with higher rates in regions where risk factors such as

Descargado para Lucia Angulo (lu.maru26@gmail.com) en National Library of Health and Social Security de ClinicalKey.es por Elsevier en julio 10, 2025. Para uso personal exclusivamente. No se permiten otros usos sin autorización. Copyright ©2025. Elsevier Inc. Todos los derechos reservados.

Box 1
Clinical entities of oral potentially malignant disorders[3,17]

Proliferative verrucous leukoplakia

Leukoplakia

Erythroleukoplakia

Erythroplakia

OSF

Palatal lesions associated with reverse smoking

Oral lichenoid lesions (OLLs)

OLP

Actinic keratosis (actinic cheilitis)

Oral graft-versus-host disease

Oral lupus erythematosus

Familial cancer syndromes including Fanconi anemia, dyskeratosis congenita, xeroderma pigmentosum, Li–Fraumeni syndrome, Bloom syndrome, ataxia–telangiectasia, and Cowden syndrome

tobacco, alcohol, and areca nut use are prevalent.[7] Male individuals were more frequently affected by these disorders. South and Southeast Asia report the highest prevalence, particularly due to areca nut chewing, tobacco, and betel quid consumption.[7] For example, OSF is notably common in countries like India and Pakistan, where areca nut is culturally ingrained.[8] In contrast, oral leukoplakia (OL) is more frequently observed in populations with high tobacco and alcohol use, with global prevalence estimates ranging from 1% to 4%.[7,9] In Western countries, leukoplakia and OLP are the most frequently encountered OPMDs. OLP affects approximately 0.5% to 2.2% of the population, particularly middle-aged and elderly women.[7]

The etiology of OPMDs is multifactorial, with key risk factors including tobacco use, alcohol consumption, and areca nut chewing.[2,8,10] Tobacco and alcohol are particularly significant, often acting synergistically to increase the risk of MT. Heavy tobacco use (eg, smoking over 20 cigarettes per day) can increase the risk of developing leukoplakia by 5 to 10 times compared to nonsmokers.[11] Additionally, alcohol consumption exceeding 30 g per day significantly raises the risk of MT in existing OPMDs.[11] The combination of smoking and alcohol use has an additive effect, leading to a markedly higher risk of developing OPMDs and progression to OSCC compared to using either substance alone.[11] Areca nut, commonly used in parts of Asia, is another major risk factor, particularly for OSF.[10,12] The fibrogenic and carcinogenic properties of areca nut significantly increase the risk of OSF and subsequent MT.[10] In a small subset of OPMDs, human papillomavirus, especially type 16, has been implicated in the pathogenesis of OPMDs, although its role is less definitive compared to its established connection with oropharyngeal cancers.[13] A recent study has shown a significant association between floor-of-mouth tumors and a history of smoking and alcohol use, with a 26 fold increase in odds compared to other oral sites. In contrast, tumors in the gingiva and buccal mucosa were much less likely to be associated with these traditional risk factors, suggesting a differing etiologic profile for OSCC in these areas.[14]

The etiopathogenesis of OPMDs involves a complex interplay of genetic, environmental, and lifestyle factors. Chronic exposure to carcinogens can lead to genetic

Descargado para Lucia Angulo (lu.maru26@gmail.com) en National Library of Health and Social Security de ClinicalKey.es por Elsevier en julio 10, 2025. Para uso personal exclusivamente. No se permiten otros usos sin autorización. Copyright ©2025. Elsevier Inc. Todos los derechos reservados.

mutations, alterations in cell signaling pathways, and disruption of normal cell cycles. Tobacco and alcohol metabolites can damage DNA, impair repair mechanisms, and cause epigenetic changes that promote dysplasia and carcinogenesis. Chronic inflammation also plays a role in facilitating MT, with inflammatory mediators contributing to an environment conducive to cancer development.[15,16]

Other risk factors include genetic susceptibility, poor oral hygiene, and nutritional deficiencies, particularly of vitamins A, C, and E, which are crucial for maintaining mucosal integrity and protecting against oxidative stress. Individuals with inadequate dietary intake of these vitamins, especially when combined with tobacco and alcohol use, are at increased risk of developing OPMDs.[16] Public health efforts should focus on reducing exposure to known risk factors, promoting early detection, and implementing targeted interventions in high-risk populations to mitigate the burden of OPMDs.[2]

TYPES OF LESIONS AND CONDITIONS AND THEIR CLINICAL PRESENTATION

Leukoplakia is the most common OPMD. It presents as a white patch that cannot be scraped off or attributed to any other diagnosable condition.[18,19] OL is a clinical diagnosis by exclusion and is classified into different types based on its clinical presentation, including homogeneous and nonhomogeneous OL (**Fig. 1**A–D).[3] The global prevalence of OL is 4.11% (95% confidence interval [CI]: 1.98%–6.97%).[7] Histopathological examination of OL often reveals hyperkeratosis, characterized by thickened keratin layers, with or without the presence of (oral epithelial dysplasia [OED]; see **Fig. 1**A–D).[20] Men are generally more affected than women, primarily due to higher rates of tobacco and alcohol use. Leukoplakia is most commonly diagnosed in individuals aged over 40 years, with the risk of MT increasing with age, lesion size, and the presence and grade of dysplasia.[5,21] A pooled meta-analysis reported a cumulative

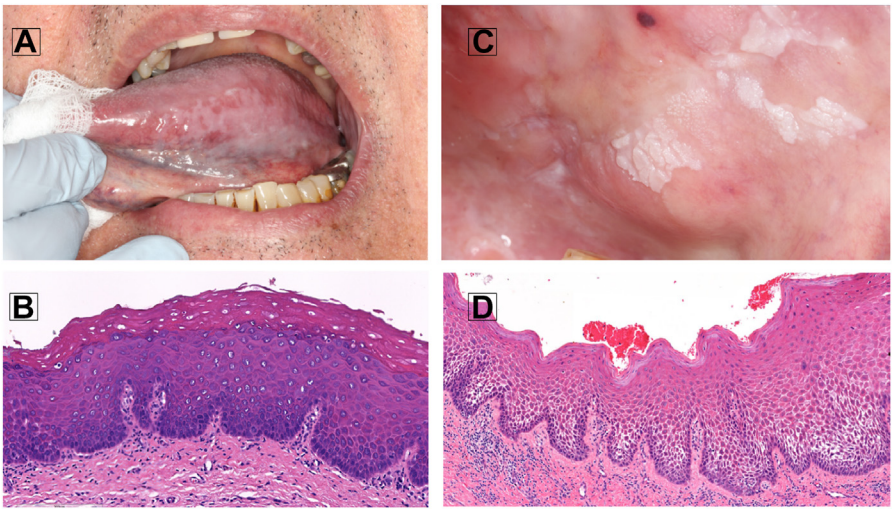

Fig. 1. Oral leukoplakia. (*A*) Homogenous flat leukoplakia on the left lateral tongue in a 65 year old male patient with a proven biopsy (*B*) showing hyperkeratosis with mild dysplasia (low-grade epithelial dysplasia). (*C*) Nonhomogenous nodular leukoplakia on the left buccal mucosa, × 120; (*D*) biopsy showed hyperkeratosis with moderate dysplasia, × 120 (high-grade epithelial dysplasia).

Descargado para Lucia Angulo (lu.maru26@gmail.com) en National Library of Health and Social Security de ClinicalKey.es por Elsevier en julio 10, 2025. Para uso personal exclusivamente. No se permiten otros usos sin autorización. Copyright ©2025. Elsevier Inc. Todos los derechos reservados.

MT rate of 8.6% (95% CI: 5.1%–13.0%) and an annual MT rate of 1.56%.[5,22] Homogeneous OL has a relatively lower MT rate of about 1% to 3%, while nonhomogeneous types, such as speckled and nodular leukoplakia, carry a higher risk, estimated at 10% to 30%.[22]

Homogeneous Leukoplakia

This type appears as a uniformly white, flat, or slightly elevated lesion with a consistent texture. It is the most common type of leukoplakia and generally carries a lower risk of MT compared to nonhomogeneous leukoplakia.[3] The prevalence of homogeneous leukoplakia is estimated to be around 1% to 2% in the general population, with a higher incidence in individuals who smoke.[5,12]

Nonhomogeneous Leukoplakia

Nonhomogeneous leukoplakia includes speckled, nodular, and verrucous types and is characterized by mixed white and red areas, surface irregularities, or exophytic growth. It has a significantly higher risk of MT, with transformation rates reported to be between 15% and 30%, depending on various factors such as lesion size, location, and the presence and grade of OED.[5,23] This type is more prevalent among smokers and individuals with a history of alcohol consumption, as these risk factors are known to increase the likelihood of malignant changes.[5] Clinicians should remain vigilant regarding the MT potential of OL, even when OED is absent. A North American study revealed that 39.6% of cancers originated from biopsied leukoplakias that displayed no dysplastic features.[5]

In evaluating OL, Villa and Woo[24] proposed the following points to carefully differentiate it from other lesions across various categories:

- *Developmental*: Consider congenital conditions such as Cannon's white sponge nevus, hereditary benign intraepithelial dyskeratosis, and other genodermatoses like pachyonychia congenita.
- *Reactive or frictional*: Conditions like leukoedema, contact desquamation, and frictional keratosis (eg, morsicatio mucosae oris, BARK) may present similarly. Tobacco-related lesions, including nicotinic stomatitis and smokeless tobacco keratosis, are also common considerations, as is hairy tongue.
- *Infectious*: Common infections mimicking leukoplakia include candidiasis and Epstein-Barr virus-associated hairy leukoplakia.
- *Immune-mediated*: Conditions such as lichen planus, lichenoid lesions, and benign migratory glossitis should be excluded in the differential.
- *Autoimmune*: Autoimmune diseases like lupus erythematosus and chronic graft-versus-host disease can present with oral manifestations that may mimic leukoplakia.
- *Metabolic*: Metabolic causes such as uremic stomatitis or drug-related hyperkeratosis (eg, palifermin-induced) may also resemble leukoplakia.
- *Malignant and OPMD*: Finally, consider potentially malignant disorders and malignancies, including dysplastic leukoplakia, OSCC or verrucous carcinoma (VC), and keratosis of unknown significance.

Accurate diagnosis requires thorough clinical assessment and, where necessary, histopathological examination to guide appropriate management and rule out these diverse conditions.

Proliferative verrucous leukoplakia (PVL) was first identified by Hansen and colleagues in 1985 as a unique subtype of OL. It quickly garnered significant attention due to its aggressive nature and high MT rate, with approximately 50% of cases

Descargado para Lucia Angulo (lu.maru26@gmail.com) en National Library of Health and Social Security de ClinicalKey.es por Elsevier en julio 10, 2025. Para uso personal exclusivamente. No se permiten otros usos sin autorización. Copyright ©2025. Elsevier Inc. Todos los derechos reservados.

progressing to OSCC and VC.[3] This disorder is notable for its multifocal presentation and persistent progression, often resisting conventional treatment and demonstrating a high recurrence rate. Consequently, PVL has become a focus of concern and study within oral pathology and medicine due to its challenging diagnosis and serious management; hence, several proposals for diagnosing and classification were made.[25,26] PVL predominantly affects older adults, especially women, and is generally unassociated with traditional risk factors like tobacco and alcohol use.[3,5,16] PVL follows a multifocal, recurrent progression (**Fig. 2**A–D), frequently affecting areas like the gingiva (39.6%) and buccal mucosa (21.6%).[27] Early lesions in patients with PVL often resemble OLP or homogeneous OL, presenting as smooth or fissured/verrucous white or mixed red-and-white patches, typically without ulceration.[28] Characteristic features include multiple nonadjacent lesions, a single lesion over 40 mm at one site, or a single lesion over 30 mm spreading across connected sites. A distinct sign of PVL is the presence of thick, verrucous leukoplakias along the marginal gingiva, especially when encircling teeth or appearing at multiple locations.[28] The pooled MT rate of PVL is 43.9% (95% CI = 31.93–56.13). PVL is notably more prevalent in female individuals (64.02%, 95% CI: 54.9%–72.7%) than male individuals (35.98%, 95% CI: 27.3%–45.1%).[27] Diagnosis is retrospective, relying on a detailed clinical history and histopathological analysis of representative, noninflamed mucosal sites. Sampling should ideally be from junctions with healthy tissue, avoiding ulcerated or inflamed areas to enhance diagnostic accuracy.

Erythroplakia presents as a red, velvety patch and is considered to have a significantly higher risk of MT than leukoplakia. However, the prevalence of erythroplakia is much lower than that of leukoplakia, with estimates of 0.17% (95% CI: 0.07%–0.32%).[7] Despite its low prevalence, erythroplakia is of particular concern due to its high MT

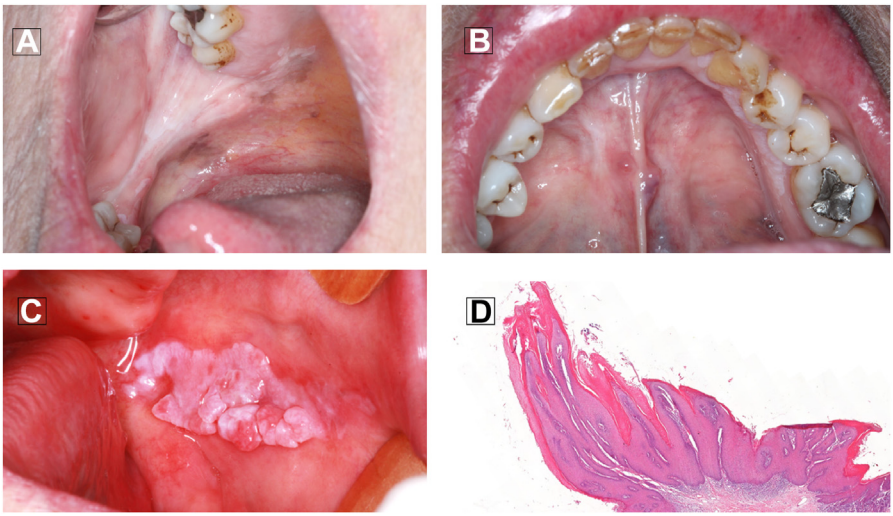

Fig. 2. Proliferative verrucous leukoplakia in a 47 year old ex-smoker (30 pack-year) nondrinker female patient. (*A*) Irregular corrugated white patch extending on the right retromolar pad to the palatal mucosa opposite #17 and #18 (biopsy showed mild dysplasia). (*B*) Irregular verrucous white patch on the lingual mucosa opposite #43 to #46 (Biopsy showed moderate dysplasia). (*C*) Irregular verrucous speckled leukoplakia on the left buccal mucosa. (*D*) Biopsy showed bulky hyperkeratotic epithelial proliferation with severe dysplasia (× 60). This lesion transformed into verrucous carcinoma after 15 months.

Descargado para Lucia Angulo (lu.maru26@gmail.com) en National Library of Health and Social Security de ClinicalKey.es por Elsevier en julio 10, 2025. Para uso personal exclusivamente. No se permiten otros usos sin autorización. Copyright ©2025. Elsevier Inc. Todos los derechos reservados.

rate, which can be as high as 33.1% (95% CI: 13.6%–56.1%), depending on various factors such as lesion size, location, and patient demographics.[5,22] Erythroplakia is most commonly found in older adults, typically over 50 years, with a slightly higher incidence in male individuals. The condition is frequently associated with risk factors such as tobacco and alcohol use, which are known to contribute to its development and progression. Clinically, erythroplakia presents as a well-demarcated, bright red lesion, often with a soft or velvety texture (**Fig. 3**A, B). It is commonly located on high-risk sites such as the floor of the mouth, the ventral tongue, and the soft palate.[29,30]

Histologically, erythroplakia often shows severe dysplasia, carcinoma in situ, or even invasive carcinoma at the time of diagnosis, which underscores the need for prompt biopsy and definitive management.[5,20] The high MT risk necessitates careful monitoring and early intervention, making erythroplakia one of the most clinically significant OPMDs. Due to its high-risk nature, any lesion suspected to be erythroplakia should be biopsied to determine the appropriate course of treatment.[16,31]

OLP is a chronic inflammatory disorder of the oral mucosa characterized by immune-mediated pathology,[32–34] and has been extensively studied because of the controversy of its potential MT.[33] OLP is typically diagnosed based on clinical and histopathological correlation, where the diagnostic criteria evolved over the years (**Table 1**).[3,35,36] The classic presentation includes bilateral white striations (Wickham's striae) on the buccal mucosa and lateral tongue (**Fig. 4**A–F). A biopsy is recommended to confirm the diagnosis and rule out dysplasia or malignancy.[35,37] The presence of a lace-like network of keratotic striae is a key diagnostic feature, while direct immunofluorescence may help differentiate OLP from other vesiculobullous diseases when required.[19] OLP can be classified into several clinical subtypes, including reticular, papular, plaque, atrophic, erosive, and bullous forms.[32,33] The reticular type is the most frequently encountered, presenting as interlaced, raised white lines forming lattice patterns. Plaque-type OLP resembles leukoplakia but has characteristic keratotic striae at the periphery. Atrophic, erosive, and ulcerative subtypes may present with erythematous areas and ulceration, often leading to symptoms like soreness or a burning sensation, especially when eating spicy foods. The bullous form is rare and tends to recur, requiring differentiation from pemphigus or mucus membrane pemphigoid.[18] OLP has an estimated global prevalence of 1.01% (95% CI: 0.74%–1.32%). Prevalence is lowest in North America (0.47% [95% CI: 0.13–1.02]) and Asia (0.83% [95% CI: 0.59–1.12]), while higher rates are observed in South-Central America (1.74% [95% CI: 0.13–5.09]), Africa (1.43% [95% CI: 1.12–1.82]), and Europe (1.32% [95% CI: 0.74–2.05]).[38] This variation may reflect geographic, genetic, or

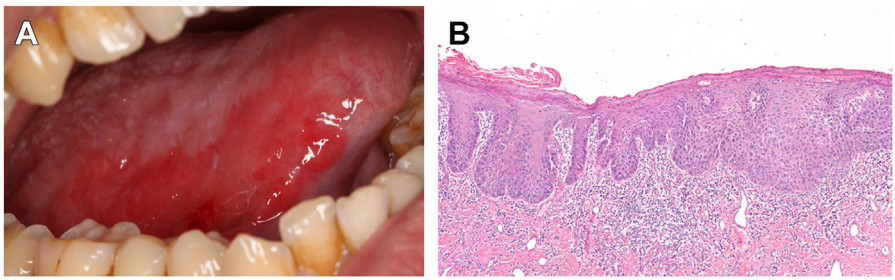

Fig. 3. (*A*) Irregular extensive velvety erythroplakia of the right lateral surface of the tongue in a 39 year old male patient. (*B*) The biopsy showed severe dysplasia (high-grade epithelial dysplasia, × 120). ([*A*] *Courtesy* Associate Professor Agnieszka Frydrych, The University of Western Australia.)

Descargado para Lucia Angulo (lu.maru26@gmail.com) en National Library of Health and Social Security de ClinicalKey.es por Elsevier en julio 10, 2025. Para uso personal exclusivamente. No se permiten otros usos sin autorización. Copyright ©2025. Elsevier Inc. Todos los derechos reservados.

Table 1
Diagnostic criteria for oral lichen planus

Clinical criteria	• Presence of bilateral, more or less symmetric white lesions affecting buccal mucosa, and/or tongue, and/or lip, and/or gingiva • Presence of a white papular lesion and lace-like network of slightly raised white lines (reticular, annular, or linear pattern) with or without erosions and ulcerations • Sometimes presents as desquamative gingivitis
Histopathological criteria	• Presence of a well-defined band-like predominantly lymphocytic infiltrate that is confined to the superficial part of the connective tissue • Signs of vacuolar degeneration of the basal and/or supra basal cell layers with keratinocyte apoptosis • In the atrophic type, there is epithelial thinning and sometimes ulceration caused by failure of epithelial regeneration as a result of basal cell destruction. A mixed inflammatory infiltrate may be found

Adapted from Warnakulasuriya et al. 2021.[3]

environmental factors and differences in diagnostic practices and health care access across regions.[38]

The diagnosis of OLP is clinically significant because it requires ongoing surveillance due to the risk of MT.[33] Although the overall risk of OLP progressing to OSCC is relatively low (between 0.5% and 2%),[22,39,40] the erosive and atrophic subtypes are associated with a higher risk of MT.[39] Patients with OLP, particularly those with symptomatic lesions, need regular follow-up to monitor for changes indicative of dysplasia or carcinoma. OLP can also impact patients' quality of life, particularly when the lesions are painful or interfere with eating and speaking.[3]

The differential diagnosis of OLP includes lichenoid reactions, lichen sclerosis, discoid lupus erythematosus, chronic ulcerative stomatitis, and OL.[3,21,36] Biopsy and histopathological examination are crucial to differentiate OLP from these other conditions and assess the presence of epithelial dysplasia.[37,39]

OLLs are inflammatory conditions that resemble OLP both clinically and histopathologically but have a known or suspected external trigger, such as dental materials, drugs, systemic diseases, or idiopathic.[3] OLLs are distinguished from OLP based on their etiology and the presence of an identifiable causal agent.[36] The diagnosis of OLLs involves a thorough clinical examination and assessment of potential etiologic factors, including medications and dental restorations. Unlike OLP, OLLs may show a more unilateral or asymmetrical distribution and are often found adjacent to suspected causative agents, such as amalgam restorations.[3,32] A biopsy with histopathological examination is necessary to confirm the diagnosis and differentiate OLLs from OLP (see **Fig. 4**A–F). Histopathologically, OLLs show similar features to OLP, such as a band-like inflammatory infiltrate and basal cell degeneration, but they may have more pronounced perivascular inflammation.[41] Clinically, OLLs can present in various forms, including reticular, atrophic, and erosive subtypes (see **Fig. 4**A–F). The reticular subtype is characterized by interlacing white striae, similar to OLP, while the erosive subtype presents with erythematous areas and ulceration. The atrophic and plaque-like subtypes are less common and may resemble other conditions like leukoplakia or chronic hyperplastic candidiasis.[21,42] OLLs' clinical significance lies in their potential for chronicity and discomfort, as well as their MT risk.[36] The risk of MT in OLLs is higher than that reported for OLP. The pooled MT rate for OLL is estimated at 3.8% (95% CI: 1.6%–7.0%), with an

Descargado para Lucia Angulo (lu.maru26@gmail.com) en National Library of Health and Social Security de ClinicalKey.es por Elsevier en julio 10, 2025. Para uso personal exclusivamente. No se permiten otros usos sin autorización. Copyright ©2025. Elsevier Inc. Todos los derechos reservados.

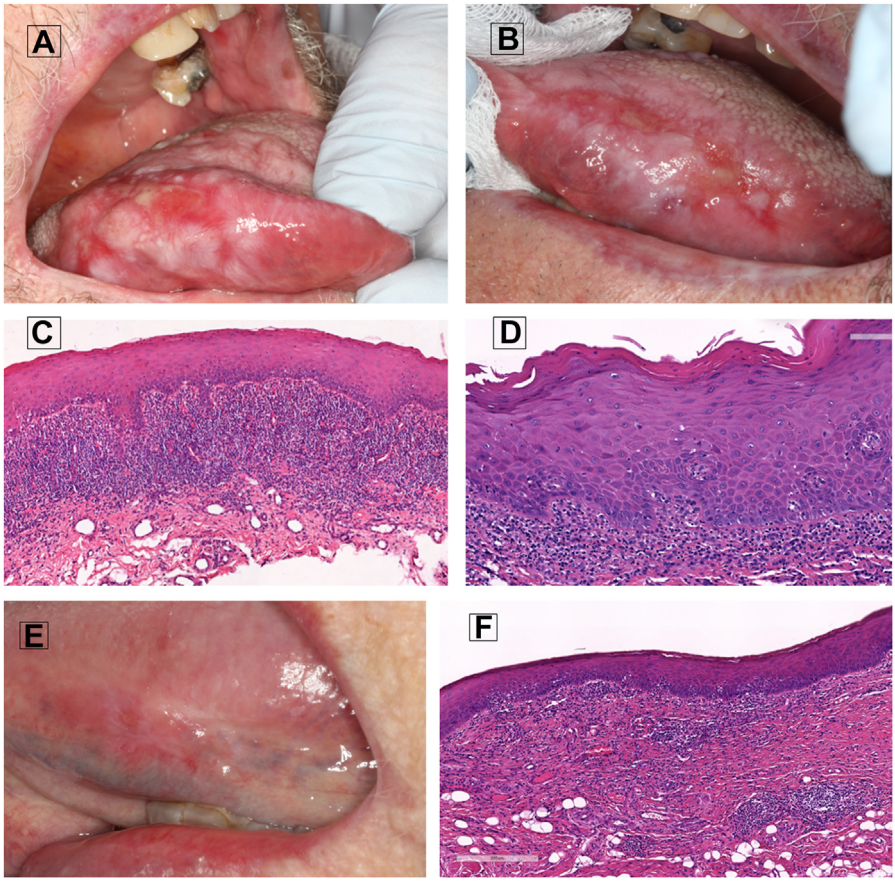

Fig. 4. Oral lichen planus, ulcerative type in an 84 year old male patient, bilateral and symmetric involvement. (*A*) Right lateral tongue, (*B*) left lateral tongue, (*C*) biopsy showing typical band-like lymphocytic infiltrate in association with basal cell degeneration (× 40), and (*D*) biopsy showing lack of epithelial dysplasia, apoptotic bodies, and thickened basement membrane (× 120). (*E*) Drug-related oral lichenoid reaction in a 75 year old ex-smoker (50 pack-years) with hypertension and asthma in response to hydrochlorothiazide and propranolol on the left latero-ventral tongue and (*F*) biopsy confirmed oral lichenoid mucositis with a diffuse lymphoplasmacytic infiltrate (× 120).

annual transformation rate of approximately 0.57%.[22] These figures underscore the importance of vigilant monitoring for OLL patients. Though the risk is relatively low annually, it accumulates over time, highlighting the need for regular follow-up and early intervention in cases of atypical progression, particularly in cases with persistent or erosive lesions.

OSF is a chronic, progressive, scarring disease of the oral mucosa that leads to restricted mouth opening and has a high potential for MT.[43,44] It is strongly associated with chewing areca nuts, often mixed with tobacco, which is a common cultural practice in South and Southeast Asia, particularly in countries such as India, Pakistan, Sri Lanka, and Taiwan.[12,43] The global prevalence of OSF is estimated at 4.96% (95% CI: 2.28%–8.62%).[7] OSF primarily affects young adults, often between the ages of 20 and 40 years, with a higher incidence reported in male individuals due to their higher usage

Descargado para Lucia Angulo (lu.maru26@gmail.com) en National Library of Health and Social Security de ClinicalKey.es por Elsevier en julio 10, 2025. Para uso personal exclusivamente. No se permiten otros usos sin autorización. Copyright ©2025. Elsevier Inc. Todos los derechos reservados.

rates of areca nut and related products.[43] Clinically, OSF is characterized by progressive fibrosis of the oral mucosa, leading to symptoms such as a burning sensation, blanching, and rigidity of the oral tissues, resulting in reduced mouth opening (trismus).[45] The affected mucosa may appear pale and stiff, and palpable fibrous bands are often present, particularly in the buccal mucosa, soft palate, and lips (**Fig. 5**A–C).[45] As the condition progresses, it may severely impair mouth opening, limiting function and quality of life.[44,45] Microscopically, in OSF biopsy, the epithelium initially exhibits hyperplasia, eventually progressing to atrophy and loss of rete ridges. Early dysplasia manifests with budding rete morphology, while minimal submucosal changes include increased vascularity, collagen, and inflammatory infiltrates. As OSF advances, collagen becomes homogenous with juxta-epithelial hyalinization, reduced vascularity, and dense fibrosis extending into deeper tissues, leading to muscle degeneration.[46] Several clinical and histopathological grading systems have been developed. However, the 2023 *WHO Classification of Head and Neck Tumors* recommends using the Kerr and colleagues[45] staging system for OSF, which categorizes the disease into 5 grades.[46] This staging system provides a detailed framework for assessing the progression of OSF, aiding clinicians in standardizing diagnosis, management, and prognosis across different cases. OSF is a potentially malignant disorder with a pooled MT rate of 4.2% (95% CI: 2.7%–5.6%).[47] Factors such as the duration and frequency of areca nut use, genetic susceptibility, and the presence of dysplastic changes influence the risk of transformation. Due to the irreversible nature of fibrosis, early intervention is crucial to prevent progression.[5,43,44] Management primarily involves cessation of areca nut use, medical therapy to alleviate symptoms, and, in advanced cases, surgical intervention to improve mouth opening.[48]

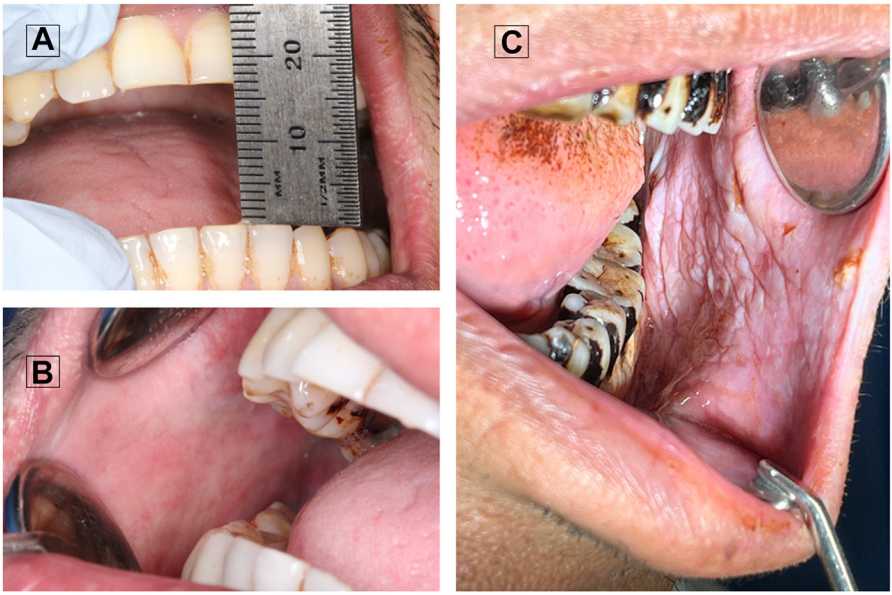

Fig. 5. Oral submucous fibrosis. (*A*) Significantly limited mouth opening in a 55 year old male patient with pale depigmented right buccal mucosa (*B*); biopsy showed significant fibrosis. (*C*) Teeth and mucosal discoloration associated with extensive leukoplakia in a background of oral submucous fibrosis in a 47 year old male biopsy showed moderate epithelial dysplasia (high-grade OED).

Descargado para Lucia Angulo (lu.maru26@gmail.com) en National Library of Health and Social Security de ClinicalKey.es por Elsevier en julio 10, 2025. Para uso personal exclusivamente. No se permiten otros usos sin autorización. Copyright ©2025. Elsevier Inc. Todos los derechos reservados.

Regular follow-up is essential to monitor for signs of MT, particularly in patients with long-standing OSF or those who continue to use areca nut products.[43]

Actinic cheilitis/Actinic keratosis (AC) affects the lips, particularly in individuals with significant sun exposure.[3,49] It is characterized by atrophic, scaly patches, typically on the lower lip, and is considered a precursor to OSCC.[50] AC generally presents as a poorly defined area of erythema and dryness on the lip, with scales and fissures. It is often accompanied by a loss of clear demarcation between the lip vermilion and adjacent skin (**Fig. 6**A, B).[49] The affected area may exhibit atrophic changes, ulcerations, or crusting, and there may be areas of hyperkeratosis.[3] In advanced cases, patients may report a burning sensation or discomfort.[50] AC is more common in individuals with fair skin and those who have a history of chronic sun exposure. It is particularly prevalent in geographic regions with high levels of sunlight, such as Australia, Southern Europe, and parts of the United States. Farmers, fishermen, and outdoor workers are at an increased risk of developing this condition due to occupational sun exposure.[49] The prevalence of actinic cheilitis increases with age and is higher in male individuals, likely due to increased cumulative sun exposure and less frequent use of protective measures such as lip balms with sunscreen. Mello and colleagues[51] reported an overall prevalence of 2.08% (95% CI: 0.94%–3.67%).[7] AC has an overall MT rate of 3.07%. Management typically involves minimizing further sun exposure through behavioral changes, such as wearing wide-brimmed hats and using lip balms with high SPF. In cases with severe dysplasia or persistent lesions, treatment options include cryotherapy, laser ablation, or surgical excision to prevent progression to carcinoma.[48]

MALIGNANT TRANSFORMATION AND PREDICTIVE FACTORS

Assessing the risk of malignant change in OPMDs involves a comprehensive approach that includes clinical history, examination, and histopathological evaluation.[5] Factors such as lesion color, texture, location, size, presence, and grade of dysplasia and patient demographics (eg, age, gender, and smoking status) influence the likelihood of MT.[5] For instance, erythroplakia and nonhomogeneous leukoplakia are considered high-risk lesions, while homogeneous leukoplakia and OLP are generally associated with lower risk.[22]

Although histopathological evaluation remains the current standard for assessing dysplasia and predicting malignant potential,[20] a holistic approach that combines clinical history, examination, and biopsy is essential for optimal risk assessment. Clinicians should be vigilant for changes in lesion characteristics, such as increased redness, ulceration, or pain, which may indicate MT. Early rebiopsy and intervention are crucial for improving patient outcomes.[5,48] Hence, the following flowchart has been proposed to assist clinicians in the risk assessment of OPMDs (**Fig. 7**).

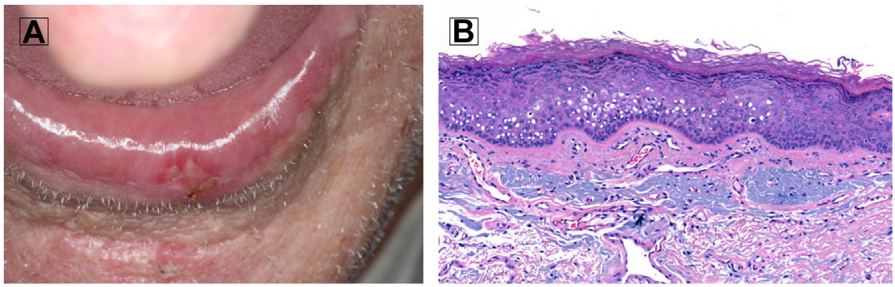

Fig. 6. Actinic cheilitis in an 82 year old farmer. (*A*) Note the loss of vermilion border, ulceration, and crusting on the left lip. (*B*) Biopsy showed hyperkeratosis with mild epithelial dysplasia (low-grade OED), dystrophic solar elastosis, and mild inflammatory infiltrate, × 60.

Descargado para Lucia Angulo (lu.maru26@gmail.com) en National Library of Health and Social Security de ClinicalKey.es por Elsevier en julio 10, 2025. Para uso personal exclusivamente. No se permiten otros usos sin autorización. Copyright ©2025. Elsevier Inc. Todos los derechos reservados.

EFFECTIVENESS OF DIAGNOSTIC ADJUNCTS

General dental practitioners play a crucial role in the early detection of OPMDs.[52] Conventional oral examination (COE) is still the current standard.[53] However, studies have shown adjunctive tools can assist in the detection and risk evaluation of OPMDs.[53–55] Diagnostic adjuncts include chemiluminescence, tissue autofluorescence, tissue fluorescence spectroscopy, vital staining, and cytology techniques. The following is the summary evidence on adjunctive aids for detecting OSCC and OPMDs.[53–57]

I. COE should remain the primary method for early screening of potentially malignant lesions. It should be supplemented by a thorough patient history, which includes identifying high-risk behaviors like smoking and alcohol use. COE is effective as a frontline detection tool, with adjunctive aids considered supplementary.
II. Adjunctive aids like chemiluminescence and tissue autofluorescence (eg, ViziLite and VELscope) are valuable for enhancing visual assessment, especially in suspicious lesions. However, they should not replace COE and biopsy confirmation. These tools are associated with subjectivity, variable specificity and sensitivity, and high false-positive rates. To overcome these limitations, a comprehensive assessment through COE is essential to validate their findings.
III. Narrow band imaging (NBI) has shown promise, especially for differentiating grades of intraepithelial papillary capillary loops, which may indicate early malignant changes. NBI can be particularly beneficial in specialist clinics but requires further training and equipment, making it less ideal for primary care settings without additional support.
IV. Cytology techniques, including brush biopsies, have demonstrated the highest diagnostic accuracy among adjuncts for evaluating suspicious lesions, with moderate sensitivity and high specificity. This makes cytologic testing valuable as a noninvasive follow-up for high-risk patients, helping to determine if a biopsy is necessary.
V. While useful, vital staining, such as toluidine blue, should not be the sole diagnostic tool due to variable specificity. It is beneficial for highlighting lesion boundaries and identifying higher risk areas but must be followed by histologic confirmation if malignancy is suspected.
VI. Light-based adjuncts like VELscope are commonly used but show significant limitations. Their low specificity often leads to false positives, which may result in unnecessary biopsies. Light-based tools can aid in visualizing lesion margins and areas of concern but should be used with clinical judgment and not as diagnostic replacements.
VII. In addition to aiding in diagnosis, adjunctive tools can help educate patients on lesion monitoring, especially for individuals with recurrent lesions or risk factors such as tobacco and alcohol use.
VIII. Evidence suggests that combining COE with adjuncts like cytology and, where appropriate, vital staining improves diagnostic accuracy. This combination approach leverages the strengths of each tool, reducing the likelihood of false negatives and false positives, which are common in light-based methods when used alone.[55,56]

FUTURE DIRECTIONS

Advances in molecular biology are paving the way for more targeted approaches to diagnosing, staging, and managing OPMDs.[58–64] Identifying biomarkers that predict MT could allow for more personalized management strategies focusing on high-risk individuals.[63] Additionally, immunotherapy and other novel treatments are being

Descargado para Lucia Angulo (lu.maru26@gmail.com) en National Library of Health and Social Security de ClinicalKey.es por Elsevier en julio 10, 2025. Para uso personal exclusivamente. No se permiten otros usos sin autorización. Copyright ©2025. Elsevier Inc. Todos los derechos reservados.

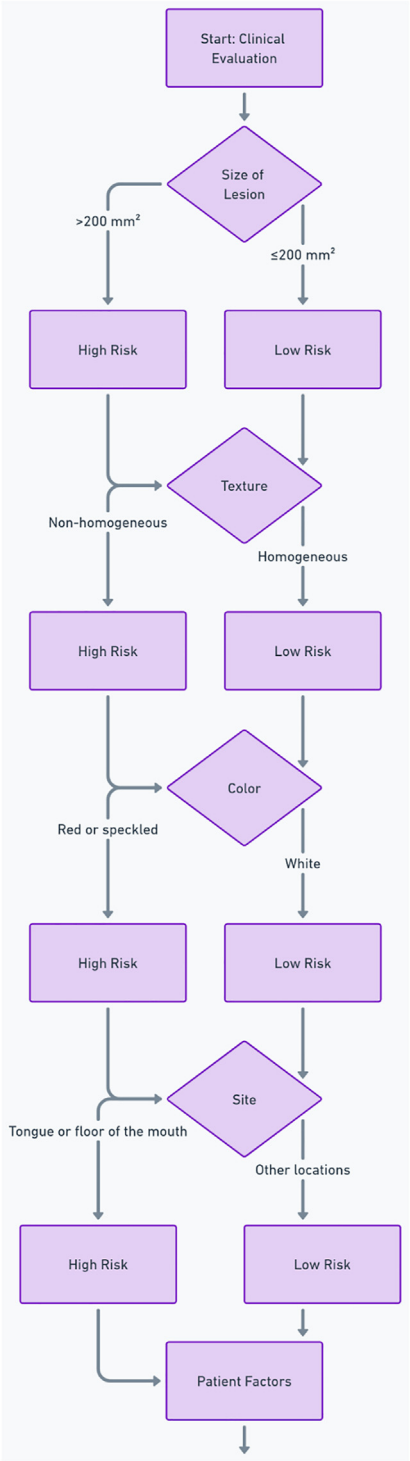

Fig. 7. A proposed flowchart to assist with the risk stratification of oral potentially malignant disorders.

Descargado para Lucia Angulo (lu.maru26@gmail.com) en National Library of Health and Social Security de ClinicalKey.es por Elsevier en julio 10, 2025. Para uso personal exclusivamente. No se permiten otros usos sin autorización. Copyright ©2025. Elsevier Inc. Todos los derechos reservados.

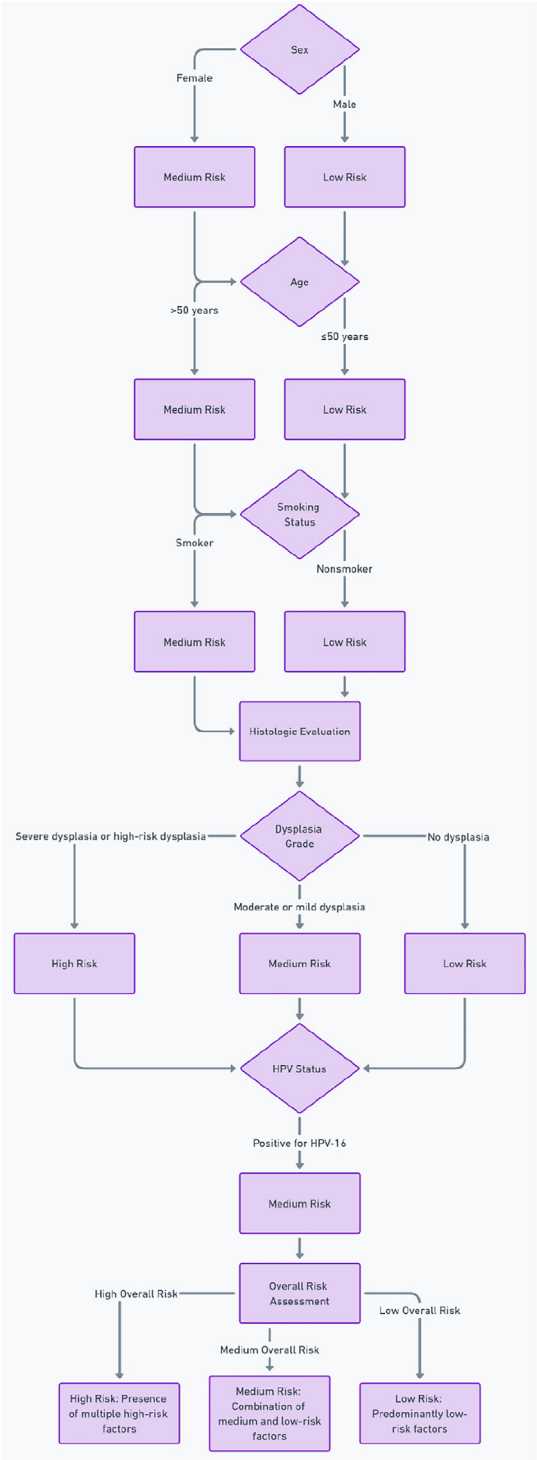

Fig. 7. (*continued*).

Descargado para Lucia Angulo (lu.maru26@gmail.com) en National Library of Health and Social Security de ClinicalKey.es por Elsevier en julio 10, 2025. Para uso personal exclusivamente. No se permiten otros usos sin autorización. Copyright ©2025. Elsevier Inc. Todos los derechos reservados.

explored as potential options for preventing the progression of OPMDs to OSCC.[65] New imaging technologies, such as confocal microscopy that can provide live pathology evaluation, might assist in the decision-making process for managing OPMDs and OSCC.[66–68] Nonetheless, while these biomarkers, techniques, and tools show promising potential, they require substantial refinement and validation over the coming years before they can be widely and reliably applied in clinical practice.

Artificial intelligence (AI) has recently emerged as a powerful tool for diagnosing and detecting OPMDs and OSCC.[69–71] AI, mainly through machine learning and deep learning algorithms, has shown promise in enhancing diagnostic accuracy, reducing interobserver variability, and aiding clinicians in decision-making.[70–73] AI algorithms, particularly convolutional neural networks, have been developed to analyze oral lesion images, including photographs and histopathological slides.[70–72] These models can assist in distinguishing between benign and potentially malignant lesions as they show promising sensitivity and specificity. Nevertheless, applying AI in the risk stratification of OPMDs is challenged by data quality and consistency, model transparency, integration with clinical workflows, and regulatory and ethical issues.[73,74] AI models require standardized, high-quality datasets, yet data for OPMDs are often inconsistent across clinical settings. Many AI tools' opaque "black-box" nature makes their predictions difficult to interpret, limiting clinician trust.[71] Additionally, integrating AI seamlessly into clinical workflows is challenging, as real-time performance and minimal training requirements are essential for widespread adoption.[74] Regulatory hurdles also require models to demonstrate reliability across diverse populations while ensuring data privacy. Lastly, AI models must generalize well across different demographic and environmental factors, demanding more globally representative datasets.[71,74] Tackling these issues requires collaboration among health care, regulatory, and technical experts.

SUMMARY

OPMDs represent a diverse group of conditions with the potential for MT. Early identification and appropriate management are crucial to reducing the burden of oral cancer. While significant progress has been made in understanding these disorders' etiology, risk factors, and management, further research is needed to improve diagnostic accuracy and develop effective interventions. General dentists, equipped with knowledge of diagnostic adjuncts and risk factors, are uniquely positioned to contribute to the early detection and prevention of oral cancer.

CLINICS CARE POINTS

- Always biopsy lesions suspected of OPMDs, histopathology remains the gold standard for diagnosis and risk stratification.
- Document lesion characteristics (location, size, color, texture) and update regularly.
- Use adjunctive tools judiciously; they support but do not replace COE and biopsy.
- Refer complex or non-resolving cases early to specialists for evaluation.
- Assess and document risk habits such as tobacco, alcohol, and areca nut use.
- Schedule regular follow-up appointments, especially for high-risk lesions like erythroplakia or PVL.
- Educate patients about their condition, potential risks, and the importance of compliance with follow-up.
- Use high-resolution intraoral photographs to document lesion progression or resolution.

Descargado para Lucia Angulo (lu.maru26@gmail.com) en National Library of Health and Social Security de ClinicalKey.es por Elsevier en julio 10, 2025. Para uso personal exclusivamente. No se permiten otros usos sin autorización. Copyright ©2025. Elsevier Inc. Todos los derechos reservados.

DECLARATION OF AI AND AI-ASSISTED TECHNOLOGIES IN THE WRITING PROCESS

During the preparation of this work, the author used ChatGPT 4, supported by Whimsical, to create the flowchart. After using this tool, the author reviewed and edited the content as needed and takes full responsibility for the content of the publication.

DISCLOSURE

None.

REFERENCES

1. Warnakulasuriya S, Johnson NW, van der Waal I. Nomenclature and classification of potentially malignant disorders of the oral mucosa. J Oral Pathol Med 2007; 36(10):575–80.
2. Bouvard V, Nethan ST, Singh D, et al. IARC perspective on oral cancer prevention. N Engl J Med 2022;387(21):1999–2005.
3. Warnakulasuriya S, Kujan O, Aguirre-Urizar JM, et al. Oral potentially malignant disorders: a consensus report from an international seminar on nomenclature and classification, convened by the WHO Collaborating Centre for Oral Cancer. Oral Dis 2021;27(8):1862–80.
4. Nikitakis NG. Special focus issue on potentially premalignant oral epithelial lesions: introduction and perspective. Oral Surg Oral Med Oral Pathol Oral Radiol 2018;125(6):575–6.
5. Speight PM, Khurram SA, Kujan O. Oral potentially malignant disorders: risk of progression to malignancy. Oral Surg Oral Med Oral Pathol Oral Radiol 2018; 125(6):612–27.
6. Celentano A, Cirillo N. Diseases with oral malignant potential: need for change to inform research, policy, and practice. J Oral Pathol Med 2024;53(8):495–501.
7. Mello FW, Miguel AFP, Dutra KL, et al. Prevalence of oral potentially malignant disorders: a systematic review and meta-analysis. J Oral Pathol Med 2018; 47(7):633–40.
8. Mehta FS, Gupta PC, Pindborg JJ. Chewing and smoking habits in relation to precancer and oral cancer. J Cancer Res Clin Oncol 1981;99(1–2):35–9.
9. Lee CH, Ko YC, Huang HL, et al. The precancer risk of betel quid chewing, tobacco use and alcohol consumption in oral leukoplakia and oral submucous fibrosis in southern Taiwan. Br J Cancer 2003;88(3):366–72.
10. Gupta B, Johnson NW. Systematic review and meta-analysis of association of smokeless tobacco and of betel quid without tobacco with incidence of oral cancer in South Asia and the Pacific. PLoS One 2014;9(11):e113385.
11. Morse DE, Psoter WJ, Cleveland D, et al. Smoking and drinking in relation to oral cancer and oral epithelial dysplasia. Cancer Causes Control 2007;18(9):919–29.
12. Amarasinghe HK, Usgodaarachchi US, Johnson NW, et al. Betel-quid chewing with or without tobacco is a major risk factor for oral potentially malignant disorders in Sri Lanka: a case-control study. Oral Oncol 2010;46(4):297–301.
13. Syrjänen S, Lodi G, von Bültzingslöwen I, et al. Human papillomaviruses in oral carcinoma and oral potentially malignant disorders: a systematic review. Oral Dis 2011;17(Suppl 1):58–72.
14. Eloranta R, Vilén ST, Keinänen A, et al. Oral squamous cell carcinoma: effect of tobacco and alcohol on cancer location. Tob Induc Dis 2024;22:112.
15. Tan Y, Wang Z, Xu M, et al. Oral squamous cell carcinomas: state of the field and emerging directions. Int J Oral Sci 2023;15(1):44.

Descargado para Lucia Angulo (lu.maru26@gmail.com) en National Library of Health and Social Security de ClinicalKey.es por Elsevier en julio 10, 2025. Para uso personal exclusivamente. No se permiten otros usos sin autorización. Copyright ©2025. Elsevier Inc. Todos los derechos reservados.

16. Farah CS, Kujan O, Prime S, et al. Oral mucosal malignancies. In: Farah CS, Balasubramaniam R, McCullough MJ, editors. Contemporary oral medicine: a comprehensive approach to clinical practice. Cham: Springer International Publishing; 2019. p. 1249–436.
17. Muller S and Tilakaratne WM, Oral potentially malignant disorders, In: Odell EW, *WHO classification of tumours editorial board. Head and neck tumours*, 2023, International Agency for Research on Cancer; Lyon, France, (WHO classification of tumours series, 5th edition; vol. 9). Available at: https://publications.iarc.who.int/629 (Accessed 26 September 2024).
18. Warnakulasuriya S. Oral potentially malignant disorders: a comprehensive review on clinical aspects and management. Oral Oncol 2020;102:104550.
19. Wetzel SL, Wollenberg J. Oral potentially malignant disorders. Dent Clin North Am 2020;64(1):25–37.
20. Odell E, Kujan O, Warnakulasuriya S, et al. Oral epithelial dysplasia: recognition, grading and clinical significance. Oral Dis 2021;27(8):1947–76.
21. Warnakulasuriya S. Clinical features and presentation of oral potentially malignant disorders. Oral Surg Oral Med Oral Pathol Oral Radiol 2018;125(6):582–90.
22. Iocca O, Sollecito TP, Alawi F, et al. Potentially malignant disorders of the oral cavity and oral dysplasia: a systematic review and meta-analysis of malignant transformation rate by subtype. Head Neck 2020;42(3):539–55.
23. Chaturvedi AK, Udaltsova N, Engels EA, et al. Oral leukoplakia and risk of progression to oral cancer: a population-based cohort study. J Natl Cancer Inst 2020;112(10):1047–54.
24. Villa A, Woo SB. Leukoplakia-A diagnostic and management algorithm. J Oral Maxillofac Surg 2017;75(4):723–34.
25. Thompson LDR, Fitzpatrick SG, Müller S, et al. Proliferative verrucous leukoplakia: an expert consensus guideline for standardized assessment and reporting. Head Neck Pathol 2021;15(2):572–87.
26. Villa A, Menon RS, Kerr AR, et al. Proliferative leukoplakia: proposed new clinical diagnostic criteria. Oral Dis 2018;24(5):749–60.
27. Ramos-García P, González-Moles M, Mello FW, et al. Malignant transformation of oral proliferative verrucous leukoplakia: a systematic review and meta-analysis. Oral Dis 2021;27(8):1896–907.
28. Eisenberg E, Fitzpatrick SG, Kallarakkal TG, et al, Proliferative verrucous leukoplakia, In: Muller S, Odell EW and Tilakaratne WM, *WHO classification of tumours editorial board. Head and neck tumours*, 2023, International Agency for Research on Cancer; Lyon, France, (WHO classification of tumours series, 5th edition; vol. 9). Available at https://publications.iarc.who.int/629 (Accessed 26 September 2024).
29. van der Waal I, Scully C. Oral cancer: comprehending the condition, causes, controversies, control and consequences. 4. Potentially malignant disorders of the oral and oropharyngeal mucosa. Dent Update 2011;38(2):138–40.
30. Warnakulasuriya S. White, red, and mixed lesions of oral mucosa: a clinicopathologic approach to diagnosis. Periodontol 2000 2019;80(1):89–104.
31. Lorenzo-Pouso AI, Lafuente-Ibáñez de Mendoza I, Pérez-Sayáns M, et al. Critical update, systematic review, and meta-analysis of oral erythroplakia as an oral potentially malignant disorder. J Oral Pathol Med 2022;51(7):585–93.
32. Al-Hashimi I, Schifter M, Lockhart PB, et al. Oral lichen planus and oral lichenoid lesions: diagnostic and therapeutic considerations. Oral Surg Oral Med Oral Pathol Oral Radiol Endod 2007;103(Suppl):S25.e1-12.

Descargado para Lucia Angulo (lu.maru26@gmail.com) en National Library of Health and Social Security de ClinicalKey.es por Elsevier en julio 10, 2025. Para uso personal exclusivamente. No se permiten otros usos sin autorización. Copyright ©2025. Elsevier Inc. Todos los derechos reservados.

33. Carrozzo M, Porter S, Mercadante V, et al. Oral lichen planus: a disease or a spectrum of tissue reactions? Types, causes, diagnostic algorhythms, prognosis, management strategies. Periodontol 2000 2019;80(1):105–25.
34. El-Howati A, Thornhill MH, Colley HE, et al. Immune mechanisms in oral lichen planus. Oral Dis 2023;29(4):1400–15.
35. Cheng YS, Gould A, Kurago Z, et al. Diagnosis of oral lichen planus: a position paper of the American Academy of Oral and Maxillofacial Pathology. Oral Surg Oral Med Oral Pathol Oral Radiol 2016;122(3):332–54.
36. van der Meij EH, van der Waal I. Lack of clinicopathologic correlation in the diagnosis of oral lichen planus based on the presently available diagnostic criteria and suggestions for modifications. J Oral Pathol Med 2003;32(9):507–12.
37. Idrees M, Farah CS, Khurram SA, et al. Observer agreement in the diagnosis of oral lichen planus using the proposed criteria of the American Academy of Oral and Maxillofacial Pathology. J Oral Pathol Med 2021;50(5):520–7.
38. González-Moles M, Warnakulasuriya S, González-Ruiz I, et al. Worldwide prevalence of oral lichen planus: a systematic review and meta-analysis. Oral Dis 2021;27(4):813–28.
39. Idrees M, Kujan O, Shearston K, et al. Oral lichen planus has a very low malignant transformation rate: a systematic review and meta-analysis using strict diagnostic and inclusion criteria. J Oral Pathol Med 2021;50(3):287–98.
40. González-Moles M, Ruiz-Ávila I, González-Ruiz L, et al. Malignant transformation risk of oral lichen planus: a systematic review and comprehensive meta-analysis. Oral Oncol 2019;96:121–30.
41. Müller S. Oral lichenoid lesions: distinguishing the benign from the deadly. Mod Pathol 2017;30(s1):S54–67.
42. Schifter M, Yeoh SC, Coleman H, et al. Oral mucosal diseases: the inflammatory dermatoses. Aust Dent J 2010;55(Suppl 1):23–38.
43. Rao NR, Villa A, More CB, et al. Oral submucous fibrosis: a contemporary narrative review with a proposed inter-professional approach for an early diagnosis and clinical management. J Otolaryngol Head Neck Surg 2020;49(1):3.
44. Tilakaratne WM, Ekanayaka RP, Warnakulasuriya S. Oral submucous fibrosis: a historical perspective and a review on etiology and pathogenesis. Oral Surg Oral Med Oral Pathol Oral Radiol 2016;122(2):178–91.
45. Kerr AR, Warnakulasuriya S, Mighell AJ, et al. A systematic review of medical interventions for oral submucous fibrosis and future research opportunities. Oral Dis 2011;17(Suppl 1):42–57.
46. Warnakulasuriya S and Ranganathan K, Submucous fibrosis, In: Tilakaratne WM, Muller S and Odell EW, *WHO classification of tumours editorial board. Head and neck tumours*, 2023, International Agency for Research on Cancer; Lyon, France, (WHO classification of tumours series, 5th edition; vol. 9). Available at: https://publications.iarc.who.int/629 (Accessed 26 September 2024).
47. Kujan O, Mello FW, Warnakulasuriya S. Malignant transformation of oral submucous fibrosis: a systematic review and meta-analysis. Oral Dis 2021;27(8):1936–46.
48. Kerr AR, Lodi G. Management of oral potentially malignant disorders. Oral Dis 2021;27(8):2008–25.
49. Savage NW, McKay C, Faulkner C. Actinic cheilitis in dental practice. Aust Dent J 2010;55(Suppl 1):78–84.
50. Lim GF, Cusack CA, Kist JM. Perioral lesions and dermatoses. Dent Clin North Am 2014;58(2):401–35.

Descargado para Lucia Angulo (lu.maru26@gmail.com) en National Library of Health and Social Security de ClinicalKey.es por Elsevier en julio 10, 2025. Para uso personal exclusivamente. No se permiten otros usos sin autorización. Copyright ©2025. Elsevier Inc. Todos los derechos reservados.

51. Dancyger A, Heard V, Huang B, et al. Malignant transformation of actinic cheilitis: a systematic review of observational studies. J Investig Clin Dent 2018;9(4): e12343.
52. Gaballah K, Faden A, Fakih FJ, et al. Diagnostic accuracy of oral cancer and suspicious malignant mucosal changes among future dentists. Healthcare (Basel) 2021;9(3):263.
53. Walsh T, Warnakulasuriya S, Lingen MW, et al. Clinical assessment for the detection of oral cavity cancer and potentially malignant disorders in apparently healthy adults. Cochrane Database Syst Rev 2021;12(12):CD010173.
54. Lau J, O G, Warnakulasuriya S, et al. Adjunctive aids for the detection of oral squamous cell carcinoma and oral potentially malignant disorders: a systematic review of systematic reviews. Jpn Dent Sci Rev 2024;60:53–72.
55. Yang EC, Tan MT, Schwarz RA, et al. Noninvasive diagnostic adjuncts for the evaluation of potentially premalignant oral epithelial lesions: current limitations and future directions. Oral Surg Oral Med Oral Pathol Oral Radiol 2018;125(6): 670–81.
56. Lingen MW, Tampi MP, Urquhart O, et al. Adjuncts for the evaluation of potentially malignant disorders in the oral cavity: diagnostic test accuracy systematic review and meta-analysis-a report of the American Dental Association. J Am Dent Assoc 2017;148(11):797–813.e752.
57. Walsh T, Macey R, Kerr AR, et al. Diagnostic tests for oral cancer and potentially malignant disorders in patients presenting with clinically evident lesions. Cochrane Database Syst Rev 2021;7(7):CD010276.
58. Yap T, Celentano A, Seers C, et al. Molecular diagnostics in oral cancer and oral potentially malignant disorders-A clinician's guide. J Oral Pathol Med 2020;49(1):1–8.
59. El-Sakka H, Kujan O, Farah CS. Assessing miRNAs profile expression as a risk stratification biomarker in oral potentially malignant disorders: a systematic review. Oral Oncol 2018;77:57–82.
60. Monteiro L, Mello FW, Warnakulasuriya S. Tissue biomarkers for predicting the risk of oral cancer in patients diagnosed with oral leukoplakia: a systematic review. Oral Dis 2021;27(8):1977–92.
61. Lim I, Tan J, Alam A, et al. Epigenetics in the diagnosis and prognosis of head and neck cancer: a systematic review. J Oral Pathol Med 2024;53(2):90–106.
62. Villa A, Celentano A, Glurich I, et al. World Workshop on Oral Medicine VII: prognostic biomarkers in oral leukoplakia: a systematic review of longitudinal studies. Oral Dis 2019;25 Suppl 1(Suppl 1):64–78.
63. Balakittnen J, Ekanayake Weeramange C, Wallace DF, et al. A novel saliva-based miRNA profile to diagnose and predict oral cancer. Int J Oral Sci 2024;16(1):14.
64. Celentano A, Glurich I, Borgnakke WS, et al. World Workshop on Oral Medicine VII: prognostic biomarkers in oral leukoplakia and proliferative verrucous leukoplakia-A systematic review of retrospective studies. Oral Dis 2021;27(4):848–80.
65. Hanna GJ, Villa A, Nandi SP, et al. Nivolumab for patients with high-risk oral leukoplakia: a nonrandomized controlled trial. JAMA Oncol 2024;10(1):32–41.
66. Farah CS, Janik M, Woo SB, et al. Dynamic real-time optical microscopy of oral mucosal lesions using confocal laser endomicroscopy. J Oral Pathol Med 2023; 52(6):539–47.
67. Sievert M, Oetter N, Mantsopoulos K, et al. Systematic classification of confocal laser endomicroscopy for the diagnosis of oral cavity carcinoma. Oral Oncol 2022;132:105978.

Descargado para Lucia Angulo (lu.maru26@gmail.com) en National Library of Health and Social Security de ClinicalKey.es por Elsevier en julio 10, 2025. Para uso personal exclusivamente. No se permiten otros usos sin autorización. Copyright ©2025. Elsevier Inc. Todos los derechos reservados.

68. Yap T, Tan I, Ramani RS, et al. Acquisition and annotation in high resolution in vivo digital biopsy by confocal microscopy for diagnosis in oral precancer and cancer. Front Oncol 2023;13:1209261.
69. Kouketsu A, Doi C, Tanaka H, et al. Detection of oral cancer and oral potentially malignant disorders using artificial intelligence-based image analysis. Head Neck 2024;46(9):2253–60.
70. Adeoye J, Koohi-Moghadam M, Lo AWI, et al. Deep learning predicts the malignant-transformation-free survival of oral potentially malignant disorders. Cancers (Basel) 2021;13(23):6054.
71. Pham TD, Teh MT, Chatzopoulou D, et al. Artificial intelligence in head and neck cancer: innovations, applications, and future directions. Curr Oncol 2024;31(9):5255–90.
72. Shephard AJ, Bashir RMS, Mahmood H, et al. A fully automated and explainable algorithm for predicting malignant transformation in oral epithelial dysplasia. NPJ Precis Oncol 2024;8(1):137.
73. Adeoye J, Su YX. Leveraging artificial intelligence for perioperative cancer risk assessment of oral potentially malignant disorders. Int J Surg 2024;110(3):1677–86.
74. Uppal S, Kumar Shrivastava P, Khan A, et al. Machine learning methods in predicting the risk of malignant transformation of oral potentially malignant disorders: a systematic review. Int J Med Inform 2024;186:105421.

Descargado para Lucia Angulo (lu.maru26@gmail.com) en National Library of Health and Social Security de ClinicalKey.es por Elsevier en julio 10, 2025. Para uso personal exclusivamente. No se permiten otros usos sin autorización. Copyright ©2025. Elsevier Inc. Todos los derechos reservados.