

# Laparoscopic Abdominal Cerclage



Shabnam Gupta, MD<sup>a,b,\*</sup>, Jon Ivar Einarsson, MD, PhD, MPH<sup>a,b</sup>

## KEYWORDS

- Laparoscopic abdominal cerclage • Cervical insufficiency
- Minimally invasive gynecology

## KEY POINTS

- Laparoscopic abdominal cerclage is a highly effective, well-tolerated surgical treatment of patients with refractory cervical insufficiency or anatomic limitations to vaginal cerclage.
- Transabdominal cerclage is preferred for patients with cervical insufficiency and a prior failed vaginal cerclage, given improved birth outcomes compared with repeat transvaginal cerclage.
- Suggested benefits of abdominal cerclage compared with vaginal cerclage include a more proximal placement at the level of the internal os, greater mechanical support to the cervix, decreased risk of caudal suture migration as pregnancy progresses, and possible reduced risk of ascending intrauterine infections due to the absence of foreign body material in the vagina.
- Neonatal survival rates more than 96% and mean gestational age of 37 weeks at delivery have been observed in subsequent pregnancies with laparoscopic abdominal cerclage in place.

## INTRODUCTION

Preterm birth is a significant cause of infant morbidity and mortality. A well-established cause of preterm birth is cervical insufficiency, which occurs in up to 8% of women with a history of miscarriage and approximately 1% of all pregnancies.<sup>1</sup> Recommended treatment of patients with cervical insufficiency includes a cerclage placement or procedure in which a stitch is tied around the cervix. Cerclages function by providing structural support to the cervix and keeping it artificially closed throughout pregnancy. Cerclages can be placed transvaginally or transabdominally. In this article, we will discuss transabdominal cerclages with emphasis placed on the indications, surgical technique, and clinical outcomes associated with a minimally invasive approach.

---

<sup>a</sup> Brigham & Women's Hospital, Harvard Medical School, 75 Francis Street, CWN 3rd Floor, MIGS Office, Boston, MA 02115, USA; <sup>b</sup> Division of Minimally Invasive Gynecology, Harvard Medical School, 75 Francis Street, CWN 3rd Floor, MIGS Office, Boston, MA 02115, USA

\* Corresponding author.

E-mail address: [sgupta44@bwh.harvard.edu](mailto:sgupta44@bwh.harvard.edu)

Twitter: @ShabnamGuptaMD (S.G.)

Obstet Gynecol Clin N Am 49 (2022) 287–297

<https://doi.org/10.1016/j.ogc.2022.02.010>

0889-8545/22/© 2022 Elsevier Inc. All rights reserved.

[obgyn.theclinics.com](http://obgyn.theclinics.com)

## ***Cervical Insufficiency***

---

Cervical insufficiency is defined as an inability of the uterine cervix to maintain a pregnancy in the second-trimester, without signs of labor, clinical contractions, or both.<sup>2</sup> This often follows painless cervical dilation or cervical shortening. While the clinical presentation can vary, this condition often presents around 16 to 18 weeks of gestation with subsequent preterm or previable delivery.

Structural weakness of the cervix can be a result of cervical trauma (prior operative vaginal deliveries, surgery of the cervix or uterus including loop electrosurgical excision or conization, mechanical dilation during pregnancy terminations) or congenital abnormalities (collagen disorders such as Ehlers–Danlos syndrome, Mullerian anomalies, in utero diethylstilbestrol exposure).<sup>3</sup> Second-trimester births and fetal losses can also be caused by infection or decidual inflammation, bleeding at the decidua-placenta interface, or overdistension of the uterus. These each result in biochemical changes in the cervix leading to shortening and/or dilation with subsequent preterm delivery.

In select cases, a cerclage can be placed to prevent second-trimester loss or subsequent preterm birth in a pregnancy affected by painless cervical dilation or very short cervix. This is termed a rescue cerclage. Alternatively, a cerclage can be placed prophylactically or before conception in women with a history of previous preterm deliveries or fetal losses due to cervical insufficiency.

## ***Discussion***

---

### ***History of cerclages***

Transvaginal cerclage placement was first described by Shirodkar and McDonald in the 1950s.<sup>4,5</sup> Traditionally, cerclages have been placed with nonabsorbable sutures via a vaginal approach. In the McDonald procedure, a simple, purse-string suture is inserted at the cervicovaginal junction. In the Shirodkar procedure, the stitch is placed higher up on the cervix, requiring the dissection of the vesicocervical mucosa to expose tissue closer to the level of the internal cervical os. The suture is then placed, and the mucosa is closed back over the secured knot. Surgeon preference typically guides treatment approach, as neither surgical technique has demonstrated superior outcomes.<sup>6,7</sup>

In 1965, Benson and Durfee proposed a transabdominal approach to cerclage placement at the cervicoisthmic junction.<sup>8</sup> This approach differed from the historically performed Shirodkar and McDonald techniques which place the cerclage more distally at the intersection of the cervix and vaginal fornix (**Fig. 1**). The laparoscopic approach to transabdominal cerclage was first reported in 1998 and has been gaining increased popularity since this time (**Fig. 2**).<sup>9</sup>

## **WHEN TO CONSIDER TRANSABDOMINAL CERCLAGE**

Transabdominal cervicoisthmic cerclage was initially suggested for women with a history of cervical insufficiency and anatomy that precluded a transvaginal cerclage (history of trachelectomy, inadequate vaginal access). Over the past 50 years, abdominal cerclage indications have been expanded to also include women with refractory cervical insufficiency.<sup>10</sup>

Women who have experienced a second-trimester fetal loss or preterm birth despite an appropriately timed and placed transvaginal cerclage are considered to have refractory cervical insufficiency and should be offered an abdominal cerclage (**Fig. 3**). It is important to rule out other causes of second-trimester loss including large fibroids or Mullerian anomalies with a thorough history and imaging studies as needed.

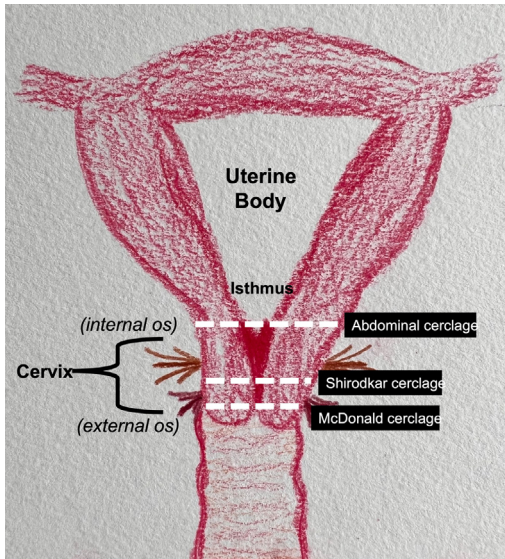


Fig. 1. Anatomic placement of various cerclage types.

Recent evidence suggests that an abdominal cerclage improves neonatal outcomes compared with repeat vaginal cerclage in patients with one prior failed vaginal cerclage.<sup>11</sup> Providers should individualize counseling and adhere to principles of beneficence and nonmaleficence to help each patient reach their unique reproductive health goals.

A recent 2020 landmark randomized controlled trial of abdominal versus vaginal cerclage (the MAVRIC trial or Multicentre Abdominal vs Vaginal Randomized Intervention of Cerclage) has provided substantial validation for the belief that an abdominal approach is a preferred approach for patients with cervical insufficiency and a prior failed vaginal cerclage given improved birth outcomes and superior reduction in risk of early preterm birth and fetal loss in women with previous failed vaginal cerclage compared with repeat transvaginal placement.<sup>12</sup> This study evaluated 111 women with a single prior failed vaginal cerclage (fetal loss or preterm birth between 14 and 28 weeks of gestation). Patients were randomized to either an open abdominal cerclage or repeat vaginal cerclage placement. Results of this trial found that preterm birth

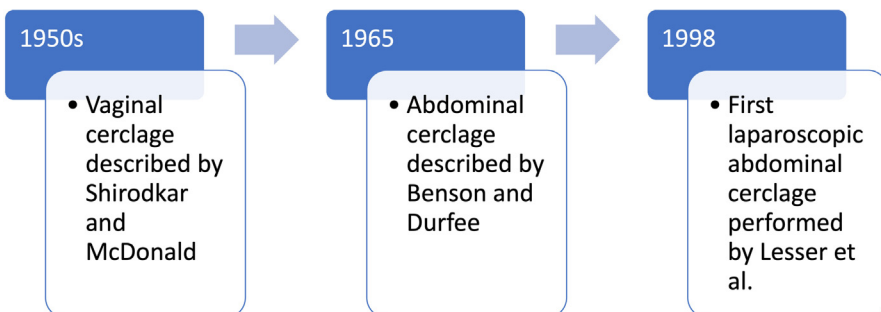


Fig. 2. Historical timeline of cerclage use.

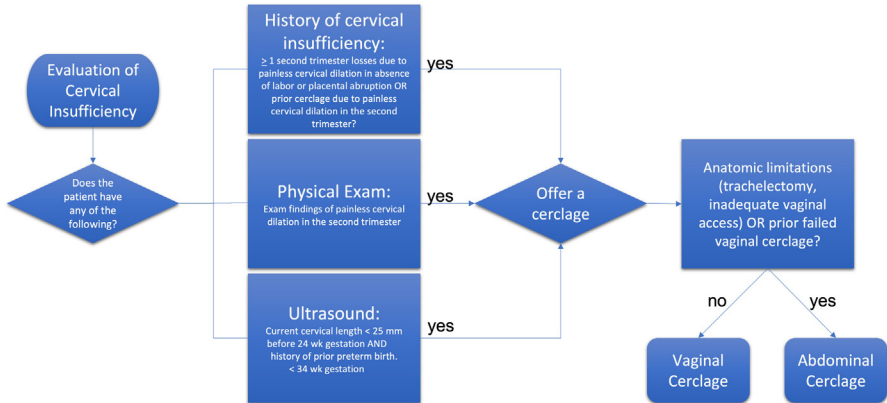


Fig. 3. Cerclage decision tree.

before 32 weeks of gestation occurred in only 8% of women randomized to an abdominal cerclage, compared with 38% of women randomized to a repeat vaginal cerclage ( $P = .008$ ).

Contraindications to transabdominal cerclage are similar to those for transvaginal cerclage. Clinical scenarios in which cerclages are unlikely to reduce the risk of preterm birth or improve fetal outcomes include fetal anomalies incompatible with life, intrauterine infections, active uterine bleeding, active labor, preterm rupture of membranes, and fetal demise. A relative contraindication includes the presence of prolapsed fetal membranes through the external cervical os. In these cases, the potential risk of iatrogenic rupture of membranes may exceed 50%.<sup>2,6</sup>

### ADVANTAGES OF A LAPAROSCOPIC, MINIMALLY INVASIVE APPROACH

The advantage of the abdominal approach compared with the vaginal approach is the ability to place the suture at or slightly above the level of the internal os, providing greater mechanical support to the cervix. There is also decreased risk of caudal suture migration as pregnancy progresses and the uterus enlarges.<sup>13</sup> Additionally, an abdominal cerclage avoids the prolonged presence of a foreign body within the vagina, which may reduce the potential for ascending infections and resulting preterm labor or premature rupture of membranes.

Transabdominal cerclage has been underutilized in the past due to the need for cesarean section, risk of intraoperative blood loss at the uterine vessels, and historically, the need for a laparotomy with associated morbidity (risks of poor postoperative pain control, overnight hospital admission, and delayed return to normal activities). Laparoscopy has many benefits over laparotomy, including smaller incisions with faster postoperative healing, reduced risks of postoperative wound infections, quicker return to baseline function, less blood loss, and ability to undergo outpatient surgery.<sup>14</sup> While the cesarean section is still required for delivery, increased surgeon experience and more widespread use of minimally invasive surgery has encouraged more physicians to offer laparoscopic abdominal cerclage to patients with the aforementioned indications.

Moawad and colleagues noted in a systematic review of laparoscopic abdominal cerclage that neonatal outcomes were similar compared with laparotomy. In this review, 1844 women who underwent laparoscopically versus open abdominal cerclage were found to have no significant difference in neonatal survival rates (90% for

laparoscopic and 91% for open cerclage,  $P = .8$ ).<sup>15</sup> Of note, after excluding first trimester losses from the analysis, women who underwent laparoscopic abdominal cerclage had significantly greater neonatal survival rates (97% vs 90%,  $P < .01$ ). First trimester losses are unlikely to be related to cervical insufficiency or cerclage placement and can, therefore, be appropriately excluded.

### **Timing of Laparoscopic Abdominal Cerclage**

Laparoscopic cerclages are ideally placed prior to conception (termed an interval cerclage) for multiple reasons. The nonpregnant uterus is smaller in size and can accommodate a uterine manipulator. These factors give the surgeon better visualization of anatomy for proper cerclage placement. Surgeons face additional challenges including increased paracervical vasculature, blood supply, and tissue softness with a gravid uterus.<sup>13</sup> Preconception abdominal cerclage placement is associated with lower rates of repeat spontaneous pregnancy loss and preterm labor, and less surgical and pregnancy-related morbidity compared with postconception placement.<sup>16</sup> Studies have shown that preconception cerclage placement does not impact fertility.<sup>17</sup>

Optimal timing for laparoscopic abdominal cerclage placement in pregnancy is the late first trimester or early second trimester (8–12 weeks). This time period reduces the risk of miscarriage associated with earlier gestation, enables time for exclusion of major anomalies from aneuploidy screening and ultrasound studies, and ensures that the uterus is not too large, which can make cerclage placement more technically challenging. More advanced pregnancies can be offered abdominal cerclage placement after appropriately counseling, depending on the clinical picture and surgeon experience. Postconception cerclage placement confers a small risk of fetal loss, with estimated rates of 1.2% in laparoscopic cases and 3% of open cases.<sup>12</sup>

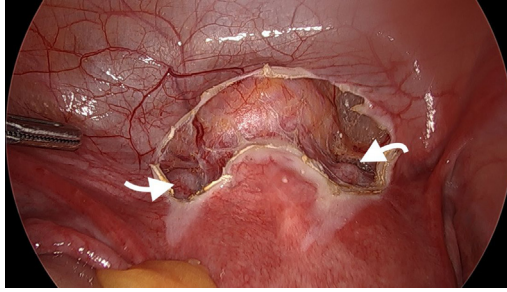
### **SURGICAL TECHNIQUE**

Here we will describe our surgical approach to laparoscopic abdominal cerclage placement in a nonpregnant patient. No prophylactic antibiotics are administered before incision. Laparoscopic abdominal cerclage placement is performed under general anesthesia with the patient in the dorsal lithotomy position. A catheter is placed in the bladder to keep it decompressed throughout the procedure. Port placement is guided by surgeon preference. We prefer to use 4 ports: a 10-mm scope at the umbilicus, two 5-mm ports in the bilateral lower quadrants, and a fourth ipsilateral port in the left upper quadrant. In nonpregnant women, a uterine manipulator is placed to assist with the traction and delineation of planes for proper angulation and placement of the suture needle. No manipulator is placed in a gravid uterus, although a sponge stick could be considered.

The procedure starts with the dissection of the vesicouterine peritoneum to expose the uterine arteries anteriorly and move the bladder slightly caudad (**Fig. 4**).

Next, a 5-mm Mersilene polyester tape with blunt-tip needles on either side is used for cerclage placement. This is the same tape commonly used for transvaginal cerclages. The blunt-tip needles are straightened out before insertion using heavy-duty needle holders (**Fig. 5**). We find that the needles are unnecessarily long for laparoscopic cerclages, thus grasping the needle closer to the tip can help with needle management.

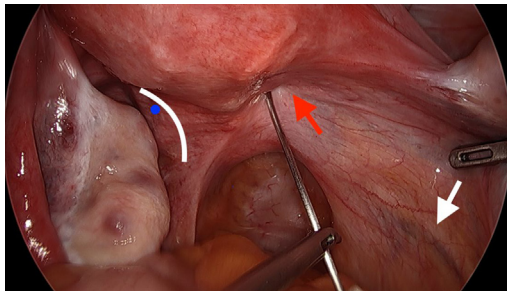
The posterior broad ligament is not opened before needle insertion, as opening this area can add the unnecessary risk of underlying vessel injury. Direct insertion of the needle simplifies the procedure and has not led to any complications thus far. The ureter is identified, and its course is followed distally (**Fig. 6**).



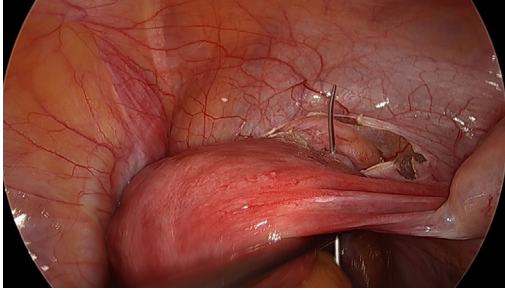
**Fig. 4.** Dissection of the anterior vesicouterine peritoneum. The uterine arteries are indicated by white arrows.



**Fig. 5.** A single Mersilene tape (12-inch length, 5-mm width) with double-armed blunt point needles is used for laparoscopic abdominal cerclage. The curved needles are straightened to allow for insertion through laparoscopic trocars and to aid in needle handling.



**Fig. 6.** Placement of the first needle on the right. The uterine artery is indicated with a red arrow, the ureter with a white arrow, and the site of anticipated needle insertion on the left is shown with a blue dot. The curved white line highlights the lateral border of the cervix.

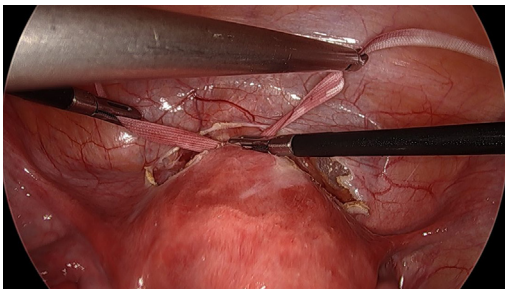


**Fig. 7.** Twisting the uterus with the uterine manipulator (*left hand*) enables the surgeon to better visualize the correct exit point and direct the needle placement (*right hand*).

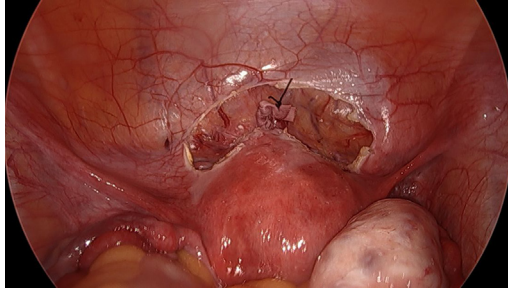
Our preference is to insert the suture posteriorly at the level of the internal cervical os, just above the insertion of the uterosacral ligaments. It can be helpful to think of the uterus and cervix as an hourglass, with the level of the internal os as the narrowest point of the hourglass. The suture is carefully passed in the space between the uterine vessels and cervical stroma. The uterine artery (identified by its pulsation) should be lateral to the placement of the needle, and the uterosacral ligament should be below. The use of blunt needles is advantageous because it enables the surgeon to direct the needle more medially to avoid uterine vessels, and then adjust placement more laterally if the resistance of the cervix is encountered. Proper placement of suture follows a low resistance path. We find it helpful to twist the uterus with the uterine manipulator in one hand, while placing and directing the needle path in tandem with the other hand (**Fig. 7**). Once the needles are passed bilaterally, they are cut off the Mersilene tape and removed through the ports.

The 2 free ends of the Mersilene tape are then pulled anteriorly to ensure that the suture is tightened and flush with the posterior cervix. The tape is then secured using intracorporeal knot tying. It is important to ensure that the first and second knots are tied down snugly and flat against the anterior cervix. We find it helpful to have the assistant hold down the first knot with a grasper, so that it doesn't slip while the second knot is tied (**Fig. 8**). Our approach is to secure 6 square knots.

Once the knots have been secured, the tape is trimmed and secured to the lower uterine segment with a 2.0 silk suture to prevent a theoretic risk of erosion into the bladder (**Fig. 9**).



**Fig. 8.** An assistant grasps the knot to prevent slippage to secure the first square knot flush with the anterior cervix.



**Fig. 9.** The free ends of the tied Mersilene tape have been secured with silk suture.

Next, the overlying vesicouterine peritoneum is closed with 2 to 0 Monocryl suture using intracorporal knot tying (**Fig. 10**).

Finally, all instruments are removed from the abdomen and pelvis, and port sites are closed.

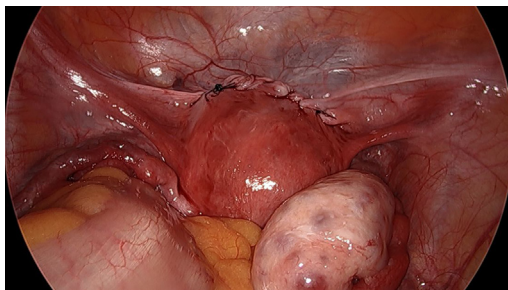
Significant bleeding or severe complications are rarely encountered.<sup>11</sup> In the case of oozing from the uterine vein, this will often resolve once the Mersilene stitch is tied down. Persistent bleeding even after securing the cerclage may require additional placement of a simple figure of 8 stitches (Monocryl or Vicryl) at the posterior insertion of the tape to obtain hemostasis.

#### **POSTOPERATIVE COURSE**

Due to the advantages of a minimally invasive surgical approach, patients can undergo laparoscopic abdominal cerclage as an outpatient procedure, without the need for overnight hospital admission. Pain is controlled adequately with nonnarcotic medications including ibuprofen and acetaminophen. Postoperative restrictions include performing activities as tolerated, with recommendations for 2 weeks of pelvic rest. Most patients experience a return to baseline function within 1 to 2 weeks. Patients may begin attempts at conception 2 months after laparoscopic abdominal cerclage placement. We recommend that they receive obstetric care as high-risk patients.

#### **WHEN TO REMOVE AN ABDOMINAL CERCLAGE**

Abdominal cerclages can be removed at the time of cesarean delivery if the patient has completed her childbearing. If the patient is still considering future childbearing, the cerclage can be left in place for future pregnancies. In the event of a miscarriage,



**Fig. 10.** The anterior vesicouterine peritoneum has been closed.



a dilation and curettage procedure can be performed with the abdominal cerclage in place up to 18 weeks of gestation.<sup>18</sup> For more advanced gestational ages, hysterotomy may be necessary if the patient desires to keep the cerclage, or laparoscopic removal of the cerclage can be performed to allow for the vaginal passage of the fetus.

## CLINICAL OUTCOMES

As with all surgical procedures, technical skill and surgeon experience are important factors for successful patient outcomes. At the Brigham & Women's Hospital in Boston, we have been performing abdominal cerclages for more than 20 years and were one of the first centers in the United States to offer a laparoscopic, minimally invasive approach to placement. Since 2007, we have performed more than 150 laparoscopic abdominal cerclage placements. Most of these patients had at least one prior second-trimester loss (many of them had multiple losses), with many having also failed a transvaginal cerclage (Table 1). In an analysis of 169 of these cases, the neonatal survival rate was 96.9% in the 98 pregnancies that followed and extended beyond the first trimester, and the mean gestational age at delivery was 37.0 weeks (first trimester losses are typically excluded from the denominator because they are unlikely to be the result of cervical insufficiency).<sup>11</sup>

<b>Table 1</b>	
<b>Laparoscopic abdominal cerclage in 169 patients at the Brigham &amp; Women's Hospital in Boston, Massachusetts</b>	
<b>Parameters</b>	<b>Values</b>
<b>Patient Characteristics (n = 169)</b>	
Mean Age (y) <sup>a</sup>	34.9 ± 4.5
<b>History</b>	
First Trimester Loss	77 (45.6%)
Second-Trimester Loss	125 (45.6%)
Third Trimester Loss	6 (3.6%)
Previous Transvaginal Cerclage	112 (66.3%)
Cervical Surgery or Injury	104 (61.5%)
<b>Procedural Outcomes (n = 169)</b>	
Mean Operative Time (min) <sup>a</sup>	
All Cases	61 ± 36
No Additional Procedures	49 ± 25
Mean Estimated Blood Loss (mL) <sup>a</sup>	
All Cases	23 ± 20
No Additional Procedures	17 ± 11
<b>Complications</b>	
Same-day Discharge	163 (96.4%)
<b>Obstetric Outcomes (n = 98)</b>	
Neonatal Survival Rate <sup>b</sup>	96 (96.9%)
Mean Gestational Age (wk) <sup>a</sup>	37.0 ± 1.3
Mean Birth Weight (g) <sup>a</sup>	2963 ± 459

<sup>a</sup> Mean ± standard deviation.

<sup>b</sup> Neonates surviving until hospital discharge.

## SUMMARY

Laparoscopic abdominal cerclage is a minimally invasive, highly effective surgical treatment of patients with refractory cervical insufficiency or anatomic limitations to vaginal cerclage placement. The laparoscopic abdominal technique has demonstrated similar or improved neonatal survival rates compared with the more invasive, historically performed open approach.

## CLINICS CARE POINTS

- Cervical insufficiency is a well-established cause of infant morbidity and mortality
- Cervical cerclage placement is the recommended treatment of women with cervical insufficiency
- Cerclages can be placed transvaginally or transabdominally
- Women with anatomic limitations to vaginal cerclage placement or prior failed vaginal cerclages should be offered transabdominal cerclage placement
- Abdominal cerclage requires cesarean delivery
- Abdominal cerclage is the preferred approach for patients with cervical insufficiency and a prior failed vaginal cerclage gave improved birth outcomes compared with repeat transvaginal placement
- Benefits of abdominal cerclages compared with vaginal cerclages include a more proximal placement at the level of the internal os, greater mechanical support to the cervix, decreased risk of caudal suture migration with the progression of pregnancy, and possible reduced risk of ascending intrauterine infections due to the absence of foreign body material in the vagina
- Laparoscopic abdominal cerclage is the preferred approach compared with laparotomy
- Benefits of laparoscopic approach includes smaller incisions, faster postoperative healing, reduced risk of postoperative wound infections, quicker return to baseline function, less blood loss, and ability to undergo outpatient surgery
- Laparoscopic cerclages are ideally placed before conception but can be placed up to the early second trimester of pregnancy
- Patients with abdominal cerclage should receive obstetric care as high-risk patients
- Abdominal cerclages can be removed during cesarean delivery if the patient has completed childbearing, otherwise it can be left in place for pregnancies
- Dilation and curettage can be performed through abdominal cerclage placement up to 18 weeks of gestation
- Neonatal survival rates more than 96% and mean gestational age of 37 weeks at delivery have been observed in subsequent pregnancies with laparoscopic abdominal cerclage in place
- Laparoscopic abdominal cerclage is a highly effective, well-tolerated surgical treatment of refractory cervical insufficiency or anatomic limitations to vaginal cerclage placement

## DISCLOSURE

S. Gupta has nothing to disclose; J.I. Einarsson is a consultant for Olympus, Hologic and Arthrex.

## REFERENCES

1. Thakur M, Mahajan K. Cervical incompetence. StatPearls; 2021. Available at: <https://www.ncbi.nlm.nih.gov/books/NBK525954/>.

2. American College of Obstetricians and Gynecologists. ACOG Practice Bulletin No. 142: Cerclage for the management of cervical insufficiency. *Obstet Gynecol* 2014;123:372–9.
3. Leduc L, Wasserstrum N. Successful treatment with the Smith-Hodge pessary of cervical incompetence due to defective connective tissue in Ehlers-Danlos syndrome. *Am J Perinatol* 1992;9(1):25.
4. Shirodkar V. A new method of operative treatment of habitual abortions in the second trimester of pregnancy. *Antiseptic* 1955;52:299–300.
5. McDonald IA. Suture of the cervix for inevitable miscarriage. *J Obstet Gynaecol Br Emp* 1957;64(3):346–50.
6. Harger JH. Cerclage and cervical insufficiency: an evidence-based analysis. *Obstet Gynecol* 2002;100:1313.
7. Berghella V, Szychowski JM, Owen J, et al. Suture type and ultrasound-indicated cerclage efficacy. Vaginal ultrasound trial consortium. *J Matern Fetal Neonatal Med* 2012;25:2287–90.
8. Benson RC, Durfee RB. Transabdominal cervicouterine cerclage during pregnancy for the treatment of cervical incompetency. *Obstet Gynecol* 1965;25:145–55.
9. Lesser KB, Childers JM, Surwit EA. *Obstet Gynecol.* 1998;91:855–6.
10. Witt MU, Joy SD, Clark J, et al. Cervicoisthmic cerclage: transabdominal vs transvaginal approach. *Am J Obstet Gynecol* 2009;201(1):105.e1–1054.
11. Clark N, Einarsson J. Laparoscopic abdominal cerclage: a highly effective option for refractory cervical insufficiency. *Fertil Steril* 2020. <https://doi.org/10.1016/j.fertnstert.2020.02.007>.
12. Shennan A, Chandiramani M, Bennett P, et al. MAVRIC: a multicentre randomised controlled trial of transabdominal versus transvaginal cervical cerclage. *Am J Obstet Gynecol* 2020;222(3):261.e1–9.
13. Ari S, Akdemir A, Sendag F. Transabdominal cervical cerclage. Non-obstetric surgery during pregnancy. Springer; 2019. p. 355–60.
14. Medeiros LR, Stein AT, Fachel J, et al. Laparoscopy versus laparotomy for benign ovarian tumor: a systematic review and meta-analysis. *Int J Gynecol Cancer* 2008;18(3):387–99.
15. Moawad GN, Tyan P, Bracke T, et al. Systematic review of transabdominal cerclage placed via laparoscopy for the prevention of preterm birth. *J Minim Invasive Gynecol* 2018;25:277–86.
16. Dawood F, Farquharson RG. Transabdominal cerclage: preconceptional versus first trimester insertion. *Eur J Obstet Gynecol Reprod Biol* 2016;199:27–31.
17. Vousden NJ, Carter J, Seed PT, et al. What is the impact of preconception abdominal cerclage on fertility: evidence from a randomized controlled trial. *Acta Obstet Gynecol Scand* 2017;96(5):543–6.
18. Chandiramani M, Chappell L, Radford S, et al. Successful pregnancy following mid-trimester evacuation through a transabdominal cervical cerclage. *BMJ Case Rep* 2011. <https://doi.org/10.1136/bcr.02.2011.3841>. bcr0220113841.