

# Diagnostic, Therapeutic, and Prognostic Implications of the 2021 World Health Organization Classification of Tumors of the Central Nervous System

Simon Gritsch, DrMed, MD<sup>1</sup>; Tracy T. Batchelor, MD<sup>2,3</sup>; and L. Nicolas Gonzalez Castro, MD, PhD <sup>1,2,3</sup>

The 2016 revised fourth edition of the World Health Organization (WHO) classification of central nervous system (CNS) tumors incorporated molecular features with histologic grading, revolutionizing how oncologists conceptualize primary brain and spinal cord tumors as well as providing new insights into their management and prognosis. The 2021 revised fifth edition of the WHO classification further integrates molecular alterations for CNS tumor categorization, updating current understanding of the pathophysiology of many of these disease entities. Here, the authors review changes in the new classification for the most common primary adult tumors—gliomas (including astrocytomas, oligodendrogliomas, and ependymomas) and meningiomas—highlighting the key genomic alterations for each group classification to help clinicians interpret them as they consider therapeutic options—including clinical trials and targeted therapies—and discuss the prognosis of these tumors with their patients. The revised, updated 2021 WHO classification also further integrates molecular alterations in the classification of pediatric CNS tumors, but those are not covered in the current review. **Cancer 2022;128:47-58.** © 2021 American Cancer Society.

**KEYWORDS:** 2021 World Health Organization (WHO) central nervous system (CNS) tumor classification, glioblastoma, glioma, isocitrate dehydrogenase (*IDH*)-mutant gliomas, meningiomas.

## INTRODUCTION

Advances in cancer genomics have greatly enhanced our understanding of the molecular alterations underlying central nervous system (CNS) tumor biology. The multitude of genetic alterations observed in CNS tumors include base substitutions, insertions and deletions, copy number alterations, and gene rearrangements. Genes commonly affected include those encoding for receptor tyrosine kinases and their downstream signaling partners (epidermal growth factor receptor [*EGFR*], platelet-derived growth factor receptor  $\alpha$  [*PDGFRA*], Met tyrosine-protein kinase [*MET*], V-raf murine sarcoma viral oncogene homolog B [*BRAF*], phosphoinositide 3-kinase [*PI3K*]), cell cycle regulation (*p53*, cyclin-dependent kinase inhibitors 2A and 2B [*CDKN2A/B*], cyclin-dependent kinase 4 [*CDK4*], retinoblastoma susceptibility gene [*RBI*]), telomere maintenance (telomerase reverse transcriptase [*TERT*],  $\alpha$ -thalassemia mental retardation X-linked [*ATRX*]), and chromatin organization (isocitrate dehydrogenase [*IDH*], histone mutations, and epigenetic modifications). The identification of these cancer-specific molecular alterations and the deeper understanding of their effects on tumor biology have translated into improved diagnosis, classification, and more accurate prognosis of most CNS tumors, transforming clinical practice.

Although the classification of CNS tumors historically was based on histologic features only,<sup>1</sup> advances in our understanding of the molecular features of CNS tumors has led to the incorporation of molecular alterations into the diagnostic criteria.<sup>2</sup> The emergence of effective and experimental molecular therapies targeting some cancer-specific genetic events provides another rationale for the inclusion of molecular alterations in disease classification. Recent successes in targeting the *BRAF* V600E mutation in melanoma<sup>3</sup> and craniopharyngioma<sup>4-6</sup>; *EGFR* mutations, *K-RAS* mutations, and anaplastic lymphoma kinase (*ALK*) rearrangements in nonsmall cell lung cancer<sup>7,8</sup>; human epidermal growth factor receptor 2 (*HER2*) amplification in breast cancer<sup>9</sup>; and the breakpoint cluster region protein/tyrosine-protein kinase ABL (*BCR-ABL*) translocation in chronic myeloid leukemia<sup>10</sup> have validated the targeted approach to cancer therapy. In CNS tumors, there are fewer but some notable successes with approvals of everolimus for subependymal giant cell astrocytoma in patients with tuberous sclerosis,<sup>11</sup> selumetinib for plexiform neurofibromas in patients with neurofibromatosis type 1,<sup>12</sup> and larotrectinib for neurotrophic tyrosine receptor kinase (NTRK)-altered tumors, including CNS neoplasms.<sup>13-15</sup> Molecular classification is also highly relevant because many patients with CNS tumors are now considered for inclusion

**Corresponding Author:** L. Nicolas Gonzalez Castro, MD, PhD, Center for Neuro-Oncology, Dana-Farber Cancer Institute, 450 Brookline Avenue, Boston, MA 02215 (lgonzalez-castro@dfci.harvard.edu).

<sup>1</sup>Cancer Center, Massachusetts General Hospital, Harvard Medical School, Boston, Massachusetts; <sup>2</sup>Department of Neurology, Brigham and Women's Hospital, Harvard Medical School, Boston, Massachusetts; <sup>3</sup>Center for Neuro-Oncology, Dana-Farber Cancer Institute, Harvard Medical School, Boston, Massachusetts

**DOI:** 10.1002/cncr.33918, **Received:** July 12, 2021; **Revised:** August 16, 2021; **Accepted:** August 17, 2021, **Published online** October 11, 2021 in Wiley Online Library (wileyonlinelibrary.com)

in clinical trials of targeted drugs based on the genetic profile of the underlying tumor.<sup>16</sup>

Therefore, an accurate classification system that takes into consideration the molecular characteristics of CNS tumors is paramount for accurate diagnosis, prognosis, treatment selection, and enrollment into relevant clinical trials. The 2016 World Health Organization (WHO) classification of CNS tumors<sup>2</sup> for the first time integrated molecular characteristics and histologic features to facilitate a more precise classification of these tumors. This has led to disease classes with entities that are more homogeneous not only in their biology but also in their response to treatment and clinical outcomes. Despite this progress, there is still need for further refinement, especially for rare and poorly characterized tumor entities.

Since publication of the 2016 WHO classification of CNS tumors, there has been additional progress in our understanding of the underlying biology of many of these tumor entities. Several of these discoveries have important implications for tumor classification, patient care, and the design and interpretation of clinical trials. To communicate these findings in advance of the 2021 WHO classification of CNS tumors, a group of leading neuropathologists and neuro-oncologists formed the Consortium to Inform Molecular and Practical Approaches to CNS Tumor Taxonomy—Not Official WHO (cIMPACT-NOW).<sup>17-24</sup> Since its inception, cIMPACT-NOW has published several recommendations for incorporation into clinical practice.<sup>17-24</sup> These updates<sup>17-24</sup> form the basis for the updated 2021 WHO classification of CNS tumors.<sup>17-25</sup>

Here, we review key updates in the 2021 WHO classification of CNS tumors for the most common primary adult tumors—gliomas and meningiomas<sup>26,27</sup>—highlighting important implications for clinical practice and providing clinicians with a framework to help them interpret the new classification as they consider therapeutic options (clinical trials, targeted therapies) and discuss prognosis with their patients.

## GENERAL UPDATES IN THE NEW CLASSIFICATION

The 2021 WHO classification adds several newly recognized tumor types (see Table 1) and makes several important changes to principles relating to nomenclature, grading, and classification of CNS tumors.<sup>25</sup> Many of these changes increase the reliance on molecular alterations for disease classification and elevate the importance of molecular testing. Importantly, in some cases, molecular subgrouping has been shown to be superior to histopathologic grading for

**TABLE 1.** New Entities Included in the 2021 World Health Organization Classification of Tumors of the Central Nervous System, Fifth Edition

Gliomas	Diffuse astrocytoma, <i>MYB</i> or <i>MYBL1</i> altered
	Polymorphous low-grade neuroepithelial tumor of the young
	Diffuse low-grade glioma, <i>MAPK</i> pathway altered
	Diffuse hemispheric glioma, H3.3 G34 mutant
	Diffuse pediatric-type high-grade glioma, H3-wildtype and <i>IDH</i> -wildtype
	Infant-type hemispheric glioma
	High-grade astrocytoma with piloid features
Glioneuronal tumors	Diffuse glioneuronal tumor with oligodendroglioma-like features and nuclear clusters
	Myxoid glioneuronal tumor
	Multinodular and vacuolating neuronal tumor
Ependymomas	Supratentorial ependymoma, <i>YAP1</i> fusion-positive
	Posterior fossa ependymoma, PFA
Embryonal tumors	Posterior fossa ependymoma, PFB
	Spinal ependymoma, <i>MYCN</i> -amplified
	Cribiform neuroepithelial tumor
	CNS neuroblastoma, <i>FOXR2</i> -activated
	CNS tumor with <i>BCOR</i> internal tandem duplication
Sarcomatous neoplasms	Desmoplastic myxoid tumor, <i>SMARCB1</i> -mutant
	Angiomatoid fibrous histiocytoma/intracranial myxoid mesenchymal tumor
	<i>CIC</i> -rearranged sarcoma
	Primary intracranial sarcoma, <i>DICER1</i> -mutant
Pituitary tumors	Pituitary blastoma

Abbreviations: *BCOR*, BCL-6 corepressor; *CIC*, Capicua transcriptional repressor; CNS, central nervous system; *IDH*, isocitrate dehydrogenase; *MAPK*, mitogen-activated protein kinase; *MYCN*, N-Myc; PFA, posterior fossa group A; PFB, posterior fossa group B; *SMARCB1*, switch/sucrose non-fermentable (SWI/SNF)-related matrix-associated actin-dependent regulator of chromatin subfamily B member 1; *YAP1*, yes-associated protein 1.

risk stratification (eg, diffuse astrocytomas, ependymomas), and molecular markers now prevail over histopathology in some of the specific cases outlined in this article.

Methylome profiling has emerged as a powerful tool for the classification and diagnosis of CNS tumors.<sup>19,28-30</sup> The 2021 WHO classification endorses methylome classifiers for many CNS tumor types and subtypes, but uncertainty about the optimal methodological approach and limited diagnostic test availability make it difficult to recommend methylome profiling as a primary or routine diagnostic test for tumor classification. In addition, most CNS tumor types and subtypes can be reliably diagnosed by established, widely available techniques (eg, by integrating histology with signature genetic alterations). A notable exception is high-grade astrocytoma with piloid

**TABLE 2.** Important Molecular Tests to Establish the Diagnosis and Prognosis of Common Tumor Entities

Gliomas	Glioblastoma
	1. If initial evaluation is consistent with an <i>IDH</i> wild-type astrocytoma without high-grade features, perform next-generation sequencing and copy number profile to evaluate for: <ul style="list-style-type: none"> <li>• <i>EGFR</i> amplification</li> <li>• <i>TERT</i> promoter mutation</li> <li>• Concurrent gain of chromosome 7, loss of chromosome 10</li> </ul>
	The presence of any of these molecular alterations establishes the diagnosis of glioblastoma, CNS WHO grade 4, despite the absence of high-grade features on histology
	2. In the presence of a diagnosis of glioblastoma, CNS WHO grade 4, evaluate for methylation of the <i>MGMT</i> gene promoter; <i>MGMT</i> promoter methylation is associated with improved response to treatment with temozolomide and longer overall survival
	<i>IDH</i> -mutant astrocytic gliomas
	1. The diagnosis of diffuse astrocytoma, <i>IDH</i> -mutant can be established using <i>ATRX</i> and/or <i>P53</i> expression as surrogate immunohistochemical markers of the absence of 1p/19 codeletion
	2. In the presence of a diagnosis of diffuse astrocytoma, <i>IDH</i> -mutant, evaluate for homozygous <i>CDKN2A/B</i> deletion using next-generation sequencing or fluorescent in situ hybridization because the presence of this molecular alteration makes the tumor grade 4, irrespective of the absence of high-grade features on histology
	Ependymomas
	1. Posterior fossa (PF) ependymomas can be classified as type A or type B based on the absence (PFA) or presence (PFB) of H3 K27me3 staining on tumor cell nuclei
	2. Gain of chromosome 1q in PFA ependymomas is associated with worse prognosis
	Meningiomas
	Anaplastic meningioma
	1. Consider next-generation sequencing of a meningioma, CNS WHO grade 2, as the presence of a <i>TERT</i> promoter mutation or homozygous <i>CDKN2A/B</i> deletion would establish the diagnosis of anaplastic meningioma, CNS WHO grade 3, even in the absence of anaplastic features on histology

Abbreviations: *ATRX*,  $\alpha$ -thalassemia mental retardation X-linked; *CDKN2A/B*, cyclin-dependent kinase inhibitor 2A/B; CNS, central nervous system; *EGFR*, epidermal growth factor receptor; *IDH*, isocitrate dehydrogenase; *MGMT*, O-6-methylguanine-DNA methyltransferase; *TERT*, telomerase reverse transcriptase; WHO, World Health Organization.

features, a new entity that has been added in the 2021 WHO classification and requires methylome profiling for diagnosis. However, this is a rare entity, and the use of methylome classifiers remains most effective in selected cases with unusual clinicopathologic presentation. A practical list of important testing for many of the tumor types discussed in this article is included in Table 2.

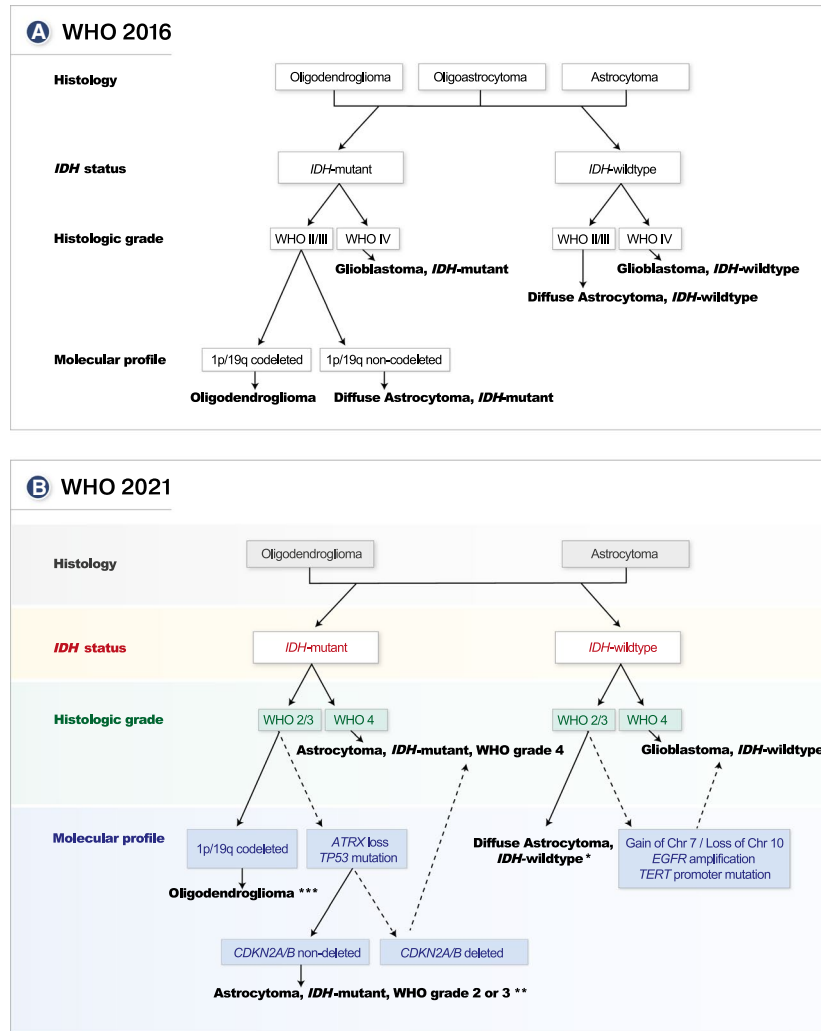
Finally, the abbreviation CNS is now included in the designation of tumor grades in the 2021 WHO classification of tumors of the CNS (eg, glioblastoma, CNS WHO grade 4). This change emphasizes differences in grading criteria of CNS tumors compared with grading criteria of tumors in other organ systems. In addition, the 2021 WHO classification has moved from Roman numerals (I, II, III, IV) to Arabic numerals (1, 2, 3, 4) for denoting tumor grades. Tumor *entities* are now referred to as tumor *types*, whereas *variants* are referred to as *subtypes*. These changes decrease the risk for typographical errors and align the nomenclature of CNS tumors with the nomenclature of tumors in other organ systems. Previous editions of the WHO classification of tumors of the CNS assigned 1 tumor grade to each entity (eg, anaplastic astrocytoma was grade III according to the definition and could not be assigned grade I, II, or IV). In contrast, the 2021 WHO classification has moved to a *within-tumor-type* grading system for most tumor types. For example, astrocytoma, *IDH*-mutant, can now be either grade 2, 3, or 4, and the term anaplastic is no longer used for grade 3 tumors.

## MAJOR UPDATES BY TUMOR GROUP

### *Diffuse Gliomas*

Diffuse gliomas are the most common primary brain tumors, with a clinical course that remains invariably fatal. The WHO 2016 classification of CNS tumors for the first time integrated histopathology with molecular features, marking an important paradigm shift in the classification of gliomas.<sup>2</sup> For adult diffuse gliomas, it defined the following 3 main categories based on histopathology, mutational spectrum, and copy number alterations: 1) astrocytic, *IDH*-wildtype tumors, including diffuse astrocytoma (grade II), anaplastic astrocytoma (grade III), and primary glioblastoma (grade IV); 2) astrocytic, *IDH*-mutant tumors, including diffuse astrocytoma (grade II), anaplastic astrocytoma (grade III), and secondary glioblastoma (grade IV); and 3) oligodendroglial, *IDH*-mutant tumors and tumors with codeletion of the short arm of chromosome 1 and the long arm of chromosome 19 (1p/19q), including diffuse oligodendroglioma (grade II) and anaplastic oligodendroglioma (grade III).

The 2021 WHO classification incorporates additional insights from genomic studies,<sup>25,31-33</sup> making several changes regarding diagnostic principles and nomenclature of diffuse gliomas, with important implications for clinical practice and for the design and interpretation of clinical trials. Clinically impactful changes include the addition of molecular criteria for the diagnosis of glioblastoma, *IDH*-wildtype, or astrocytoma, *IDH*-mutant,



**Figure 1.** The classification of diffuse gliomas is illustrated based on histologic and molecular features, including (A) a simplified diagnostic algorithm based on the 2016 edition of the World Health Organization (WHO) classification of central nervous system (CNS) tumors, integrating molecular characteristics and histologic features, and (B) a simplified algorithm based on the 2021 WHO classification of CNS tumors. Dashed lines in B denote changes compared with the 2016 WHO classification. \*Diffuse astrocytoma, isocitrate dehydrogenase (*IDH*)-wildtype without molecular features of glioblastoma, is a rare entity. Molecular testing for gain of chromosome (Chr) 7 and loss of Chr 10, epidermal growth factor receptor (*EGFR*) amplification, and telomerase reverse transcriptase (*TERT*) promoter is required to exclude glioblastoma, *IDH*-wildtype, grade 4. In the absence of molecular features of glioblastoma, additional testing should be considered (eg, v-Raf murine sarcoma viral oncogene homolog B [*BRAF*] alterations, histone mutations, methylome profiling). \*\*Astrocytoma, *IDH*-mutant, can be diagnosed as grade 2, 3, or 4 based on histopathologic grading criteria and cyclin-dependent kinase inhibitor 2A/cyclin-dependent kinase inhibitor 2B (*CDKN2A/B*) status. \*\*\*Oligodendroglioma, *IDH*-mutant with codeletion of the short arm of chromosome 1 and the long arm of chromosome (1p19q), can be diagnosed as grade 2 or 3 based on histopathologic features. *ATRX* indicates  $\alpha$ -thalassemia mental retardation X-linked.

grade 4, even in the absence of histopathologic high-grade features. The details of these changes are discussed in the tumor type-specific sections below, and a simplified algorithm for the classification of diffuse gliomas is presented in Figure 1.

**Glioblastoma**

Glioblastomas, CNS WHO grade 4, are highly malignant tumors that occur most commonly in elderly patients

(median age at diagnosis, 65 years) and are characterized by rapid progression and a poor prognosis (median overall survival, 16-18 months).<sup>27</sup> Histologically, glioblastomas are characterized by prominent cellular and nuclear atypia, frequent mitotic figures, areas of necrosis, and vascular proliferation. At a molecular level, glioblastomas demonstrate a striking degree of intratumoral heterogeneity.<sup>34-37</sup> Recurrent, signature genetic events include gain of chromosome 7 and loss of chromosome

10 (+7/–10)<sup>38</sup>; amplification and rearrangement of receptor tyrosine kinases, most commonly affecting *EGFR* (approximately 50%)<sup>39</sup>; alterations in the p53 pathway<sup>39</sup>; mutations or deletion of phosphatase and tensin homolog (*PTEN*) (approximately 40%)<sup>39</sup>; and aberrant telomere maintenance through *TERT* promoter mutations (approximately 80%).<sup>39,40</sup>

The WHO 2016 classification conceptualized primary glioblastoma (diffuse astrocytoma, *IDH*-wildtype, grade IV) as a tumor that develops rapidly de novo without a known precursor lesion and thus as a disease entity distinct from grade II diffuse astrocytoma, *IDH*-wildtype. The grading of diffuse astrocytoma, *IDH*-wildtype as a WHO grade IV tumor (glioblastoma) was primarily based on the presence of histopathologic high-grade features (necrosis and/or microvascular proliferation). However, increasing insights into the molecular characteristics of primary glioblastoma have challenged this view. Genomic studies reveal that the overwhelming majority of grade II and III diffuse astrocytomas, *IDH*-wildtype, share signature genomic alterations and very similar clinical outcomes with primary glioblastoma, grade IV.<sup>32</sup> This suggests that these tumors represent under-sampled glioblastomas. Consistent with this notion, one study revealed that the presence of either +7/–10, *EGFR* amplification, and/or *TERT* promoter mutation in histopathologic grade II or III *IDH*-wildtype diffuse astrocytic gliomas carries a prognosis that is the same as that of histologically diagnosed glioblastoma.<sup>31</sup> The 2021 WHO classification accounts for these new insights by stipulating *molecular* criteria that allow for a diagnosis of glioblastoma, CNS WHO grade 4, in *IDH*-wildtype astrocytic gliomas, even in the absence of high-grade histopathologic features, when at least one of the following molecular features is present: concurrent +7/–10, *EGFR* amplification, or *TERT* promoter mutation.<sup>19,21</sup> This change has important implications for prognosis and therapy of these tumors and highlights the importance of molecular analysis for CNS WHO grade 2 or 3 diffuse astrocytic, *IDH*-wildtype gliomas. Diffuse astrocytoma, *IDH*-wildtype, CNS WHO grade 2 or 3, without molecular features of glioblastoma is a rare entity and is no longer considered a tumor type in the 2021 WHO classification.<sup>26</sup> The absence of molecular features of glioblastoma should prompt additional molecular testing (eg, *BRAF* alterations, histone mutations, methylome profiling) to arrive at a specific diagnosis.

### **Astrocytomas, *IDH*-Mutant**

*IDH*-mutant diffuse gliomas, encompassing astrocytomas and oligodendrogliomas, are characterized by a

class-defining and possibly tumor-initiating clonal *IDH1* or (less commonly) *IDH2* gene mutation.<sup>41,42</sup> *IDH* mutations confer a neomorphic enzymatic activity,<sup>43</sup> leading to changes in cellular metabolism<sup>44–47</sup> and the accumulation of the oncometabolite 2-hydroxyglutarate.<sup>48</sup> 2-Hydroxyglutarate accumulation has been shown to promote tumorigenesis by competitively inhibiting  $\alpha$ -ketoglutarate-dependent dioxygenases, which include histone lysine demethylases and DNA demethylases.<sup>49,50</sup> This results in histone and DNA hypermethylation with a CpG island methylator phenotype pattern, leading to a change in the cellular epigenetic status and a block of cellular differentiation.<sup>51–55</sup> *IDH*-mutant gliomas originate as low-grade tumors, and their development is characterized by the progressive accumulation of additional genetic alterations accompanied by a progressive increase in tumor grade.<sup>46,56,57</sup> In the overwhelming majority of diffuse astrocytomas, an *IDH* mutation is associated with loss-of-function mutations in tumor protein 53 (*TP53*) and *ATRX* (approximately 90%),<sup>58,59</sup> the latter of which is responsible for an abnormal telomere maintenance mechanism known as alternative lengthening of telomeres.<sup>60</sup> *ATRX* mutations are mutually exclusive with 1p/19q codeletion, the class-defining molecular alteration of oligodendrogliomas.<sup>61</sup> Oligodendrogliomas achieve telomere maintenance by distinct mechanisms, most commonly through an activating mutation of the *TERT* gene (approximately 90%).<sup>62</sup>

The 2021 WHO classification incorporates these distinct molecular characteristics of *IDH*-mutant astrocytoma and oligodendroglioma to allow for additional ways for obtaining a diagnosis of diffuse astrocytoma, *IDH*-mutant. The 2016 WHO classification required the presence of an *IDH1* or *IDH2* mutation as well as the absence of 1p/19q codeletion to make the diagnosis of *IDH*-mutant diffuse astrocytoma. According to the 2021 WHO classification, this diagnosis can now also be made in the absence of 1p/19q testing if there is evidence of loss of *ATRX* and/or *TP53* mutations.<sup>23</sup>

Oligodendrogliomas have the most favorable prognosis of diffuse gliomas and are responsive to chemotherapy.<sup>32</sup> Diffuse astrocytomas, *IDH*-mutant, also have a more favorable prognosis compared with *IDH*-wildtype diffuse gliomas.<sup>32,63</sup> However, there is significant heterogeneity in the prognosis of this disease class that is not fully resolved by the histopathologically defined tumor grades of the 2016 WHO classification. Studies have identified homozygous deletion of *CDKN2A/B* as a critical, independent, negative prognostic factor in *IDH*-mutant astrocytoma.<sup>33,64,65</sup>

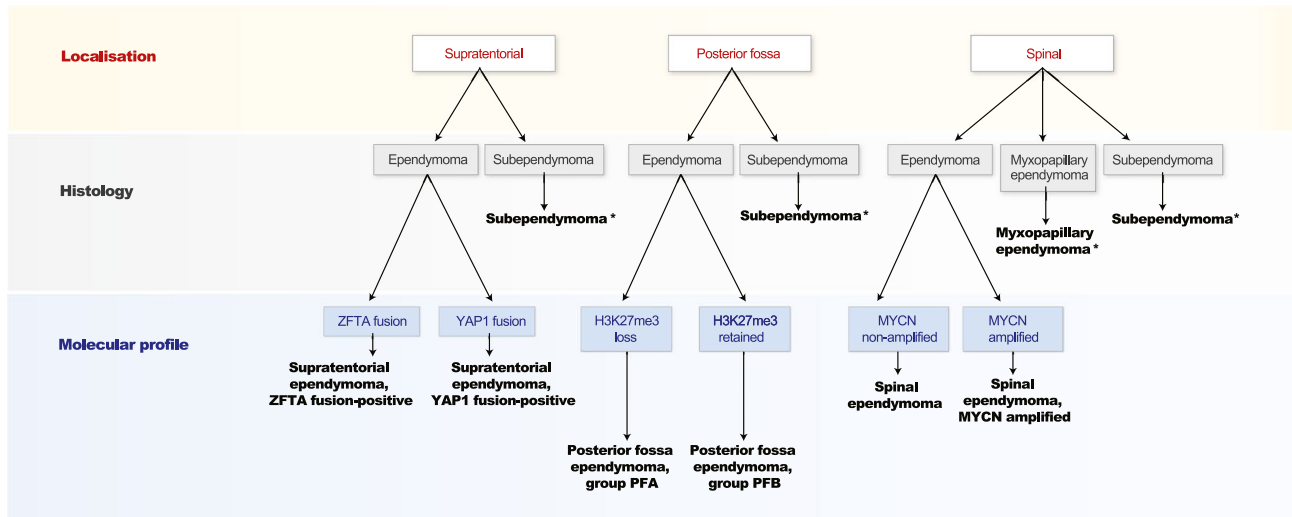
The 2021 WHO classification accounts for these findings by integrating histopathologic criteria with *CDKN2A/B* status to achieve more precise grading of diffuse *IDH*-mutant astrocytomas. *IDH*-mutant diffuse astrocytoma grade 2 can now only be diagnosed in the absence of the following: anaplastic histopathologic elements, significant mitotic activity, and homozygous *CDKN2A/B* deletion. *IDH*-mutant diffuse astrocytoma grade 3 is diagnosed if anaplastic features and significant mitotic activity are present but *CDKN2A/B* deletion is absent. A CNS WHO grade 4 diagnosis now requires the presence of histopathologic high-grade features (microvascular proliferation/necrosis) and/or homozygous *CDKN2A/B* deletion. The highest grade of an *IDH*-mutant astrocytoma is astrocytoma, *IDH*-mutant, CNS WHO grade 4 and differentiates this class from glioblastoma, CNS WHO grade 4, which carries a worse prognosis. Testing for homozygous *CDKN2A/B* deletion is critical for accurate diagnosis and to inform prognosis and optimal counseling in patients with diffuse astrocytoma, *IDH*-mutant. Currently, the standard of care for astrocytoma, *IDH*-mutant, CNS WHO grade 4 with *CDKN2A/B* deletion remains unchanged from that of other high-grade gliomas.<sup>16</sup> Future clinical trials should leverage molecular alterations established in the 2021 WHO classification to identify optimal therapeutic strategies for molecular subgroups and allocate patients to novel, targeted treatments. So far, targeted therapeutic strategies in *IDH*-mutant gliomas have focused mainly on targeting the mutated *IDH* protein<sup>66-68</sup> or alterations in cellular physiology resulting from the mutant *IDH* neomorphic enzymatic activity.<sup>69</sup> Homozygous *CDKN2A/B* deletion itself may offer an additional target for inhibitors of the *CDK4/CDK6* axis. Several *CDK4/CDK6* inhibitors have been approved for the treatment of hormone receptor-positive, metastatic breast cancer.<sup>70</sup> In gliomas, results from preclinical studies with these agents have been encouraging,<sup>71,72</sup> and ongoing clinical trials are investigating the *CDK4/CDK6* inhibitor palbociclib as a possible targeted treatment in diffuse gliomas.<sup>73</sup>

Recently, radiotherapy has been linked to a genomic deletion signature contributing to poor outcomes in patients with gliomas.<sup>74</sup> In *IDH*-mutant gliomas, radiotherapy was associated with acquired *CDKN2A* deletion at recurrence, which was linked to worse survival. This is especially significant given the important role of *CDKN2A/B* deletions for tumor classification and prognosis in the 2021 WHO classification of CNS tumors. Clinical trials have demonstrated a survival benefit of radiation and chemotherapy in newly diagnosed, low-grade

gliomas compared with radiotherapy alone.<sup>75</sup> Clinical data for initial treatment with chemotherapy alone are more limited, but the available data support increased survival with a combination of radiotherapy and chemotherapy.<sup>76-79</sup> Additional clinical trials are needed to identify subsets of patients who can be safely treated with single-modality treatment.

### **Ependymomas**

Ependymomas are a heterogeneous group of well circumscribed gliomas with ependymal features. These CNS tumors occur in the brain or spinal cord in both adults and children. Since 2015, molecular subgrouping of these tumors has been shown to be superior to histopathologic grading for risk stratification.<sup>80</sup> This was recognized in the 2016 WHO classification of CNS tumors but was not fully incorporated into the diagnostic criteria, which relied on histopathologic features.<sup>2</sup> However, ependymomas demonstrate significant heterogeneity in their clinical course and molecular features that is not satisfactorily resolved by these primarily morphologically defined groups. In addition, histopathologic tumor grading correlates poorly with clinical prognosis in ependymomas,<sup>81</sup> limiting the clinical utility of this classification system. Finally, methylome profiling and genomic studies have revealed at least 9 molecular subgroups of ependymoma that are characterized by distinct molecular alterations, have unique clinical features, and correlate with the 3 main anatomic sites of the tumor within the CNS: supratentorial brain (ST), posterior fossa brain (PF), and spinal cord (SC).<sup>80,82-86</sup> The 2021 WHO classification of CNS tumors incorporates these findings to establish a new classification system for ependymomas that is based on anatomic site (ST, PF, and SC) and molecular features. A simplified algorithm for the classification of ependymomas based on localization, histology, and molecular features is presented in Figure 2. For each anatomic site, there are 3 main groups based on the underlying epigenetic and genetic characteristics, with 1 group at each site corresponding histopathologically to superependymoma.<sup>80</sup> The other two ST ependymoma molecular groups are defined by their recurrent genetic alterations into: 1) ST ependymomas with *ZFTA* (zinc finger translocation associated; formerly *c11orf95* [chromosome 11 open reading frame 95]) gene fusions (formerly ependymoma, *RELA* [v-rel reticuloendotheliosis viral oncogene homolog A] fusion-positive), and 2) ST ependymomas with yes-associated protein 1 (*YAPI*) gene fusions.<sup>87,88</sup> Because there are insufficient data to assign a WHO grade to ST ependymoma based on the molecular



**Figure 2.** The classification system for ependymomas is illustrated based on anatomic site, histology, and molecular features, with a simplified algorithm based on the 2021 World Health Organization classification of central nervous system tumors. \*Subependymoma and myxopapillary ependymoma remain histopathologically defined tumor types. H3 K27me3 indicates trimethylation of histone H3 at lysine 27; MYCN, N-myc proto-oncogene; PF, posterior fossa; YAP1, yes-associated protein 1; ZFTA, zinc finger translocation associated.

groups, the 2021 classification allows the assignment of grade 2 or grade 3 based on the histopathologic features.

In contrast to ST ependymomas, PF ependymomas lack recurrent signature genetic events<sup>88,89</sup> but are classified based on their epigenetic features into 2 main groups: 1) PF type A (PFA) tumors are characterized by the *absence* of histone H3 K27-trimethylation, whereas 2) PFB tumors are characterized by a *high level* of histone H3 K27-trimethylation.<sup>90</sup> Most clinical studies suggest an inferior prognosis for PFA tumors, especially if chromosome 1q gain is present.<sup>80,82,83,90</sup> However, there are insufficient data to assign a WHO grade to PF ependymoma molecular groups, and these tumors can be graded as WHO grade 2 or grade 3 based on the histopathologic features.

SC ependymomas are diagnosed as myxopapillary or classical based on their morphology. The clinical outcome of myxopapillary and classical SC ependymomas is comparable,<sup>91</sup> and, unlike the 2016 WHO classification, the 2021 classification recommends grading myxopapillary SC ependymomas as grade 2 instead of grade 1. The 2021 WHO classification additionally recognizes a recently described SC ependymoma characterized by *MYCN* amplification, early dissemination, and a poor prognosis as a distinct new tumor type.<sup>92,93</sup>

The morphologic variants of classical ependymoma, defined in the WHO 2016 classification as papillary, clear cell, and tanyctic, are no longer recognized in the 2021 WHO classification given the lack of clinicopathologic utility.

The 2021 WHO classification system for ependymomas allows for the diagnosis of myxopapillary ependymoma and subependymoma based on histopathologic features but requires molecular testing for accurate diagnosis of the remaining ependymoma classes. Class-defining genetic alterations in ST ependymomas and *MYCN*-amplified SC ependymomas can be reliably detected by interphase fluorescence in situ hybridization.<sup>88</sup> PFA and PFB ependymomas can be distinguished by the absence or presence, respectively, of H3 K27me3 staining.<sup>90</sup> Finally, DNA methylation profiling can be a powerful diagnostic tool in difficult cases when ependymoma is included in the differential diagnosis based on anatomic location and histopathologic features of the tumor.<sup>85,94</sup>

### Meningiomas

Meningiomas are the most common primary CNS tumors. These tumors are slow-growing, mostly nonmalignant (CNS WHO grade 1) and may be cured by gross total resection. However, approximately 20% of meningiomas have a less favorable clinical course, with local recurrence and/or progression to a higher tumor grade with brain invasion, posing a significant therapeutic challenge.<sup>95</sup> The 2016 WHO classification of CNS tumors for the first time incorporated molecular features into the classification of meningiomas, reflecting advances in our understanding of meningioma biology.<sup>2</sup> Within the meningioma category, it defined 15 distinct meningioma variants that

differ in their histopathology and molecular features and can be separated by tumor grade. The overwhelming majority of meningiomas fall within WHO grade I, and the 2016 classification included 9 different variants in this group, with the meningothelial and fibroblastic variants occurring most frequently. WHO grade II tumors included 3 histopathologically distinct variants that share morphologic characteristics of increased malignancy. Finally, anaplastic meningiomas, or WHO grade III meningioma, comprised 3 variants characterized by high-grade histologic features and a poor prognosis. The 2021 WHO classification retains meningioma as a single tumor type with 15 distinct subtypes. However, grading of meningiomas changed to a within-tumor-type grading system. Tumor grade is no longer defined by meningioma subtype, but criteria for grade 2 and grade 3 meningiomas should be applied regardless of subtype.

Although meningioma subtypes and CNS WHO grades remain primarily based on histologic criteria, the 2021 WHO classification endorses molecular biomarkers to support classification and grading of meningiomas. Over the last few years, genomic and epigenomic studies have deepened our understanding of the molecular characteristics of meningiomas, linking recurrent driver mutations with distinct clinicopathologic phenotypes, tumor localization, and prognosis. Incorporation of these newly identified molecular features into the 2021 WHO classification has the potential to improve risk assessment and prognostic awareness, and it could offer new avenues for treatment.

Compared with other solid tumors, meningiomas have relatively simple genomes with few recurrent genetic alterations.<sup>96</sup> The most common recurrent genetic event is alteration of the tumor-suppressor gene neurofibromatosis-2 (*NF2*), which is observed in most meningiomas that occur in the setting of both neurofibromatosis type 2 as well as in approximately 60% of sporadic meningiomas. Inactivating mutation of 1 *NF2* allele is generally associated with chromosome 22 loss, affecting the second allele.<sup>97</sup> Additional karyotypic abnormalities increase in frequency with meningioma grade and include deletion of 1p, 6q, 9p, 10, 14q, and 18q.<sup>98</sup> Recently, genomic and targeted sequencing efforts have yielded several additional recurrent mutations, including AKT serine/threonine kinase 1 (*AKT1*),<sup>99</sup> smoothed (*SMO*),<sup>96,99,100</sup> Kruppel-like factor 4 (*KLF4*),<sup>99,101</sup> tumor necrosis factor receptor-associated factor 7 (*TRAF7*),<sup>99,100</sup> phosphatidylinositol-4,5-bisphosphate 3-kinase catalytic subunit  $\alpha$  (*PIK3CA*),<sup>100</sup> BRCA-associated protein 1 (*BAP1*),<sup>102</sup> and switch/sucrose nonfermentable-related matrix-associated actin-dependent regulator of chromatin

(SMARC) subfamily E member 1 (*SMARCE1*),<sup>103,104</sup> and the clinicopathologic relevance of these alterations is beginning to emerge.

In meningiomas, mutational status and clinicopathologic phenotype correlate with tumor location, possibly reflecting the different developmental origin of the meninges over the convexity of the brain versus the meninges along the skull base.<sup>105,106</sup> Convexity meningiomas are predominately of fibroblastic or transitional histology and often harbor *NF2* and *SMARCB1* alterations.<sup>107,108</sup> Grade 2 and 3 meningiomas are also more common at the convexity compared with the skull base and are similarly enriched in *NF2* gene mutations,<sup>109</sup> but they also often harbor alterations affecting the *TERT* gene promoter and *CDKN2A*.<sup>110-113</sup> By contrast, skull base meningiomas are enriched for meningothelial, secretory, and microcystic histologies and are characterized by mutations in the *AKT1*, *KLF4*, *TRAF7*, *SMO*, *PIK3CA*, and RNA polymerase II subunit A (*POLR2A*) genes. The meningothelial variant is enriched for mutations in *AKT1*, *SMO*, and *POLR2A*,<sup>96,114-116</sup> with *SMO* mutations especially frequent in the anterior skull base<sup>99</sup> and *POLR2A* mutations especially frequent near the tuberculum sellae region.<sup>117</sup> Secretory meningiomas are enriched for mutations in *KLF4* and *TRAF7*, with *KLF4* mutations exclusively occurring in this variant.<sup>99,101</sup> Finally, meningiomas harboring mutations in the *PIK3CA* gene can be of either meningothelial or transitional morphology.<sup>100</sup> Compared with convexity and skull base meningiomas, spinal cord meningiomas have a distinct molecular profile and frequently harbor *SMARCE1* mutations, which are associated with a clear cell phenotype.<sup>103,104</sup> Finally, *BAP1* mutation is a frequent genetic alteration in the rhabdoid subtype, and *BAP1* expression has been shown to separate meningiomas with rhabdoid morphologic features into aggressive and less aggressive forms.<sup>102</sup> The 2021 WHO classification of CNS tumors incorporates these findings, allowing for the diagnosis of meningioma if classic driver mutations of conventional meningioma (*NF2*, *TRAF7*, *AKT1*, *KLF4*, *SMO*, *PIK3CA*), clear cell meningioma (*SMARCE1*), or rhabdoid meningioma (*BAP1*) are present alongside suggestive histopathologic features. However, molecular biomarkers are not required for diagnosis if definitive histopathologic features of a meningioma subtype are present.

Mutational status correlates not only with unique clinical phenotypes but also with prognosis. Cytogenetic changes are more extensive in grade 2 and 3 meningiomas,<sup>98</sup> and karyotypic alterations, especially loss of 1p, have been associated with more aggressive clinical behavior.<sup>97,118-120</sup> In addition, activating mutations in the *TERT*



gene promoter are frequently observed in progressive/higher grade meningiomas<sup>112,113</sup> and constitute a strong, independent risk factor for meningioma progression and poor survival.<sup>110,121</sup> Similarly, loss of *CDKN2A* is common in high-grade meningiomas<sup>111</sup> and is associated with meningioma progression in preclinical models<sup>122</sup> and a shortened survival in clinical studies.<sup>123</sup> The 2021 WHO classification accounts for these new insights by integrating existing histopathologic criteria with *TERT* promoter and *CDKN2A* status to achieve improved grading of meningiomas. Anaplastic meningioma, CNS WHO grade 3, is now diagnosed even in the absence of anaplastic histopathologic features if *TERT* promoter mutation and/or homozygous *CDKN2A* deletion is present.

Multiple targetable genetic alterations have been identified in meningiomas, and targeted therapies are being evaluated in patients who are not amenable to local therapy or who have exhausted local therapeutic options. The molecular biomarkers established in the 2021 WHO classification have important implications for the design and interpretation of clinical trials investigating new therapeutic options in meningiomas. A phase 2 study assigning patients with meningioma to targeted treatments based on molecular features (*NF2*, *SMO*, *AKT1*) recently reported tolerability of the focal adhesion inhibitor GSK2256098 and improved progression-free survival at 6 months in patients with recurrent or progressive, *NF2*-mutated meningiomas compared with historical controls (ClinicalTrials.gov identifier NCT02523014).<sup>124</sup> In addition, *CDKN2A/B* homozygous deletion constitutes a possible therapeutic target for CDK4/6 inhibitors in high-grade meningiomas.<sup>125</sup>

## DISCUSSION

Since the publication of the updated fourth edition of the WHO Classification of CNS tumors in 2016, our understanding of the molecular underpinnings of many of these tumors has continued to evolve at a rapid pace. The fifth edition of the 2021 WHO classification of CNS tumors has been revised to incorporate many of these new insights. Several of the updates reviewed here have important implications for clinical practice. Changes with high clinical impact include those affecting the grading of diffuse astrocytic gliomas, in which, for some patients, molecular markers now allow for the diagnosis of glioblastoma, *IDH*-wildtype or astrocytoma, *IDH*-mutant, CNS WHO grade 4, even in the absence of high-grade features on histology. Many of these changes elevate the importance of molecular testing and, in some

instances, introduce new technologies into the routine diagnosis of CNS tumors.

The adoption of the fifth edition of the WHO classification of CNS tumors into clinical practice will aid the accurate diagnosis of CNS tumors, improve their management, and facilitate optimal patient care. The changes in the 2021 WHO classification of CNS tumors also have important implications for the design, implementation, and interpretation of clinical trials. The increased reliance on molecular features for tumor classification will change the timelines for patient enrollment because screening will necessitate molecular testing to ensure that appropriate patients are being enrolled for the disease entity being studied. The logistic and financial considerations caused by these changes have the potential to limit the availability of clinical trial sites and reduce patient enrollment. However, improved definition of disease entities will lead to the design of more specific therapies and prevent the potentially confounding effects on response and outcome when histologically similar but molecularly distinct tumors were studied together in the past (eg, *IDH*-mutant astrocytomas with and without *CDKN2A* deletions).

## FUNDING SUPPORT

No specific funding was disclosed.

## CONFLICT OF INTEREST DISCLOSURES

Simon Gritsch reports a postdoctoral fellowship (GR 5252/1-1) from Deutsche Forschungsgemeinschaft outside the submitted work. Tracy T. Batchelor reports institutional grants from the National Institutes of Health; royalties from *Up To Date*; personal fees from the National Institutes of Health and Champions Biotechnology; honoraria from Oakstone Audio Digest; and service on a Genomicare Scientific Advisory Board outside the submitted work. L. Nicolas Gonzalez Castro reports institutional grants from the National Institutes of Health; a Young Investigator Award from the American Society of Clinical Oncology; personal fees from Teladoc Health and Practice Update Elsevier; and honoraria from Harvard Student Agencies outside the submitted work.

## REFERENCES

- Zulch KJ. Brain Tumors. Their Biology and Pathology. Springer-Verlag; 1986.
- Louis DN, Ohgaki H, Wiestler OD, Cavenee WK, eds. World Health Organization Classification of Tumours of the Central Nervous System. 4th ed. International Agency for Research on Cancer; 2016.
- Chapman PB, Hauschild A, Robert C, et al. Improved survival with vemurafenib in melanoma with BRAF V600E mutation. *N Engl J Med*. 2011;364:2507-2516. doi:10.1056/nejmoa1103782
- Brastianos PK, Shankar GM, Gill CM, et al. Dramatic response of BRAF V600E mutant papillary craniopharyngioma to targeted therapy. *J Natl Cancer Inst*. 2016;108:djv310. doi:10.1093/jnci/djv310
- Juratli TA, Jones PS, Wang N, et al. Targeted treatment of papillary craniopharyngiomas harboring BRAF V600E mutations. *Cancer*. 2019;125:2910-2914. doi:10.1002/cncr.32197
- Aylwin SJB, Bodi I, Beaney R. Pronounced response of papillary craniopharyngioma to treatment with vemurafenib, a BRAF inhibitor. *Pituitary*. 2016;19:544-546. doi:10.1007/s11102-015-0663-4

7. Lynch TJ, Bell DW, Sordella R, et al. Activating mutations in the epidermal growth factor receptor underlying responsiveness of non-small-cell lung cancer to gefitinib. *N Engl J Med.* 2004;350:2129-2139. doi:10.1056/nejmoa040938
8. Kwak EL, Bang YJ, Camidge DR, et al. Anaplastic lymphoma kinase inhibition in non-small-cell lung cancer. *N Engl J Med.* 2010;363:1693-1703. doi:10.1056/nejmoa1006448
9. Slamon DJ, Leyland-Jones B, Shak S, et al. Use of chemotherapy plus a monoclonal antibody against HER2 for metastatic breast cancer that overexpresses HER2. *N Engl J Med.* 2001;344:783-792. doi:10.1056/nejm200103153441101
10. Druker BJ, Talpaz M, Resta DJ, et al. Efficacy and safety of a specific inhibitor of the BCR-ABL tyrosine kinase in chronic myeloid leukemia. *N Engl J Med.* 2001;344:1031-1037. doi:10.1056/nejm200104053441401
11. Franz DN, Agricola K, Mays M, et al. Everolimus for subependymal giant cell astrocytoma: 5-year final analysis. *Ann Neurol.* 2015;78:929-938. doi:10.1002/ana.24523
12. Klesse LJ, Jordan JT, Radtke HB, et al. The use of MEK inhibitors in neurofibromatosis type 1-associated tumors and management of toxicities. *Oncologist.* 2020;25:e1109-e1116. doi:10.1634/theoncologist.2020-0069
13. Torre M, Vasudevaraja V, Serrano J, et al. Molecular and clinicopathologic features of gliomas harboring NTRK fusions. *Acta Neuropathol Commun.* 2020;8:107. doi:10.1186/s40478-020-00980-z
14. Drilon A, Laetsch TW, Kummar S, et al. Efficacy of larotrectinib in TRK fusion-positive cancers in adults and children. *N Engl J Med.* 2018;378:731-739. doi:10.1056/nejmoa1714448
15. Drilon A. TRK inhibitors in TRK fusion-positive cancers. *Ann Oncol.* 2019;30(suppl 8):viii23-viii30. doi:10.1093/annonc/mdz282
16. Nabors LB, Portnow J, Ahluwalia M, et al. Central Nervous System Cancers, version 3.2020. NCCN Clinical Practice Guidelines in Oncology. *J Natl Compr Cancer Netw.* 2020;18:1537-1570. doi:10.6004/JNCCN.2020.0052
17. Ellison DW, Hawkins C, Jones DTW, et al. cIMPACT-NOW update 4: diffuse gliomas characterized by MYB, MYBL1, or FGFR1 alterations or BRAF V600E mutation. *Acta Neuropathol.* 2019;137:683-687. doi:10.1007/s00401-019-01987-0
18. Louis DN, Wesseling P, Paulus W, et al. cIMPACT-NOW update 1: not otherwise specified (NOS) and not elsewhere classified (NEC). *Acta Neuropathol.* 2018;135:481-484. doi:10.1007/s00401-018-1808-0
19. Louis DN, Wesseling P, Aldape K, et al. cIMPACT-NOW update 6: new entity and diagnostic principle recommendations of the cIMPACT-Utrecht meeting on future CNS tumor classification and grading. *Brain Pathol.* 2020;30:844-856. doi:10.1111/bpa.12832
20. Ellison DW, Aldape KD, Capper D, et al. cIMPACT-NOW update 7: advancing the molecular classification of ependymal tumors. *Brain Pathol.* 2020;30:863-866. doi:10.1111/bpa.12866
21. Brat DJ, Aldape K, Colman H, et al. cIMPACT-NOW update 3: recommended diagnostic criteria for "diffuse astrocytic glioma, IDH-wildtype, with molecular features of glioblastoma, WHO grade IV." *Acta Neuropathol.* 2018;136:805-810. doi:10.1007/s00401-018-1913-0
22. Brat DJ, Aldape K, Colman H, et al. cIMPACT-NOW update 5: recommended grading criteria and terminologies for IDH-mutant astrocytomas. *Acta Neuropathol.* 2020;139:603-608. doi:10.1007/s00401-020-02127-9
23. Louis DN, Giannini C, Capper D, et al. cIMPACT-NOW update 2: diagnostic clarifications for diffuse midline glioma, H3 K27M-mutant and diffuse astrocytoma/anaplastic astrocytoma, IDH-mutant. *Acta Neuropathol.* 2018;135:639-642. doi:10.1007/s00401-018-1826-y
24. Gonzalez Castro LN, Wesseling P. The cIMPACT-NOW updates and their significance to current neuro-oncology practice. *Neurooncol Pract.* 2020;8:4-10. doi:10.1093/nop/npaa055
25. Louis DN, Perry A, Wesseling P, et al. The 2021 WHO Classification of Tumors of the Central Nervous System: a summary. *Neuro Oncol.* 2021;23:1231-1251. doi:10.1093/neuonc/noab106
26. Louis DN, Ohgaki H, Wiestler OD, Cavenee WK, eds. World Health Organization Classification of Tumours of the Central Nervous System. 5th ed. International Agency for Research on Cancer; 2021.
27. Ostrom QT, Patil N, Cioffi G, Waite K, Kruchko C, Barnholtz-Sloan JS. CBTRUS statistical report: primary brain and other central nervous system tumors diagnosed in the United States in 2013-2017. *Neuro Oncol.* 2020;22(12 suppl 2):iv1-iv96. doi:10.1093/neuonc/noaa200
28. Jaunmuktane Z, Capper D, Jones DTW, et al. Methylation array profiling of adult brain tumours: diagnostic outcomes in a large, single centre. *Acta Neuropathol Commun.* 2019;7:24. doi:10.1186/s40478-019-0668-8
29. Capper D, Stichel D, Sahm F, et al. Practical implementation of DNA methylation and copy-number-based CNS tumor diagnostics: the Heidelberg experience. *Acta Neuropathol.* 2018;136:181-210. doi:10.1007/s00401-018-1879-y
30. Capper D, Jones DTW, Sill M, et al. DNA methylation-based classification of central nervous system tumours. *Nature.* 2018;555:469-474. doi:10.1038/nature26000
31. Tesileanu CMS, Dirven L, Wijnenga MMJ, et al. Survival of diffuse astrocytic glioma, IDH1/2 wildtype, with molecular features of glioblastoma, WHO grade IV: a confirmation of the cIMPACT-NOW criteria. *Neuro Oncol.* 2020;22:515-523. doi:10.1093/neuonc/noz200
32. Cancer Genome Atlas Research Network; Brat DJ, Verhaak RG, et al. Comprehensive, integrative genomic analysis of diffuse lower-grade gliomas. *N Engl J Med.* 2015;372:2481-2498. doi:10.1056/nejmoa1402121
33. Shirahata M, Ono T, Stichel D, et al. Novel, improved grading system(s) for IDH-mutant astrocytic gliomas. *Acta Neuropathol.* 2018;136:153-166. doi:10.1007/s00401-018-1849-4
34. Snuderl M, Fazlollahi L, Le LP, et al. Mosaic amplification of multiple receptor tyrosine kinase genes in glioblastoma. *Cancer Cell.* 2011;20:810-817. doi:10.1016/j.ccr.2011.11.005
35. Nefel C, Laffy J, Filbin MG, et al. An integrative model of cellular states, plasticity, and genetics for glioblastoma. *Cell.* 2019;178:835-849.e21. doi:10.1016/j.cell.2019.06.024
36. Venteicher AS, Tirosch I, Hebert C, et al. Decoupling genetics, lineages, and microenvironment in IDH-mutant gliomas by single-cell RNA-seq. *Science.* 2017;355:eaai8478. doi:10.1126/science.aai8478
37. Patel AP, Tirosch I, Trombetta JJ, et al. Single-cell RNA-seq highlights intratumoral heterogeneity in primary glioblastoma. *Science.* 2014;344:1396-1401. doi:10.1126/science.1254257
38. Dunn GP, Rinne ML, Wykosky J, et al. Emerging insights into the molecular and cellular basis of glioblastoma. *Genes Dev.* 2012;26:756-784. doi:10.1101/gad.187922.112
39. Brennan CW, Verhaak RGW, McKenna A, et al. The somatic genomic landscape of glioblastoma. *Cell.* 2013;155:462-477. doi:10.1016/j.cell.2013.09.034
40. Bell RJA, Rube HT, Kreig A, et al. The transcription factor GABP selectively binds and activates the mutant TERT promoter in cancer. *Science.* 2015;348:1036-1039. doi:10.1126/science.aab0015
41. Yan H, Parsons DW, Jin G, et al. IDH1 and IDH2 mutations in gliomas. *N Engl J Med.* 2009;360:765-773. doi:10.1056/nejmoa0808710
42. Parsons DW, Jones S, Zhang X, et al. An integrated genomic analysis of human glioblastoma multiforme. *Science.* 2008;321:1807-1812. doi:10.1126/science.1164382
43. Dang L, White DW, Gross S, et al. Cancer-associated IDH1 mutations produce 2-hydroxyglutarate. *Nature.* 2009;462:739-744. doi:10.1038/nature08617
44. Grassian AR, Parker SJ, Davidson SM, et al. IDH1 mutations alter citric acid cycle metabolism and increase dependence on oxidative mitochondrial metabolism. *Cancer Res.* 2014;74:3317-3331. doi:10.1158/0008-5472.CAN-14-0772-T
45. Reitman ZJ, Duncan CG, Poreet E, et al. Cancer-associated isocitrate dehydrogenase 1 (IDH1) R132H mutation and D-2-hydroxyglutarate stimulate glutamine metabolism under hypoxia. *J Biol Chem.* 2014;289:23318-23328. doi:10.1074/jbc.M114.575183
46. Tateishi K, Wakimoto H, Iafate AJ, et al. Extreme vulnerability of IDH1 mutant cancers to NAD<sup>+</sup> depletion. *Cancer Cell.* 2015;28:773-784. doi:10.1016/j.ccell.2015.11.006
47. Leonardi R, Subramanian C, Jackowski S, Rock CO. Cancer-associated isocitrate dehydrogenase mutations inactivate NADPH-dependent reductive carboxylation. *J Biol Chem.* 2012;287:14615-14620. doi:10.1074/jbc.C112.353946

48. Gross S, Cairns RA, Minden MD, et al. Cancer-associated metabolite 2-hydroxyglutarate accumulates in acute myelogenous leukemia with isocitrate dehydrogenase 1 and 2 mutations. *J Exp Med*. 2010;207:339-344. doi:10.1084/jem.20092506
49. Xu W, Yang H, Liu Y, et al. Oncometabolite 2-hydroxyglutarate is a competitive inhibitor of  $\alpha$ -ketoglutarate-dependent dioxygenases. *Cancer Cell*. 2011;19:17-30. doi:10.1016/j.ccr.2010.12.014
50. Chowdhury R, Yeoh KK, Tian YM, et al. The oncometabolite 2-hydroxyglutarate inhibits histone lysine demethylases. *EMBO Rep*. 2011;12:463-469. doi:10.1038/embor.2011.43
51. Lu C, Ward PS, Kapoor GS, et al. IDH mutation impairs histone demethylation and results in a block to cell differentiation. *Nature*. 2012;483:474-478. doi:10.1038/nature10860
52. Flavahan WA, Drier Y, Liu BB, et al. Insulator dysfunction and oncogene activation in IDH mutant gliomas. *Nature*. 2016;529:110-114. doi:10.1038/nature16490
53. Noushmehr H, Weisenberger DJ, Diefes K, et al. Identification of a CpG island methylator phenotype that defines a distinct subgroup of glioma. *Cancer Cell*. 2010;17:510-522. doi:10.1016/j.ccr.2010.03.017
54. Turcan S, Rohle D, Goenka A, et al. IDH1 mutation is sufficient to establish the glioma hypermethylator phenotype. *Nature*. 2012;483:479-483. doi:10.1038/nature10866
55. Losman JA, Koivunen P, Kaelin WG. 2-Oxoglutarate-dependent dioxygenases in cancer. *Nat Rev Cancer*. 2020;20:710-726. doi:10.1038/s41568-020-00303-3
56. Wakimoto H, Tanaka S, Curry WT, et al. Targetable signaling pathway mutations are associated with malignant phenotype in IDH-mutant gliomas. *Clin Cancer Res*. 2014;20:2898-2909. doi:10.1158/1078-0432.CCR-13-3052
57. Mazar T, Chesnelong C, Pankov A, et al. Clonal expansion and epigenetic reprogramming following deletion or amplification of mutant IDH1. *Proc Natl Acad Sci U S A*. 2017;114:10743-10748. doi:10.1073/pnas.1708914114
58. Liu XY, Gerges N, Korshunov A, et al. Frequent ATRX mutations and loss of expression in adult diffuse astrocytic tumors carrying IDH1/IDH2 and TP53 mutations. *Acta Neuropathol*. 2012;124:615-625. doi:10.1007/s00401-012-1031-3
59. Jiao Y, Killela PJ, Reitman ZJ, et al. Frequent ATRX, CIC, FUBP1 and IDH1 mutations refine the classification of malignant gliomas. *Oncotarget*. 2012;3:709-722. doi:10.18632/oncotarget.588
60. Abedalthagafi M, Phillips JJ, Kim GE, et al. The alternative lengthening of telomere phenotype is significantly associated with loss of ATRX expression in high-grade pediatric and adult astrocytomas: a multi-institutional study of 214 astrocytomas. *Mod Pathol*. 2013;26:1425-1432. doi:10.1038/modpathol.2013.90
61. Reuss DE, Sahn F, Schrimpf D, et al. ATRX and IDH1-R132H immunohistochemistry with subsequent copy number analysis and IDH sequencing as a basis for an "integrated" diagnostic approach for adult astrocytoma, oligodendroglioma and glioblastoma. *Acta Neuropathol*. 2015;129:133-146. doi:10.1007/s00401-014-1370-3
62. Koelsche C, Sahn F, Capper D, et al. Distribution of TERT promoter mutations in pediatric and adult tumors of the nervous system. *Acta Neuropathol*. 2013;126:907-915. doi:10.1007/s00401-013-1195-5
63. Weller M, Weber RG, Willscher E, et al. Molecular classification of diffuse cerebral WHO grade II/III gliomas using genome- and transcriptome-wide profiling improves stratification of prognostically distinct patient groups. *Acta Neuropathol*. 2015;129:679-693. doi:10.1007/s00401-015-1409-0
64. Korshunov A, Casalini B, Chavez L, et al. Integrated molecular characterization of IDH-mutant glioblastomas. *Neuropathol Appl Neurobiol*. 2019;45:108-118. doi:10.1111/nan.12523
65. Appay R, Dehais C, Maurice CA, et al. CDKN2A homozygous deletion is a strong adverse prognosis factor in diffuse malignant IDH-mutant gliomas. *Neuro Oncol*. 2019;21:1519-1528. doi:10.1093/neuonc/now124
66. Platten M, Bunse L, Wick A, et al. A vaccine targeting mutant IDH1 in newly diagnosed glioma. *Nature*. 2021;592:463-468. doi:10.1038/s41586-021-03363-z
67. Mellingshoff IK, Cloughesy TF, Wen PY, et al. A phase I, open label, perioperative study of AG-120 and AG-881 in recurrent IDH1 mutant, low-grade glioma: results from cohort 1 [abstract]. *J Clin Oncol*. 2019;37(15 suppl):2003. doi:10.1200/jco.2019.37.15\_suppl.2003
68. Wick A, Bahr O, Schuler M, et al. Phase I assessment of safety and therapeutic activity of BAY1436032 in patients with IDH1-mutant solid tumors. *Clin Cancer Res*. 2021;27:2723-2733. doi:10.1158/1078-0432.CCR-20-4256
69. Han CH, Batchelor TT. Isocitrate dehydrogenase mutation as a therapeutic target in gliomas. *Chin Clin Oncol*. 2017;6:33. doi:10.21037/cco.2017.06.11
70. Finn RS, Martin M, Rugo HS, et al. PALOMA-2: primary results from a phase III trial of palbociclib (P) with letrozole (L) compared with letrozole alone in postmenopausal women with ER+/HER2-advanced breast cancer (ABC) [abstract]. *J Clin Oncol*. 2016;34(15 suppl):507. doi:10.1200/JCO.2016.34.15\_suppl.507
71. Michaud K, Solomon DA, Oermann E, et al. Pharmacologic inhibition of cyclin-dependent kinases 4 and 6 arrests the growth of glioblastoma multiforme intracranial xenografts. *Cancer Res*. 2010;70:3228-3238. doi:10.1158/0008-5472.CAN-09-4559
72. Martinez-Chavez A, van Hoppe S, Rosing H, et al. P-glycoprotein limits ribociclib brain exposure and CYP3A4 restricts its oral bioavailability. *Mol Pharm*. 2019;16:3842-3852. doi:10.1021/acs.molpharmaceut.9b00475
73. Juric V, Murphy B. Cyclin-dependent kinase inhibitors in brain cancer: current state and future directions. *Cancer Drug Resist*. 2020;3:48-62. doi:10.20517/cdr.2019.105
74. Kocakavuk E, Anderson KJ, Varn FS, et al. Radiotherapy is associated with a deletion signature that contributes to poor outcomes in patients with cancer. *Nat Genet*. 2021;53:1088-1096. doi:10.1038/s41588-021-00874-3
75. Buckner JC, Shaw EG, Pugh SL, et al. Radiation plus procarbazine, CCNU, and vincristine in low-grade glioma. *N Engl J Med*. 2016;374:1344-1355. doi:10.1056/NEJMoa1500925
76. van den Bent MJ, Tesileanu CMS, Wick W, et al. Adjuvant and concurrent temozolomide for 1p/19q non-co-deleted anaplastic glioma (CATNON; EORTC study 26053-22054): second interim analysis of a randomised, open-label, phase 3 study. *Lancet Oncol*. 2021;22:813-823. doi:10.1016/S1470-2045(21)00090-5
77. Wahl M, Phillips JJ, Molinaro AM, et al. Chemotherapy for adult low-grade gliomas: clinical outcomes by molecular subtype in a phase II study of adjuvant temozolomide. *Neuro Oncol*. 2017;19:242-251. doi:10.1093/neuonc/now176
78. Baumert BG, Hegi ME, van den Bent MJ, et al. Temozolomide chemotherapy versus radiotherapy in high-risk low-grade glioma (EORTC 22033-26033): a randomised, open-label, phase 3 intergroup study. *Lancet Oncol*. 2016;17:1521-1532. doi:10.1016/S1470-2045(16)30313-8
79. Wick W, Roth P, Hartmann C, et al. Long-term analysis of the NOA-04 randomized phase III trial of sequential radiochemotherapy of anaplastic glioma with PCV or temozolomide. *Neuro Oncol*. 2016;18:1529-1537. doi:10.1093/neuonc/now133
80. Pajdler KW, Witt H, Sill M, et al. Molecular classification of ependymal tumors across all CNS compartments, histopathological grades, and age groups. *Cancer Cell*. 2015;27:728-743. doi:10.1016/j.ccell.2015.04.002
81. Ellison DW, Kocak M, Figarella-Branger D, et al. Histopathological grading of pediatric ependymoma: reproducibility and clinical relevance in European trial cohorts. *J Negat Results Biomed*. 2011;10:7. doi:10.1186/1477-5751-10-7
82. Witt H, Mack SC, Ryzhova M, et al. Delineation of two clinically and molecularly distinct subgroups of posterior fossa ependymoma. *Cancer Cell*. 2011;20:143-157. doi:10.1016/j.ccr.2011.07.007
83. Wani K, Armstrong TS, Vera-Bolanos E, et al. A prognostic gene expression signature in infratentorial ependymoma. *Acta Neuropathol*. 2012;123:727-738. doi:10.1007/s00401-012-0941-4
84. Pajdler KW, Wen J, Sill M, et al. Molecular heterogeneity and CXorf67 alterations in posterior fossa group A (PFA) ependymomas. *Acta Neuropathol*. 2018;136:211-226. doi:10.1007/s00401-018-1877-0
85. Witt H, Gramatzki D, Hentschel B, et al. DNA methylation-based classification of ependymomas in adulthood: implications for diagnosis and treatment. *Neuro Oncol*. 2018;20:1616-1624. doi:10.1093/neuonc/now118

86. Cavalli FMG, Hubner JM, Sharma T, et al. Heterogeneity within the PF-EPN-B ependymoma subgroup. *Acta Neuropathol.* 2018;136:227-237. doi:10.1007/s00401-018-1888-x
87. Andreiuolo F, Varlet P, Tauziède-Espariat A, et al. Childhood supratentorial ependymomas with YAP1-MAML1 fusion: an entity with characteristic clinical, radiological, cytogenetic and histopathological features. *Brain Pathol.* 2019;29:205-216. doi:10.1111/bpa.12659
88. Parker M, Mohankumar KM, Punchihewa C, et al. C1orf95-RELA fusions drive oncogenic NF- $\kappa$ B signalling in ependymoma. *Nature.* 2014;506:451-455. doi:10.1038/nature13109
89. MacK SC, Witt H, Piro RM, et al. Epigenomic alterations define lethal CIMP-positive ependymomas of infancy. *Nature.* 2014;506:445-450. doi:10.1038/nature13108
90. Panwalkar P, Clark J, Ramaswamy V, et al. Immunohistochemical analysis of H3K27me3 demonstrates global reduction in group-A childhood posterior fossa ependymoma and is a powerful predictor of outcome. *Acta Neuropathol.* 2017;134:705-714. doi:10.1007/s00401-017-1752-4
91. Vera-Bolanos E, Aldape K, Yuan Y, et al. Clinical course and progression-free survival of adult intracranial and spinal ependymoma patients. *Neuro Oncol.* 2015;17:440-447. doi:10.1093/neuonc/nou162
92. Swanson AA, Raghunathan A, Jenkins RB, et al. Spinal cord ependymomas with MYCN amplification show aggressive clinical behavior. *J Neuropathol Exp Neurol.* 2019;78:791-797. doi:10.1093/jnen/nlz064
93. Ghasemi DR, Sill M, Okonechnikov K, et al. MYCN amplification drives an aggressive form of spinal ependymoma. *Acta Neuropathol.* 2019;138:1075-1089. doi:10.1007/s00401-019-02056-2
94. Sturm D, Orr BA, Toprak UH, et al. New brain tumor entities emerge from molecular classification of CNS-PNETs. *Cell.* 2016;164:1060-1072. doi:10.1016/j.cell.2016.01.015
95. Harter PN, Braun Y, Plare KH. Classification of meningiomas—advances and controversies. *Chin Clin Oncol.* 2017;6(suppl 1):S2. doi:10.21037/cco.2017.05.02
96. Brastianos PK, Horowitz PM, Santagata S, et al. Genomic sequencing of meningiomas identifies oncogenic SMO and AKT1 mutations. *Nat Genet.* 2013;45:285-289. doi:10.1038/ng.2526
97. Zang KD. Meningioma: a cytogenetic model of a complex benign human tumor, including data on 394 karyotyped cases. *Cytogenet Cell Genet.* 2001;93:207-220. doi:10.1159/000056986
98. Mawrin C, Perry A. Pathological classification and molecular genetics of meningiomas. *J Neurooncol.* 2010;99:379-391. doi:10.1007/s11060-010-0342-2
99. Clark VE, Erson-Omay EZ, Serin A, et al. Genomic analysis of non-NF2 meningiomas reveals mutations in TRAF7, KLF4, AKT1, and SMO. *Science.* 2013;339:1077-1080. doi:10.1126/science.1233009
100. Abedalthagafi M, Bi WL, Aizer AA, et al. Oncogenic PI3K mutations are as common as AKT1 and SMO mutations in meningioma. *Neuro Oncol.* 2016;18:649-655. doi:10.1093/neuonc/nov316
101. Reuss DE, Piro RM, Jones DTW, et al. Secretory meningiomas are defined by combined KLF4 K409Q and TRAF7 mutations. *Acta Neuropathol.* 2013;125:351-358. doi:10.1007/s00401-013-1093-x
102. Shankar GM, Abedalthagafi M, Vaubel RA, et al. Germline and somatic BAP1 mutations in high-grade rhabdoid meningiomas. *Neuro Oncol.* 2017;19:535-545. doi:10.1093/neuonc/now235
103. Smith MJ, O'Sullivan J, Bhaskar SS, et al. Loss-of-function mutations in SMARCE1 cause an inherited disorder of multiple spinal meningiomas. *Nat Genet.* 2013;45:295-298. doi:10.1038/ng.2552
104. Smith MJ, Wallace AJ, Bennett C, et al. Germline SMARCE1 mutations predispose to both spinal and cranial clear cell meningiomas. *J Pathol.* 2014;234:436-440. doi:10.1002/path.4427
105. Catala M. Embryonic and fetal development of structures associated with the cerebro-spinal fluid in man and other species. Part I: the ventricular system, meninges and choroid plexuses. *Arch Anat Cytol Pathol.* 1998;46:153-169.
106. Preusser M, Brastianos PK, Mawrin C. Advances in meningioma genetics: novel therapeutic opportunities. *Nat Rev Neurol.* 2018;14:106-115. doi:10.1038/nrneurol.2017.168
107. Lee JH, Sade B, Choi E, Golubic M, Prayson R. Meningothelioma as the predominant histological subtype of midline skull base and spinal meningioma. *J Neurosurg.* 2006;105:60-64. doi:10.3171/jns.2006.105.1.60
108. Kros J, De Greve K, Van Tilborg A, et al. NF2 status of meningiomas is associated with tumour localization and histology. *J Pathol.* 2001;194:367-372. doi:10.1002/path.909
109. Ketter R, Rahnenfuhrer J, Henn W, et al. Correspondence of tumor localization with tumor recurrence and cytogenetic progression in meningiomas. *Neurosurgery.* 2008;62:61-69. doi:10.1227/01.NEU.0000311062.72626.D6
110. Sahm F, Schrimpf D, Olar A, et al. TERT promoter mutations and risk of recurrence in meningioma. *J Natl Cancer Inst.* 2016;108:djv377. doi:10.1093/jnci/djv377
111. Goutagny S, Yang HW, Zucman-Rossi J, et al. Genomic profiling reveals alternative genetic pathways of meningioma malignant progression dependent on the underlying NF2 status. *Clin Cancer Res.* 2010;16:4155-4164. doi:10.1158/1078-0432.CCR-10-0891
112. Goutagny S, Nault JC, Mallet M, Henin D, Rossi JZ, Kalamirides M. High incidence of activating TERT promoter mutations in meningiomas undergoing malignant progression. *Brain Pathol.* 2014;24:184-189. doi:10.1111/bpa.12110
113. Kalala JPO, Maes L, Vandenbroecke C, De Ridder L. The hTERT protein as a marker for malignancy in meningiomas. *Oncol Rep.* 2005;13:273-277. doi:10.3892/or.13.2.273
114. Strickland MR, Gill CM, Nayyar N, et al. Targeted sequencing of SMO and AKT1 in anterior skull base meningiomas. *J Neurosurg.* 2017;127:438-444. doi:10.3171/2016.8.JNS161076
115. Sahm F, Bissel J, Koelsche C, et al. AKT1E17K mutations cluster with meningothelial and transitional meningiomas and can be detected by SFRP1 immunohistochemistry. *Acta Neuropathol.* 2013;126:757-762. doi:10.1007/s00401-013-1187-5
116. Boetto J, Bielle F, Sanson M, Peyre M, Kalamirides M. SMO mutation status defines a distinct and frequent molecular subgroup in olfactory groove meningiomas. *Neuro Oncol.* 2017;19:345-351. doi:10.1093/neuonc/now276
117. Clark VE, Harmanci AS, Bai H, et al. Recurrent somatic mutations in POLR2A define a distinct subset of meningiomas. *Nat Genet.* 2016;48:1253-1259. doi:10.1038/ng.3651
118. Simon M, von Deimling A, Larson JJ, et al. Allelic losses on chromosomes 14, 10, and 1 in atypical and malignant meningiomas: a genetic model of meningioma progression. *Cancer Res.* 1995;55:4696-4701.
119. Ketter R, Henn W, Niedermayer I, et al. Predictive value of progression-associated chromosomal aberrations for the prognosis of meningiomas: a retrospective study of 198 cases. *J Neurosurg.* 2001;95:601-607. doi:10.3171/jns.2001.95.4.0601
120. Bello MJ, Pestana A, Rey JA, et al. Allelic loss at 1p is associated with tumor progression of meningiomas. *Genes Chromosomes Cancer.* 1994;9:296-298. doi:10.1002/gcc.2870090411
121. Juratli TA, Thiede C, Koerner MVA, et al. Intratumoral heterogeneity and TERT promoter mutations in progressive/higher-grade meningiomas. *Oncotarget.* 2017;8:109228-109237. doi:10.18632/oncotarget.22650
122. Loewenstern J, Rutland J, Gill C, et al. Comparative genomic analysis of driver mutations in matched primary and recurrent meningiomas. *Oncotarget.* 2019;10:3506-3517. doi:10.18632/oncotarget.26941
123. Perry A, Banerjee R, Lohse CM, Kleinschmidt-DeMasters BK, Scheithauer BW. A role for chromosome 9p21 deletions in the malignant progression of meningiomas and the prognosis of anaplastic meningiomas. *Brain Pathol.* 2002;12:183-190. doi:10.1111/j.1750-3639.2002.tb00433.x
124. Brastianos PK, Twohy E, Gerstner ER, et al. Alliance A071401: phase II trial of FAK inhibition in meningiomas with somatic NF2 mutations [abstract]. *J Clin Oncol.* 2020;38(15 suppl):2502. doi:10.1200/JCO.2020.38.15\_suppl.2502
125. Das A, Alshareef M, Martinez Santos JL, et al. Evaluating anti-tumor activity of palbociclib plus radiation in anaplastic and radiation-induced meningiomas: pre-clinical investigations. *Clin Transl Oncol.* 2020;22:2017-2025. doi:10.1007/S12094-020-02341-7