

Keloids and Hypertrophic Scars



Ariel Knowles, MBBS^a, Donald A. Glass II, MD, PhD^{a,b,*}

KEYWORDS

• Keloids • Hypertrophic scar • Scarring • Fibroblast • Treatment

KEY POINTS

- Keloids are a fibroproliferative inflammatory disorder of the skin where scars grow excessively past the original borders of the inciting agent and invade into normal adjacent tissue.
- At the molecular/genetic level, an autosomal dominant mode of inheritance, a mutation in the protein N-acylsphingosine amidohydrolase 1, single-nucleotide polymorphisms in noncoding regions of the genome, and upregulation of critical fibroproliferative genes have all been linked to patients with keloids.
- Treatment of keloids can be aimed at flattening already formed keloids or at preventing the formation of keloids after trauma/surgery. A postsurgical treatment regimen is necessary to minimize the risk of recurrence after keloid excision.
- More basic/translational research as well as published case-control studies are needed.

INTRODUCTION

Keloids are an exaggerated fibroproliferative response to cutaneous wound healing in which scar tissue grows excessively and invasively beyond the original wound borders. They were first described as early as 3000 BC in the Edwin Smith Papyrus, the first known descriptions of ancient Egyptian medical practice. In the early nineteenth century, the French Dermatologist Jean Louis Alibert termed these scar keloids based on the Greek word for crabs claw “*cheloide*” or “*keloide*,” referencing the claw-like extension of the scar beyond the initial wound margins into the surrounding skin.¹ Keloids are raised, firm, fibrotic scars that can develop up to 1 year after injury to the skin, sometimes even beyond 1 year, and they do not tend to regress spontaneously. This contrasts with hypertrophic scars that tend to form within the first few months after injury, stay within the margins of the original wound and may regress spontaneously.² The general pathomechanisms that drive fibrotic scars and the biological differences between the formation of keloids and hypertrophic scars are

poorly understood, in part due to the lack of suitable animal models to study.³ Humans are the only species known to develop keloids.

Epidemiology

Race/ethnicity, genetic predisposition, and age may all contribute to keloid predilection. Keloid incidence rates vary greatly between different racial groups.⁴ Studies of keloid incidence in the general population report a varying incidence from 4.5 to 6.2 up to 16% in those of African descent while the incidence in the Taiwanese Chinese and Caucasians is reported to be as low as less than 1%.¹ The relative paucity of keloid incidence data in older publications has led some to question the notion of an increased prevalence of keloids in people of color.⁵ However, recent studies in head and neck surgical patients and women after caesarian sections show the incidence of keloid scar formation was significantly increased in African Americans (0.8% and 7.1%, respectively) compared with the Caucasian (0.1% and 0.5%, respectively) and Asian

^a Department of Dermatology, University of Texas Southwestern Medical Center, 5323 Harry Hines Boulevard, Dallas, TX 75390-9069, USA; ^b Eugene McDermott Center for Human Growth and Development, University of Texas Southwestern Medical Center, 5323 Harry Hines Boulevard, Dallas, TX 75390, USA

* Corresponding author. 5323 Harry Hines Boulevard, Mail Code 9069, Dallas, TX 75390-9069, USA.

E-mail address: donald.glass@utsouthwestern.edu

populations (0.2% and 5.2%, respectively).^{6,7} Despite observed differences in keloid incidence, increased skin pigmentation cannot solely explain the reported racial/ethnic differences in incidence rate. In a study of keloids in Africans with albinism, the prevalence rate of 7.5% was not statistically different from the overall prevalence rate of 8.3% in the general population or the 8.5% observed in the normally pigmented African population.^{8,9} In general, it is thought that no gender differences exist in keloid incidence, although some studies report that keloids are more likely to occur in women than men.¹⁰ Although keloids can develop at any age, the incidence is highest between the ages of 10 to 30 years.^{6,10,11} A peak in incidence after puberty, exacerbations of keloids during pregnancy, and decreased occurrences postmenopause indicate an endocrinological mechanism underlying keloid pathogenesis.¹²

Comorbidities

Keloids are recognized as an inflammatory skin disorder but evidence supports that the inflammation is not purely cutaneous because keloids are associated with several other medical conditions.¹³ Keloids have been associated with hypertension, obesity, atopy, and osteoporosis. Studies show an association between hypertension and keloid formation with hypertension and keloid size and number having a statistically significant positive correlation.¹⁴ Furthermore, individuals aged younger than 30 years with keloids have a higher incidence of hypertension.¹⁵ Evidence suggests that obesity may play a role in the presence of keloids occurring on the ears. A significant difference in obesity prevalence was seen between patients with ear-inclusive versus ear-exclusive keloids.¹⁶ Patients with atopic dermatitis have a higher-than-normal risk of developing keloids; and the coexistence of other allergic diseases further increases the risk.^{17,18} There are conflicting reports about an association between keloids and uterine fibroids.^{19,20} Keloids and osteoporosis may share a similar pathogenesis through chronic inflammation. Osteoporosis risk is higher in patients with keloids compared with controls, especially in young subjects and subjects without comorbidities.¹³ These findings suggest that keloids may be thought of as a cutaneous manifestation of systemic inflammation.

Pathophysiology/Genetics

The mechanisms behind keloid scarring are poorly understood and contribute to our inability to satisfactorily manage this abnormal scarring process.

Genetics—A genetic predisposition for keloid formation is the most relevant patient related factor in the development of keloids. Work in Asian and African-American populations have identified single-nucleotide polymorphisms (SNPs) associated with keloid formation.^{21–23} Additional studies have begun to unravel how these SNPs are associated with keloid formation.²⁴ Having a family member with keloids is associated with increased keloid prevalence.^{9–11} Most evidence points to an autosomal dominant pattern of inheritance with incomplete penetration and variable expression. So far, there is one gene that has been identified in a family with multiple generations affected by keloids. A rare variant in the N-acylsphingosine amidohydrolase 1, or *ASAH1*, segregates within the family. *ASAH1* is known to catalyze the degradation of ceramide into sphingosine and free fatty acid but its role in keloid pathogenesis remains unclear.²⁵ In addition to inherited gene mutations, epigenetic modifications may also play a role in keloid pathogenesis.¹²

Transforming growth factor beta 1—Transforming growth factor beta 1 (TGFβ1) is a secreted cytokine involved in proliferation, differentiation, migration, and apoptosis; it binds to its receptor and signal downstream through small/mothers against decapentaplegic homolog genes (SMADs), which function as intracellular mediators. Overproduction of TGFβ1, which occurs in keloids, has been associated with excessive deposition of scar tissue and fibrosis in the skin as well as in other organs. In contrast, TGFβ3 is present in high levels in embryonic skin—embryonic cutaneous wounds heal without scarring.²⁶

Hypoxia—Keloids histologically have large number of microvessels. Partial or total occlusion of these microvessels may contribute to a hypoxic microenvironment. This hypoxia is thought to lead to the upregulation of genes (such as Hypoxia Inducible Factor 1 Subunit Alpha [HIF1A]) and signals that lead to proliferation and fibrosis.

Mechanical stress: Tension and strain on wound edges are important extrinsic factors linked to hypertrophic scar and keloid development. Increased mechanical tension may lead to changes in gene expression within fibroblasts.²⁷

Hormones are thought to play a role because there is a higher incidence and tendency for keloids to enlarge after puberty and during pregnancy. Furthermore, tamoxifen is able to downregulate TGFβ1 expression in keloid fibroblasts in vitro.²⁸ Immunologically, there are increased number of macrophages, mast cells, and epidermal Langerhans cells present. T-lymphocytes and dendritic cells are found in keloids and hypertrophic scars, with evidence of Th2,

Th1, Th17/Th22, and JAK3 signaling in keloidal tissue.²⁹

Patient Evaluation and Clinical Findings

When evaluating a patient with keloids, a thorough history should be obtained from the patient. **Box 1** lists pertinent questions applicable to patients with keloids. Baseline photographs of the affected area(s) are important to evaluate the patient's condition at subsequent follow-up visits. Keloid patients will usually present with a history of local trauma or inflammation with subsequent development of a scar extending beyond the original boundary of the wound. The existence of "spontaneous keloids"—keloids that occur without any preceding trauma or inflammation—remains debated. The chest, shoulders, and back are the sites most likely to form keloids per trauma incurred, whereas the ears are the most common site for keloids to be observed. It is extremely rare to find keloids on the hands or feet, or on oral mucosa. Topographic factors that may influence keloid formation in genetically predisposed individuals include areas of increased skin tension during normal movement,^{30,31} increased sebaceous glands,^{32,33} increased collagen, and decreased macrophage numbers.³⁴ Keloids can be described as either superficial-spreading (flat) keloids or bulging (raised) keloids.¹ Superficial spreading keloids show irregular subepidermal spread with irregular areas of hyperpigmentation

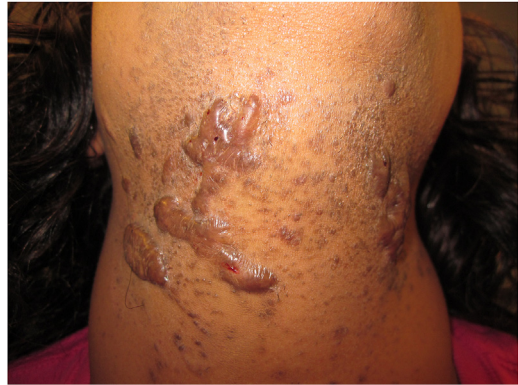

Fig. 1. Superficial spreading keloids on the submental region and neck.

and hypopigmentation (**Fig. 1**).¹ These lesions are often raised at the edges while the central aspect of the keloid is flattened and may represent a quiescent area. The central area may reflect the pigmentation of the surrounding skin, whereas the margins show hyperpigmentation and/or erythema. Bulging keloids are more pendulous or bulbous in shape and may have limited areas of central quiescence (**Fig. 2**). The growth pattern and the resulting shape may be predominately determined by local mechanical factors.³⁵

Keloids can be both painful and pruritic. Studies investigating the effect of keloids on patients' quality of life have noted keloids with itch in 66.7% to 95.0% of patients. Keloids were associated with pain in 46% to 53.3% of patients.^{36–38} Keloids can also be very sensitive to touch/pressure, making the wearing of a seat belt difficult for patients with chest keloids. Keloids/hypertrophic scars have been shown to affect patients' quality of life as significantly as psoriasis does.³⁹

Diagnosis Approach and Differential Diagnosis

Keloid scarring is primarily a clinical diagnosis. Keloids and hypertrophic scars can often be diagnosed by visual inspection and/or palpation. The first step in the Japan Scar Workshop diagnostic algorithm for keloids, hypertrophic scars, or mature scars is to determine which of the scars the lesion is likely to be.³ Benign skin tumors that resemble keloids and hypertrophic scars include dermatofibromas, neurofibromas and leiomyomas. Sinus histiocytosis with massive lymphadenopathy (Rosai-Dorfman syndrome) may also appear with keloidal-like plaques. Some malignant tumors, such as dermatofibrosarcoma protuberans (DFSP), may present with similar clinical

Box 1

Important questions to obtain when evaluating keloids/for keloid susceptibility

When did you first notice your keloid(s)?

Have you experienced itching, pain, burning in your scars?

Does pressure on your scars (eg, seatbelt over the chest) bother your scars?

Is there a family history of similar scars?

What treatment options have you previously tried for your keloids? Did they work at all? Did they work but then the keloids came back after treatments were stopped?

Do you have any of the following medical conditions?

Hypertension

Uterine fibroids

Atherosclerosis

Atopic Dermatitis

Osteoporosis

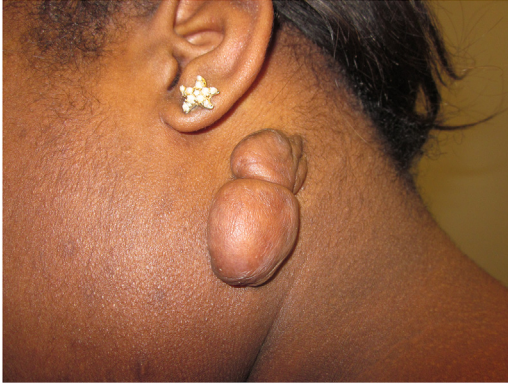

Fig. 2. Bulging keloid on the lateral neck.

features as keloids. Palpation around an atypical appearing keloid revealing focal areas of induration is suspicious for a DFSP and warrants a biopsy for further evaluation. If the patient endorses rapid growth of the lesion, a malignant tumor should be suspected.

Histopathological investigation can differentiate keloids from hypertrophic scars. In both keloids and hypertrophic scars, the epidermis and the papillary dermis can seem normal in structure. Hypertrophic scars are characterized by well-organized, wavy collagen bundles oriented parallel to epidermis surface. In contrast, keloids are characterized by disorganized, large, thick, hyalinized collagen bundles, with poor vascularization and widely scattered small dilated blood vessels.^{3,40} Dermoscopy of keloids and hypertrophic scars reveals vascular structures more commonly in keloids than in hypertrophic scars (90% and 27%, respectively). The dermoscopic

identification of vascular structures (arborizing, linear irregular or comma-shaped) can be a clinically useful tool to differentiate keloids from hypertrophic scars.⁴¹

Treatment

Prevention is better than cure. Patients with personal history (or family history) are discouraged from piercings, branding, or unnecessary surgeries. It is highly encouraged to pierce earlobes before puberty due to the hormonal contribution to keloid pathogenesis.⁴² Tattoos are also discouraged but seem less likely to induce keloids than the other aforementioned procedures. Surgical excision is the most definitive treatment option. However, surgery alone has a high recurrence rate (45%–100%), with the keloid often returning larger than the original scar.⁴³ Recurrences are also more likely to recur within the first 6 months after the surgical procedure. Therefore, a postsurgical treatment regimen started soon after surgery is necessary to decrease the likelihood for recurrence. These regimens are performed for at least 6 months, if not 1 full year, to minimize the recurrence risk.

Radiation therapy is often used in combination with surgical excision, especially if the keloid being excised is recurrent. Given within 72 hours of excision; 9 Gy to 16 Gy in 2 to 4 different fractions. Recurrence rates after excision with adjuvant radiation therapy range from 0% to 8.6%. Mechanism of action is not well known. The main side effects are dyspigmentation, dermatitis, and telangiectasias (**Fig. 3**).⁴⁴ A systematic review of 33 studies using radiation therapy (external beam or brachytherapy) as adjuvant

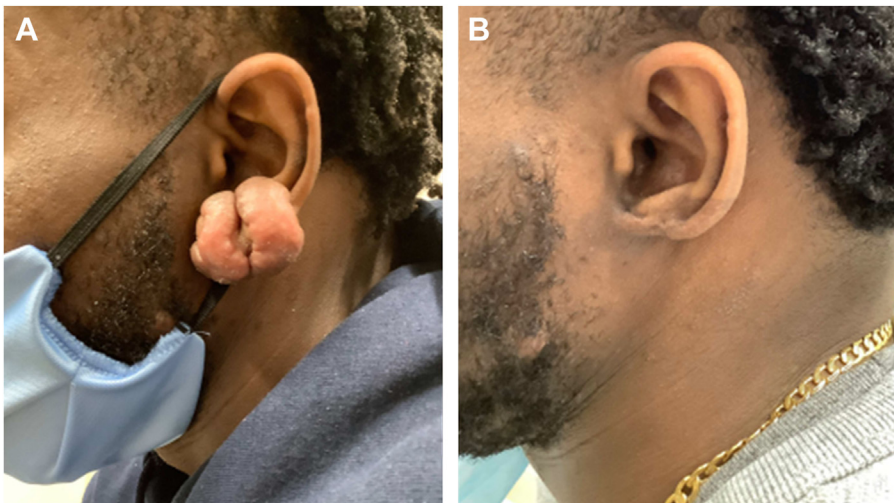

Fig. 3. Keloid before (A) and after (B) surgery with postoperative radiation therapy.

therapy postexcision of keloids found that the lowest recurrence rates were seen with high-dose radiation brachytherapy, then low-dose radiation brachytherapy and external beam radiation (10.5% vs 21.3% vs 22.2%, respectively). A shorter time interval (<7 hours) between excision and radiation resulted in lower recurrence (compared with >24 hours).⁴⁵

Silicone sheets are Food and Drug Administration (FDA)-approved for the treatment of keloids and hypertrophic scars. They are more effective in the postsurgical setting or on new hypertrophic scars and have minimal efficacy in treating already formed keloids.^{46,47} Silicone sheets should be worn over the surgical scar for 8 to 24 h/d for several months. Although the mechanism of action is unclear, it is thought to be secondary to occlusion and hydration.

Intralesional corticosteroids are FDA-approved for the treatment of keloids: they decrease collagen production, increase collagenase expression, and decrease inflammation (Fig. 4). Triamcinolone acetonide (10–40 mg/mL) injections are done every 4 to 6 weeks to treat formed keloids, with a maximum recommended dosage per visit is 80 mg. Response rates: 50% to 100%, with recurrence rates of 9% to 50%.⁴⁴ Side effects: pain, dyspigmentation, skin/fat atrophy, and telangiectasias.

Intralesional antineoplastic agents (5-fluorouracil [5-FU], bleomycin, vincristine). 5-FU 50 mg/mL once monthly to three times weekly. Less risk for skin atrophy and telangiectasias than intralesional

steroids; greater risk for hyperpigmentation and wound ulceration. Superior results when combined with corticosteroid injections.^{48,49} One combination regimen is a mixture of 1 part triamcinolone (40 mg/mL) to 9 parts 5-FU (50 mg/mL).

Flurandrenolide tape has been shown to flatten hypertrophic scars and thinly raised keloids. They are also effective in the postsurgical setting in the prevention of keloid occurrence.⁵⁰ They are worn over the scars for 8 to 24 h/d for 5 d/wk. Expect postinflammatory hypopigmentation of the surrounding normal skin; can also see skin atrophy, telangiectasias.

Cryotherapy works by cellular injury and necrosis of keloidal tissue. Side effects include local pain, blister formation, dyspigmentation, and depigmentation. Intralesional cryotherapy requires fewer treatments and has less risk for depigmentation than spray cryotherapy (Fig. 5).⁵¹

Mechanical compression has been used primarily to treat earlobe keloids but can be used in other locations. The mechanism of action is unknown but thought to be due to decreased oxygen tension from occlusion of smaller blood vessels or decreased mechanical tension.⁵² They can be used after surgery to decrease the chances of keloid formation. They are most effective if worn 24 h/d for several months at a pressure level of at least 24 mm Hg.⁵³

Various lasers have been used to treat keloids. Their proposed benefit is via selective photothermolysis, in which direct energy is absorbed by

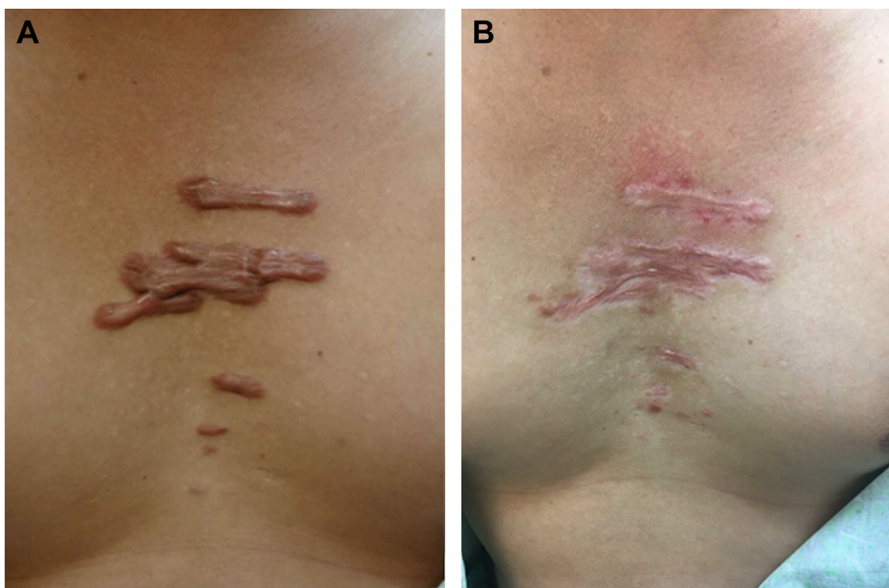

Fig. 4. Keloids before (A) and after (B) intralesional steroids.

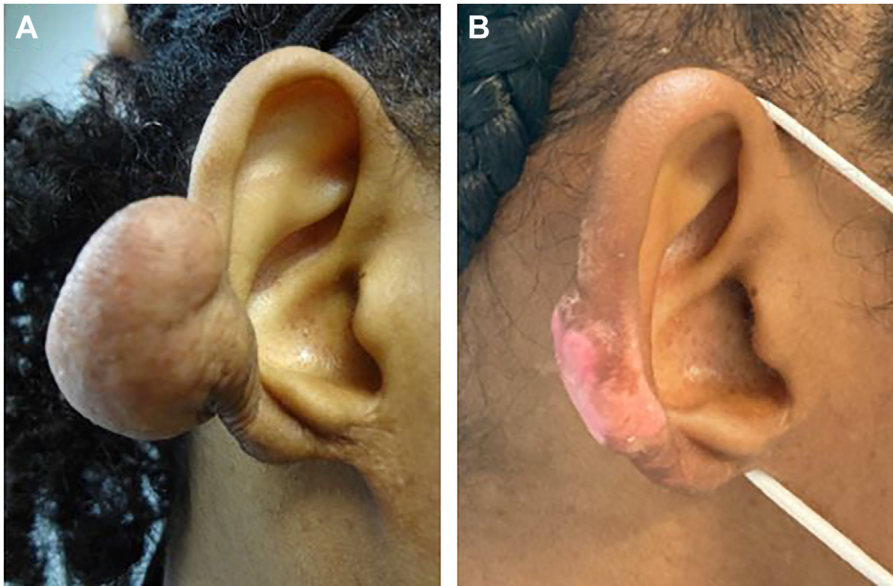


Fig. 5. Keloid before (A) and after (B) cryosurgery and intralesional steroids.

oxyhemoglobin, leading to thermal injury and reduced collagen. Multiple treatments are required for good outcome, and they may be used in combination with topical applications (steroids, 5-FU). Potential side effects include hyperpigmentation/hypopigmentation, scarring, and purpura. Options are 585 nm PDL, 1064 nm Nd:YAG, and CO₂ lasers.⁵⁴

Pentoxifylline is a xanthine derivative, known to improve erythrocyte flexibility and lower blood viscosity used to treat stroke, claudication, and sickle cell disease. It exerts a dose-dependent inhibition on the *in vitro* proliferation and collagen synthesis of human fibroblasts derived from normal skin and keloid tissue.⁵⁵ Tissue oxygen levels are significantly increased by therapeutic doses of pentoxifylline in patients with peripheral arterial disease. Wong and colleagues reports 3 patients with large keloidal plaques placed on pentoxifylline; they had substantial improvement in their pain and pruritus and lesional growth was halted.⁵⁶ A separate study has shown that pentoxifylline decreases the risk of postsurgical keloid recurrence.⁵⁷

Dupilumab has been proposed as a systemic treatment modality for keloids, given evidence for increased interleukin (IL)-4/IL-13 signaling and Th2 inflammation in keloid scars.⁵⁸ There are conflicting publications regarding efficacy of dupilumab for keloid growth as well as pain and itch.^{58–62} A clinical trial is underway to explore this modality.

Other treatment modalities include intralesional bleomycin, verapamil, hyaluronidase, collagenase,

botulinum toxin, radiofrequency ablation, and extracorporeal shockwave therapy.⁵⁴

Long-Term Monitoring

Because of the high rate of recurrence, a follow-up period of at least 1 year is necessary to fully evaluate the effectiveness of therapy. Close follow-up monitoring is vital during immediate and aggressive treatment of subsequent keloid formation. Noncompliant patients who are lost to follow-up care for months often return for further evaluation long after further adjunct treatment would have been most beneficial.

SUMMARY

Keloids remain a condition causing significant morbidity in patients, especially those of skin of color. With identification of its associations with other medical conditions and the inflammatory component to the disease, we are now beginning to understand some of the complexities of this disease process. Future research will hopefully identify more of the causal genes linked to keloids, as well as more of the systemic diseases that we should screen for in our patients diagnosed with CCCA. Future clinical studies should explore possible therapeutic options (local and systemic) that target the inflammatory and the fibroproliferative genes that are upregulated in keloids. As we learn more about keloids, we hope that future treatments will be able to prevent or reverse what has been thought to be an irreversible scarring process.

CLINICS CARE POINTS

- Keloids are an exuberant response to cutaneous wound healing in which scar tissue grows beyond the boundaries of the inciting insult.
- Age, race, location, family history, and personal history of keloids are relevant factors concerning the risk of developing keloids.
- Because keloids are prone to postexcisional recurrence, medical management plays an important role in keloid treatment.
- Many modalities exist to treat keloids/prevent recurrence.
- Multimodal approach is often necessary in difficult cases.

DECLARATION OF INTERESTS

Ariel Knowles has no conflicts of interest to declare. Donald Glass has served on advisory boards for AbbVie, Pfizer and UCB and has received honoraria as compensation.

REFERENCES

1. Limandjaja GC, Niessen FB, Scheper RJ, et al. The Keloid Disorder: Heterogeneity, Histopathology, Mechanisms and Models. *Front Cell Dev Biol* 2020; 8:360.
2. Ud-Din S, Bayat A. New insights on keloids, hypertrophic scars, and striae. *Dermatol Clin* 2014;32(2): 193–209.
3. Ogawa R, Akita S, Akaishi S, et al. Diagnosis and Treatment of Keloids and Hypertrophic Scars-Japan Scar Workshop Consensus Document 2018. *Burns Trauma* 2019;7:39.
4. Burd A, Huang L. Hypertrophic response and keloid diathesis: two very different forms of scar. *Plast Reconstr Surg* 2005;116(7):150e–7e.
5. Deyrup A, Graves JL Jr. Racial Biology and Medical Misconceptions. *N Engl J Med* 2022; 386(6):501–3.
6. Young WG, Worsham MJ, Joseph CL, et al. Incidence of keloid and risk factors following head and neck surgery. *JAMA Facial Plast Surg* 2014;16(5):379–80.
7. Tulandi T, Al-Sannan B, Akbar G, et al. Prospective study of intraabdominal adhesions among women of different races with or without keloids. *Am J Obstet Gynecol* 2011;204(2):132 e131–e134.
8. Bran GM, Goessler UR, Hormann K, et al. Keloids: current concepts of pathogenesis (review). *Int J Mol Med* 2009;24(3):283–93.
9. Kiprono SK, Chaula BM, Masenga JE, et al. Epidemiology of Keloids in Normally Pigmented Africans and African People With Albinism: Population-Based Cross Sectional Survey. *Br J Dermatol* 2015;173(3):852–4.
10. Bayat A, Arscott G, Ollier WE, et al. Keloid disease: clinical relevance of single versus multiple site scars. *Br J Plast Surg* 2005;58(1):28–37.
11. Lu WS, Zheng XD, Yao XH, et al. Clinical and epidemiological analysis of keloids in Chinese patients. *Arch Dermatol Res* 2015;307(2):109–14.
12. Glass DA 2nd. Current Understanding of the Genetic Causes of Keloid Formation. *J Investig Dermatol Symp Proc* 2017;18(2):S50–3.
13. Lu CC, Qin H, Zhang ZH, et al. The association between keloid and osteoporosis: real-world evidence. *BMC Musculoskelet Disord* 2021;22(1):39.
14. Arima J, Huang C, Rosner B, et al. Hypertension: a systemic key to understanding local keloid severity. *Wound Repair Regen* 2015;23(2):213–21.
15. Woolery-Lloyd H, Berman B. A controlled cohort study examining the onset of hypertension in black patients with keloids. *Eur J Dermatol* 2002;12(6): 581–2.
16. Rutherford A, Glass DA 2nd. A case-control study analyzing the association of keloids with hypertension and obesity. *Int J Dermatol* 2017;56(9):e187–9.
17. Lu YY, Lu CC, Yu WW, et al. Keloid risk in patients with atopic dermatitis: a nationwide retrospective cohort study in Taiwan. *BMJ Open* 2018;8(7): e022865.
18. Kwon HE, Ahn HJ, Jeong SJ, et al. The increased prevalence of keloids in atopic dermatitis patients with allergic comorbidities: a nationwide retrospective cohort study. *Sci Rep* 2021;11(1):23669.
19. Sun LM, Wang KH, Lee YC. Keloid incidence in Asian people and its comorbidity with other fibrosis-related diseases: a nationwide population-based study. *Arch Dermatol Res* 2014;306(9):803–8.
20. Harmon QE, Laughlin SK, Baird DD. Keloids and ultrasound detected fibroids in young African American women. *PLoS One* 2013;8(12):e84737.
21. Nakashima M, Chung S, Takahashi A, et al. A genome-wide association study identifies four susceptibility loci for keloid in the Japanese population. *Nat Genet* 2010;42(9):768–71.
22. Zhu F, Wu B, Li P, et al. Association study confirmed susceptibility loci with keloid in the Chinese Han population. *PLoS One* 2013;8(5):e62377.
23. Velez Edwards DR, Tsosie KS, Williams SM, et al. Admixture mapping identifies a locus at 15q21.2-22.3 associated with keloid formation in African Americans. *Hum Genet* 2014;133(12): 1513–23.
24. Fujita M, Yamamoto Y, Jiang JJ, et al. NEDD4 Is Involved in Inflammation Development during Keloid Formation. *J Invest Dermatol* 2019;139(2):333–41.

25. Santos-Cortez RLP, Hu Y, Sun F, et al. Identification of ASAH1 as a susceptibility gene for familial keloids. *Eur J Hum Genet* 2017;25(10):1155–61.
26. Beanes SR, Dang C, Soo C, et al. Skin repair and scar formation: the central role of TGF-beta. *Expet Rev Mol Med* 2003;5(8):1–22.
27. Harn HI, Ogawa R, Hsu CK, et al. The tension biology of wound healing. *Exp Dermatol* 2019;28(4):464–71.
28. Chau D, Mancoll JS, Lee S, et al. Tamoxifen downregulates TGF-beta production in keloid fibroblasts. *Ann Plast Surg* 1998;40(5):490–3.
29. Wu J, Del Duca E, Espino M, et al. RNA Sequencing Keloid Transcriptome Associates Keloids With Th2, Th1, Th17/Th22, and JAK3-Skewing. *Front Immunol* 2020;11:597741.
30. Bux S, Madaree A. Involvement of upper torso stress amplification, tissue compression and distortion in the pathogenesis of keloids. *Med Hypotheses* 2012;78(3):356–63.
31. Ogawa R, Okai K, Tokumura F, et al. The relationship between skin stretching/contraction and pathologic scarring: the important role of mechanical forces in keloid generation. *Wound Repair Regen* 2012;20(2):149–57.
32. Al-Attar A, Mess S, Thomassen JM, et al. Keloid pathogenesis and treatment. *Plast Reconstr Surg* 2006;117(1):286–300.
33. Fong EP, Bay BH. Keloids - the sebum hypothesis revisited. *Med Hypotheses* 2002;58(4):264–9.
34. Butzelaar L, Niessen FB, Talhout W, et al. Different properties of skin of different body sites: The root of keloid formation? *Wound Repair Regen* 2017;25(5):758–66.
35. Huang C, Liu L, You Z, et al. Keloid progression: a stiffness gap hypothesis. *Int Wound J* 2017;14(5):764–71.
36. Kouotou EA, Nansseu JR, Omona Guissana E, et al. Epidemiology and clinical features of keloids in Black Africans: a nested case-control study from Yaounde, Cameroon. *Int J Dermatol* 2019;58(10):1135–40.
37. Lee SS, Yosipovitch G, Chan YH, et al. Pruritus, pain, and small nerve fiber function in keloids: a controlled study. *J Am Acad Dermatol* 2004;51(6):1002–6.
38. Kassi K, Kouame K, Kouassi A, et al. Quality of life in black African patients with keloid scars. *Dermatol Reports* 2020;12(2):8312.
39. Balci DD, Inandi T, Dogramaci CA, et al. DLQI scores in patients with keloids and hypertrophic scars: a prospective case control study. *J Dtsch Dermatol Ges* 2009;7(8):688–92.
40. Gauglitz GG, Korting HC, Pavicic T, et al. Hypertrophic scarring and keloids: pathomechanisms and current and emerging treatment strategies. *Mol Med* 2011;17(1–2):113–25.
41. Yoo MG, Kim IH. Keloids and hypertrophic scars: characteristic vascular structures visualized by using dermoscopy. *Ann Dermatol* 2014;26(5):603–9.
42. Lane JE, Waller JL, Davis LS. Relationship between age of ear piercing and keloid formation. *Pediatrics* 2005;115(5):1312–4.
43. Butler PD, Longaker MT, Yang GP. Current progress in keloid research and treatment. *J Am Coll Surg* 2008;206(4):731–41.
44. Berman B, Maderal A, Raphael B. Keloids and Hypertrophic Scars: Pathophysiology, Classification, and Treatment. *Dermatol Surg* 2017;43(Suppl 1):S3–18.
45. van Leeuwen MC, Stokmans SC, Bulstra AE, et al. Surgical Excision with Adjuvant Irradiation for Treatment of Keloid Scars: A Systematic Review. *Plast Reconstr Surg Glob Open* 2015;3(7):e440.
46. Dockery GL, Nilson RZ. Treatment of hypertrophic and keloid scars with SILASTIC Gel Sheeting. *J Foot Ankle Surg* 1994;33(2):110–9.
47. O'Brien L, Jones DJ. Silicone gel sheeting for preventing and treating hypertrophic and keloid scars. *Cochrane Database Syst Rev* 2013;9:CD003826.
48. Asilian A, Darougheh A, Shariati F. New combination of triamcinolone, 5-Fluorouracil, and pulsed-dye laser for treatment of keloid and hypertrophic scars. *Dermatol Surg* 2006;32(7):907–15.
49. Srivastava S, Patil AN, Prakash C, et al. Comparison of Intralesional Triamcinolone Acetonide, 5-Fluorouracil, and Their Combination for the Treatment of Keloids. *Adv Wound Care* 2017;6(11):393–400.
50. Potter K, Konda S, Ren VZ, et al. Techniques for Optimizing Surgical Scars, Part 2: Hypertrophic Scars and Keloids. *Skinmed* 2017;15(6):451–6.
51. Mourad B, Elfar N, Elsheikh S. Spray versus intralesional cryotherapy for keloids. *J Dermatolog Treat* 2016;27(3):264–9.
52. Kelly AP. Medical and surgical therapies for keloids. *Dermatol Ther* 2004;17(2):212–8.
53. Niessen FB, Spauwen PH, Schalkwijk J, et al. On the nature of hypertrophic scars and keloids: a review. *Plast Reconstr Surg* 1999;104(5):1435–58.
54. Limmer EE, Glass DA 2nd. A Review of Current Keloid Management: Mainstay Monotherapies and Emerging Approaches. *Dermatology and Therapy* 2020;10(5):931–48.
55. Berman B, Duncan MR. Pentoxifylline inhibits the proliferation of human fibroblasts derived from keloid, scleroderma and morphea skin and their production of collagen, glycosaminoglycans and fibronectin. *Br J Dermatol* 1990;123(3):339–46.
56. Wong TW, Lee JY, Sheu HM, et al. Relief of pain and itch associated with keloids on treatment with ox-pentifylline. *Br J Dermatol* 1999;140(4):771–2.

57. Tan A, Martinez Luna O, Glass DA. 2nd. Pentoxifylline for the Prevention of Postsurgical Keloid Recurrence. *Dermatol Surg* 2020;46(10):1353–6.
58. Diaz A, Tan K, He H, et al. Keloid lesions show increased IL-4/IL-13 signaling and respond to Th2-targeting dupilumab therapy. *J Eur Acad Dermatol Venereol* 2019;34(4):e161–4.
59. Wong AJS, Song EJ. Dupilumab as an adjuvant treatment for keloid-associated symptoms. *JAAD Case Rep* 2021;13:73–4.
60. Tirgan MH, Uitto J. Lack of efficacy of dupilumab in the treatment of keloid disorder. *J Eur Acad Dermatol Venereol* 2022;36(2):e120–2.
61. Peterson DM, Damsky WE, Vesely MD. Treatment of lichen sclerosus and hypertrophic scars with dupilumab. *JAAD Case Rep* 2022;23:76–8.
62. Luk K, Fakhoury J, Ozog D. Nonresponse and Progression of Diffuse Keloids to Dupilumab Therapy. *J Drugs Dermatol JDD* 2022;21(2):197–9.