

# Revision Total Elbow Arthroplasty with the Semiconstrained Coonrad/Morrey Prosthesis

## Follow-up to 21 Years

Hugo Barret, MD, Pierre Laumonerie, MD, Stéphanie Delclaux, MD, Marine Arboucalot, MD, Nicolas Bonneville, MD, PhD, and Pierre Mansat, MD, PhD

*Investigation performed at the Service de Chirurgie Orthopédique et Traumatologique, Hôpital Pierre Paul Riquet, Toulouse, France*

**Background:** Revision total elbow arthroplasty (TEA) has increased, especially in young patients with high functional expectations. The objective of this study was to evaluate the long-term results of revision TEA with a single semiconstrained prosthesis.

**Methods:** Thirty-four revision TEAs were performed with a Coonrad/Morrey prosthesis in 32 patients; 2 patients had bilateral procedures. The mean patient age was 61 years (range, 22 to 76 years), and the revision TEA was performed at a mean time of 7.8 years (range, 1.6 to 21 years) after the primary TEA. Etiologies for revisions were humeral and ulnar aseptic loosening (n = 14), ulnar aseptic loosening (n = 8), humeral aseptic loosening (n = 6), septic arthritis (n = 4), and unstable unlinked prostheses (n = 2). Clinical and radiographic evaluations were performed with systematic preoperative infection workup and quantification of bone loss. The mean follow-up was 11.4 years (range, 2 to 21 years).

**Results:** The Mayo Elbow Performance Score (MEPS) at the last follow-up was excellent in 6 cases, good in 18 cases, fair in 8 cases, and poor in 2 cases, with a mean improvement (and standard deviation) between the preoperative values at  $42.4 \pm 16.1$  points and the postoperative values at  $81.8 \pm 12$  points ( $p < 0.001$ ). The mean pain scores improved significantly from  $6.7 \pm 1.3$  points preoperatively to  $1.4 \pm 1.4$  points postoperatively ( $p < 0.001$ ). The flexion-extension arc increased significantly ( $p = 0.02$ ) from  $74^\circ \pm 27^\circ$  preoperatively to  $100^\circ \pm 31^\circ$  postoperatively. The total number of complications was 29 in 19 revision TEAs (56%). Twenty of the 29 complications simply required monitoring without surgical intervention. Six repeat surgical procedures were required, and 3 implant revisions (9%) were performed.

**Conclusions:** Revision TEA with a semiconstrained prosthesis can provide good clinical results that can be maintained during follow-up. The rate of complications is high. Proper evaluation of the risk-benefit ratio is essential for each revision TEA and should be discussed with the patient.

**Level of Evidence:** Therapeutic Level IV. See Instructions for Authors for a complete description of levels of evidence.

The increase in the number of elbow arthroplasties during the 2000s<sup>1-3</sup> has led to an increase in the number of revisions, especially in young patients with high functional expectations<sup>4-6</sup>. A revision total elbow arthroplasty (TEA) is usually performed in the first decade following a primary TEA<sup>5,7</sup>. The main causes for the revision of a semi-constrained TEA are aseptic loosening of the components<sup>7-10</sup>, associated polyethylene wear<sup>11,12</sup>, and deep infections<sup>1,13</sup>. Other causes of revision are instabilities of unconstrained prostheses<sup>14</sup>, periprosthetic fractures<sup>15-17</sup>, and ulnar nerve involvement.

Revision TEA remains a challenging procedure<sup>18,19</sup>, especially in the case of bone loss. Clinically, soft-tissue status, triceps strength<sup>20</sup>, and nerve function should be considered. Results appear to be better if revisions are performed with semi-constrained prostheses<sup>5,11</sup>.

The objective of this investigation was to evaluate the long-term results of revision TEA with a single semiconstrained prosthesis (Coonrad/Morrey Total Elbow; Zimmer-BIOMET). Our hypothesis was that satisfactory results could be obtained after revision TEA and could be maintained over time.

**Disclosure:** The authors indicated that no external funding was received for any aspect of this work. The **Disclosure of Potential Conflicts of Interest** forms are provided with the online version of the article (<http://links.lww.com/JBJS/G356>).

## Materials and Methods

### Patients

A retrospective, single-center study was conducted. All patients who had revision TEA (humeral, ulnar, or 2-component) with a Coonrad/Morrey prosthesis with a minimum follow-up of 2 years were included. The patients were fully informed regarding the study and agreed to participate. This study was approved by the institutional review board at Toulouse University Hospital and ethic requirements were totally respected (registered as a retrospective study with Toulouse University Hospital number's register: RnIPH 2020-38) and covered by the MR-004 CNIL number 2206723 v 0.

Between 1996 and 2015, 34 revision TEAs (19.2% of the 177 TEAs performed during the time period of the study) were performed in 32 patients; 2 patients had bilateral procedures. Seven patients died of unrelated causes at a mean time of 5.9 years (range, 2.1 to 12.9 years) following the revision procedure. The results at the time of the last follow-up of these 7 patients were included.

TEA was initially indicated for rheumatoid arthritis (17 cases), posttraumatic conditions (12 cases), another inflammatory etiology (4 cases), and sequelae of osteosarcoma treatment (1 case). The TEA cases that underwent revision were 22 semiconstrained linked implants, 11 unlinked prostheses, and 1 constrained linked Dee prosthesis (Luer) (Table I). The mean period between the primary TEA and the revision TEA was 7.8 years (range, 1.6 to 21 years).

### Evaluation

All patients were assessed by an independent observer. Pain level was evaluated with a visual analog scale (VAS) of 0 to 10, with 0 indicating no pain and 10 indicating unbearable pain. Range of motion was measured with a goniometer. The Mayo Elbow Performance Score (MEPS)<sup>21</sup> and the Disabilities of the Arm, Shoulder and Hand (DASH) questionnaire<sup>22</sup> were assessed preoperatively and at the last follow-up. Clinical evaluation<sup>23,24</sup> was specifically focused on soft-tissue status and neurological examination. The skin was classified either as scarred (good quality) or as damaged (precarious and/or damaged and/or fragile). The neurological examination, using the British Medical Research Council (MRC) system<sup>25</sup>, identified signs of nerve dysfunction, especially in the ulnar and radial nerve distribution. The function of the triceps was analyzed by evaluating the force against gravity<sup>20,25</sup> (Table II).

Preoperatively, bone loss evaluated on radiographs was classified into 4 categories related to the joint line: no or minimal bone loss, <8-cm bone loss with intact cortical bone, <8-cm bone loss with thin cortical or periprosthetic fractures, and bone loss of  $\geq 8$  cm with a massive allograft-prosthesis composite (APC) (Table II); there was a fifth category,  $\geq 8$ -cm bone deficiency with a custom prosthesis, but no patient was categorized as such. Periprosthetic fractures were evaluated using the Mayo classification<sup>15,17</sup>. Radiographic evaluation was performed at the last follow-up to analyze radiolucent lines around the components according to the King classification<sup>26</sup> and to evaluate the wear of the bushings.

All patients had a preoperative assessment<sup>27</sup> to rule out any infection (i.e., a history and clinical signs of sepsis), a biologic evaluation (leukocytes, C-reactive protein, erythrocyte sedimentation rate), and a bone scan. Computed tomographic scans were performed to assess residual bone stock around the prosthesis<sup>28</sup>.

### Indications for Revision

Loosening of the components was the main cause of revision: humeral and ulnar aseptic loosening (14 cases), ulnar aseptic loosening (8 cases), and humeral aseptic loosening (6 cases). A revision was performed to treat septic arthritis in 4 cases. Two patients had a revision surgical procedure for instability of an unlinked prosthesis without loosening of the components.

### Surgical Technique

All patients were surgically treated by the senior author. A posterior approach was used (Table I). The ulnar nerve was systematically released and was anteriorly transposed if it had not been previously transposed. The radial nerve was systematically located and isolated in only 4 patients on account of the proximal extension of the dissection. Bacteriological samples (a minimum of 5 samples) were systematically taken and were retained for 21 days. Patients received antibiotic prophylaxis until bacteriological results were obtained. Three patients had positive cultures (*Staphylococcus aureus* or *Staphylococcus epidermidis*) requiring prolonged antibiotic therapy for 6 weeks after advice from the infectious diseases specialists.

### Extraction of the Implants

When the implants were not loosened or were impossible to extract after weakening the bone-cement interface with a small burr, a posterior bone window (n = 8) was created up to the end of the stem. The width of the bone window should be less than the humeral or ulnar diaphyseal diameter. Its length must be such that a length of 1 to 2 cortical diaphyseal diameters remains at the end of the ulnar or humeral stem (Fig. 1). As much cement as possible was removed in order to not interfere with the placement of the revision implant<sup>29</sup>. Fluoroscopic control was performed when reamers were used. An incorrect humeral path with fracture of the cortical bone was noted at the humerus in 4 cases and at the ulna in 6 cases.

### Revision Prosthesis

All patients underwent revision with a semiconstrained Coonrad/Morrey prosthesis. On the humeral side, 2 requirements had to be met. The stem had to be of sufficient length to bridge cortical defects and/or periprosthetic fractures. The length of the stem had to be long enough to ensure adequate joint stability and to withstand high constraints; 4-inch (10-cm) humeral components (15 cases), 6-inch (15-cm) components (15 cases), and 8-inch (20-cm) components (4 cases) were used.

When bone loss was substantial, the prosthesis had to be suspended so as not to shorten the upper limb by  $>2$  cm. To avoid stresses, the anterior flange on the humeral component

TABLE I Summary of Demographic Characteristics, Preoperative and Postoperative Prosthetic Features, and Complications for Each Case\*

Case	Sex	Age (yr)	Side		Initial Prosthesis	No. of Previous Surgeries	Approach	Components Revised	Humerotomy or Ulnarotomy	Length of Revision Prosthesis		Complications During Revision
			Involved	Dominant						Ulnar	Humeral	
1	F	55	L	N	GUEPAR 1	1	Bryan-Morrey	Both	N	Normal	6 inches (15 cm)	None
2	M	73	R	Y	Souter-Strathclyde	1	Bryan-Morrey	Both	N	Normal	4 inches (10 cm)	Radial nerve palsy with exploration and weakness of the triceps
3	F	22	R	Y	GUEPAR 1	1	Bryan-Morrey	Both	N	Normal	4 inches (10 cm)	Repeat debridement associated with antibiotic therapy for acute infection
4	M	68	L	Y	Coonrad/Morrey	2	Gschwend	Ulnar	Ulnarotomy	Extra-long	6 inches (15 cm)	None
5	F	61	L	N	GUEPAR 1	1	Bryan-Morrey	Both	N	Normal	4 inches (10 cm)	ORIF of Mayo type-II humeral periprosthetic fracture and weakness of the triceps
6	F	61	R	Y	Coonrad/Morrey	5	Bryan-Morrey	Both	N	Normal	6 inches (15 cm)	Mayo type-I humeral periprosthetic fracture
7	F	76	R	Y	Ewald	1	Bryan-Morrey	Both	N	Normal	4 inches (10 cm)	Wound dehiscence and ulnar nerve neurapraxia
8	F	67	R	Y	iBP	1	Bryan-Morrey	Both	N	Normal	4 inches (10 cm)	Ulnar nerve neurapraxia and heterotopic ossifications
9	F	68	L	N	GUEPAR 1	1	Bryan-Morrey	Humeral	N	Normal	4 inches (10 cm)	None
10	M	67	R	Y	Coonrad/Morrey	1	Bryan-Morrey	Both	N	Normal	6 inches (15 cm) expanded AF	None
11	F	76	L	N	Coonrad/Morrey	2	Bryan-Morrey	Ulnar	N	Normal	4 inches (10 cm)	Radial neurapraxia and heterotopic ossifications
12	F	73	R	Y	GSB III	3	Bryan-Morrey	Both	N	Extra-long	4 inches (10 cm)	None
13	M	76	L	N	Coonrad/Morrey	1	Bryan-Morrey	Humeral	Humerotomy	Normal	8 inches (20 cm) expanded AF	None
14	F	69	L	N	Coonrad/Morrey	2	Bryan-Morrey	Humeral	Humerotomy	Normal	6 inches (15 cm) expanded AF	None
15	F	54	L	N	Ewald	1	Bryan-Morrey	Both	N	Extra-long	4 inches (10 cm)	Radial neurapraxia and heterotopic ossifications
16	M	74	R	Y	GSB III	2	Bryan-Morrey	Both	N	Normal	6 inches (15 cm)	Mayo type-III humeral periprosthetic fracture and weakness of the triceps
17	F	76	L	N	Coonrad/Morrey	1	Gschwend	Both	Ulnarotomy	Normal	6 inches (15 cm)	None
18	F	64	R	Y	Coonrad/Morrey	1	Bryan-Morrey	Ulnar	N	Normal	4 inches (10 cm)	None
19	F	35	R	Y	Coonrad/Morrey	1	Bryan-Morrey	Ulnar	N	Normal	4 inches (10 cm)	None
20	F	33	L	N	Coonrad/Morrey	1	Bryan-Morrey	Ulnar	Ulnarotomy	Normal	4 inches (10 cm)	None
21	F	73	L	N	Coonrad/Morrey	1	Bryan-Morrey	Ulnar	N	Normal	4 inches (10 cm)	None
22	F	51	R	Y	Coonrad/Morrey	3	Gschwend	Ulnar	Ulnarotomy	Extra-long	6 inches (15 cm)	None
23	F	51	L	N	GSB III	1	Bryan-Morrey	Humeral	N	Normal	6 inches (15 cm)	None

continued

TABLE I (continued)

Case	Sex	Age (yr)	Side		Initial Prosthesis	No. of Previous Surgeries	Approach	Components Revised	Humerotomy or Ulnarotomy	Length of Revision Prosthesis		Complications During Revision
			Involved	Dominant						Ulnar	Humeral	
24	M	50	R	Y	Coonrad/Morrey	1	Bryan-Morrey	Both	Humerotomy	Normal	6 inches (15 cm)	Weakness of the triceps and radial neurapraxia
25	F	75	L	N	Coonrad/Morrey	3	Bryan-Morrey	Both	N	Extra-long	8 inches (20 cm) expanded AF	Evacuation of an early hematoma and ulnar neurapraxia
26	F	66	R	Y	Coonrad/Morrey	2	Bryan-Morrey	Humeral	N	Normal	6 inches (15 cm) expanded AF	None
27	M	57	L	N	Dee	1	Bryan-Morrey	Both	N	Normal	6 inches (15-cm)	ORIF of Mayo type-III ulnar periprosthetic fracture and revision (resection) for sepsis
28	F	68	R	Y	GUEPAR 1	1	Bryan-Morrey	Both	N	Normal	8 inches (20 cm)	Mayo type-III humeral periprosthetic fracture
29	F	63	R	Y	Kudo	1	Gschwend	Humeral	Humerotomy	Extra-long	6 inches (15 cm) expanded AF	Repeat debridement associated with suppressive antibiotic therapy for infection
30	F	61	L	N	Kudo	1	Gschwend	Humeral	Humerotomy	Extra-long	6 inches (15 cm) expanded AF	Revision for early aseptic humeral loosening
31	F	52	L	N	Coonrad/Morrey	2	Bryan-Morrey	Both	N	Normal	6 inches (15 cm) expanded AF	Wound dehiscence
32	M	70	L	N	Coonrad/Morrey	1	Bryan-Morrey	Ulnar	N	Normal	4 inches (10 cm)	Radial nerve neurapraxia
33	M	49	L	N	Coonrad/Morrey	2	Gschwend	Both	N	Extra-long	8 inches (20 cm) expanded AF	Mayo type-III ulnar periprosthetic fracture and ulnar neurapraxia
34	M	48	L	N	GBS III	2	Bryan-Morrey	Both	N	Normal	4 inches (10-cm)	Revision (resection) for sepsis
Total	24 female and 10 male	61 (range, 22 to 76 yr)	15 right and 19 left	47%	18 Coonrad/Morrey, 4 GSB III, 5 GUEPAR, 1 Souter-Strathclyde, 2 Ewald, 2 Kudo, 1 iBP, 1 Dee prosthesis	1.52	6 Gschwend and 28 Bryan-Morrey	20 both, 8 ulnar, 6 humeral	5 humerotomies and 4 ulnarotomies	26 normal and 8 extra-long	4 inches (10 cm) in 6 patients, 6 inches (15 cm) in 15 patients, and 8 inches (20 cm) in 4 patients	29 complications in 19 revision TEAs, 3 revisions, and 6 reoperations

\*AF = expanded anterior flinch, and ORIF = open reduction and internal fixation.

was lengthened in 9 patients with a long stem (6-inch [15-cm] or 8-inch [20-cm] length).

To insert the humeral implant, the elbow was placed in 90° of flexion and traction on the arm was performed so that the flexor and extensor muscles were in adequate tension.

For optimal stress control, a bone graft was placed between the anterior flange and the anterior cortex in 18 cases.

On the ulnar side, the same requirements had to be met. A standard-length component (26 cases) or a long stem (8 cases) was used.

When bone loss was too great at the diaphyseal level, the implant was reinforced by an autograft or an allograft. When the

loss of bone was <8 cm at the humerus, a cortical graft was preferred. Two patients received a cortical graft to reinforce the bone around the prosthesis. Four massive humeral allografts (Fig. 2) were implanted as an APC because the bone loss was >8 cm<sup>18,28</sup>.

The triceps tendon was always repaired using the technique described by Bryan and Morrey<sup>30</sup>.

#### Postoperative Care

Patients were immobilized with an anterior extension brace for 2 days, and then a sling was used for 3 weeks. In the 4 cases with an APC, immobilization in flexion of 90° was indicated for 3 weeks, followed by a sling for 3 more weeks.

TABLE II Preoperative Clinical and Radiographic Data

	No. of Cases
Skin	
Cicatricial	29 (85%)
Damaged	5 (15%)
Ulnar nerve	
Normal	29 (85%)
Paresthesia	5 (15%)
Radial nerve	
Normal	34 (100%)
Paresthesia	0 (0%)
Triceps	
Capacity to extend against gravity	30 (88%)
No capacity to extend against gravity	4 (12%)
Bushing wear*	
None	23 (68%)
Partial	8 (24%)
Total	3 (9%)
Bone loss and treatment†	
Minimal	10 (29%)
Bone deficiency <8 cm + intact cortical bone = anterior graft	18 (53%)
Bone deficiency <8-cm bone loss with thin cortical or periprosthetic fractures	2 (6%)
Bone deficiency ≥8 cm = massive APC	4 (12%)
Bone deficiency ≥8 cm = custom prosthesis	0 (0%)

\*Wear of the polyethylene bushings in the prosthetic hinge was determined by anteroposterior radiography of the elbow; an absence of bushing wear was considered to exist when the angle of the ulnar implant in relation to the humeral implant was <3.5°, wear was considered partial for an angle of up to 5°, and total wear was considered to exist for an angle of >5° on stress radiographs. †Radiographic evaluation of the amount of bone loss.

### Statistical Analysis

The means and standard deviations were calculated for continuous variables. Quantitative variables (MEPS, DASH score, mobilities, and pain) were analyzed by the Mann-Whitney and Wilcoxon tests. The chi-square and Fisher tests were used to compare categorical variables (triceps integrity). Significance was set at  $p < 0.05$ . The survival rate, and accompanying 95% confidence interval, was analyzed according to the Kaplan-Meier method, with revision due to any cause considered as the end point. XLstat (addinsoft) software was used.

### Results

The mean follow-up was 11.4 years (range, 2 to 21 years).

#### Overall Results

The MEPS was excellent in 6 cases, good in 18 cases, fair in 8 cases, and poor in 2 cases (Table III). Upper-limb function also

improved, with a mean DASH score of  $71.1 \pm 17.2$  preoperatively and  $41.9 \pm 20.5$  postoperatively ( $p < 0.001$ ).

#### Clinical Results

Pain scores improved. Range of motion also improved, especially in flexion-extension, from  $74^\circ \pm 27^\circ$  preoperatively to  $100^\circ \pm 31^\circ$  postoperatively ( $p = 0.02$ ) (Table III). Triceps strength was unchanged between preoperative and postoperative evaluations except in 4 cases.

#### Radiographic Outcomes

Radiolucent lines were observed around the humeral component in 12 cases and around the ulnar component in 3 cases. On the humeral side, 7 patients had radiolucent lines in 1 or more areas. Only 2 patients had radiolucent lines around both humeral and ulnar components. Of the 4 APCs and 2 cortical grafts, nonunion between the graft and the host bone was evident in 2 cases.

#### Complications and Revisions

Twenty-nine complications were detected in 19 revision TEAs (56%), with no difference between patients with rheumatoid arthritis and those with posttraumatic arthritis (Table IV). Revision (Fig. 3) was performed in 3 cases (9%). Two patients underwent revision for sepsis and were treated with implant removal. One patient had a humeral implant replaced with a massive allograft for early aseptic loosening. At 10 years of follow-up, the survival rate of revision TEA according to the Kaplan-Meier curve was 87%.

Twenty of 29 complications required monitoring without surgical intervention, either because of a good prognosis or because of the patient's comorbidities. These included ulnar neurapraxia (4 cases), radial neurapraxia (4 cases), heterotopic ossifications (3 cases), weakness of the triceps with loss of active elbow extension (impossible to maintain active extension against gravity, 4 cases), 3 humeral periprosthetic fractures (1 Mayo type I and 2 Mayo type III), and 1 Mayo type-III ulnar fracture treated conservatively. There were 2 wound dehiscences, which were treated medically (i.e., delayed wound-healing treated by local care and targeted antibiotics for *S. aureus* and *S. epidermidis*).

Six repeat surgical procedures were required: repeat debridement associated with antibiotic therapy for 2 acute infections. One infection was treated with suppressive antibiotics without implant revision (*S. epidermidis* and *Escherichia coli* were found in this patient with prostatitis and comorbidities). After several irrigation and debridement failures, a suppressive antibiotic treatment was decided on collegially with the infectious diseases specialists with dual therapy (betalactamines and fluoroquinolones) for 6 weeks followed by monotherapy (betalactamines) for the long term without a persistent draining wound. One evacuation of an early hematoma in 1 patient on anticoagulant therapy and 1 radial nerve exploration in 1 patient with radial nerve palsy and no sign of clinical and electromyographic recovery were necessary. Open reduction and internal fixation was performed with a locking plate for 2 periprosthetic fractures distal to the stem without component instability: 1 humeral Mayo type-II fracture (Fig. 4) and 1 ulnar Mayo type-III fracture (Fig. 5).

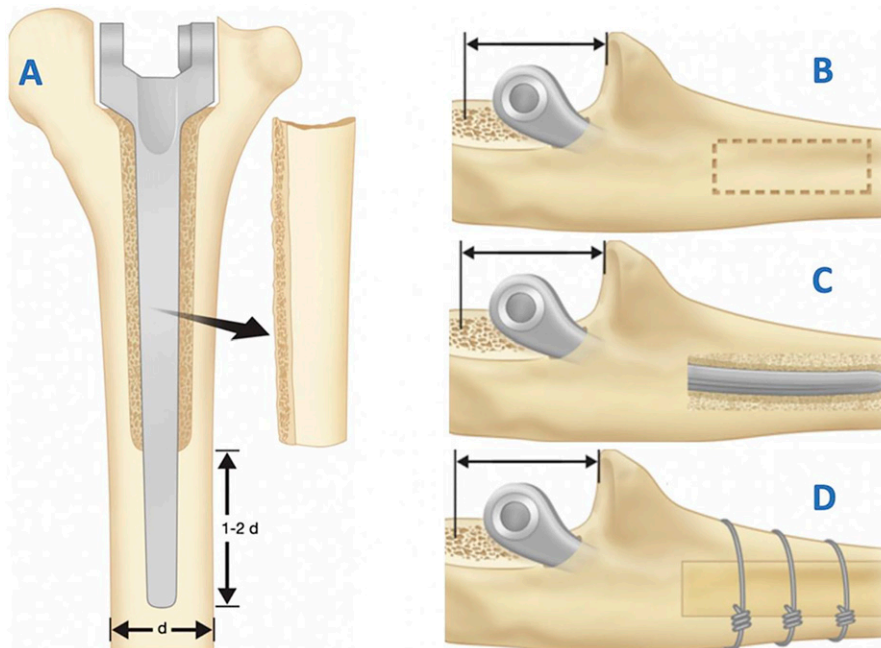


Fig. 1  
**Figs. 1-A through 1-D** Diagram of a humeral and ulnar bone window. Posterior humeral window (**Fig. 1-A**) and lateral ulnar window (the location of which is denoted by the dashed-line box) (**Fig. 1-B**) for access to the ulnar implant (**Fig. 1-C**), and repositioning of the bone window stabilized by cerclage (**Fig. 1-D**). (From: Mansat P, Bonneville N. Révision des prothèses totales de coude. EMC-Techniques chirurgicales-Orthopédie-Traumatologie. 2015 Aug 1:1-13 [Article 44-339], Elsevier-Masson. French.)

### Discussion

Clinical results improved after revision TEA with the Coonrad/Morrey prosthesis and seemed to be maintained at up to 21 years of follow-up. The complication rate was high, with complications after 56% of the revision TEAs, 6 repeat surgical procedures,

and 3 component revisions. Sixty-five percent of the patients had satisfactory clinical results, which was consistent with the literature<sup>26,31,32</sup>. Prosthetic survival without revision was 87% at 10 years.

In our series, 69% (20 of 29) of the complications were treated without a surgical procedure, with favorable results in

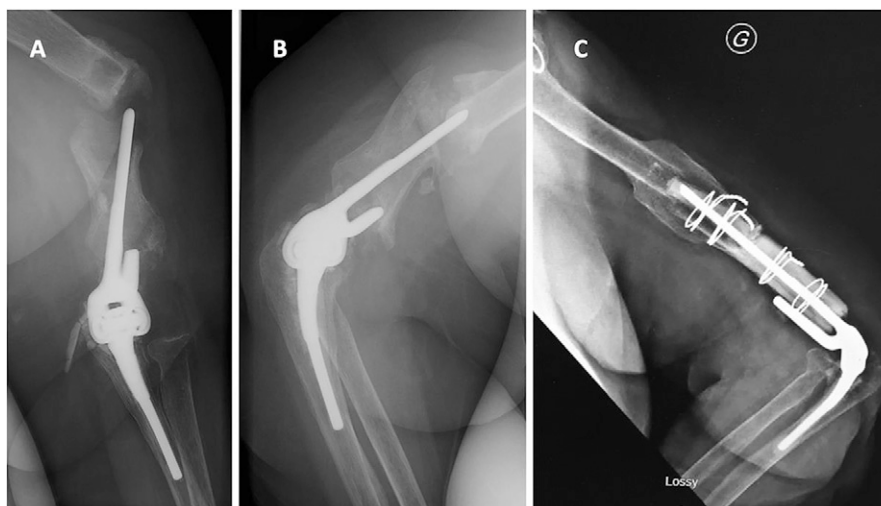


Fig. 2  
**Figs. 2-A, 2-B, and 2-C** Radiographic results of a massive humeral allograft for a 60-year-old patient who underwent an operation for a total elbow prosthesis with posttraumatic sequelae. **Figs. 2-A and 2-B** Seven years after the initial arthroplasty, a periprosthetic fracture with humeral component loosening was observed: anteroposterior view (**Fig. 2-A**) and lateral view (**Fig. 2-B**). **Fig. 2-C** The 10-year results of an APC: the allograft was perfectly healed, and there was no evidence of prosthetic loosening.

**TABLE III Clinical Results and Functional Scores at the Time of Follow-up**

	Preoperative Values*	Postoperative Values*	Difference	P Value
VAS (points)	6.7 ± 1.3	1.4 ± 1.4	5.3	<0.001
Flexion (deg)	114 ± 25	122 ± 28.2	8	0.22
Extension (deg)	40 ± 28	32 ± 33.5	8	0.41
Flexion-extension arc (deg)	74 ± 27	100 ± 31	26	0.02
Pronation (deg)	61 ± 18	65 ± 22.8	4	0.34
Supination (deg)	61 ± 20	65 ± 18.8	4	0.34
Pronation-supination arc (deg)	122 ± 19	130 ± 20	8	0.23
Triceps strength† (MRC grade)	2.9 ± 1.2	3.3 ± 1.3	0.4	0.76
Total MEPS (points)	42.4 ± 16.1	81.8 ± 12	39.6	<0.001
Pain MEPS (points)	12 ± 6.8	37 ± 7.4	25	<0.001
Mobility MEPS (points)	13.9 ± 6.8	17.3 ± 3.9	3.4	0.016
Stability MEPS (points)	4.4 ± 3.8	9.6 ± 1.9	5.2	<0.001
Function MEPS (points)	11.7 ± 6.3	18.5 ± 4.1	6.8	<0.001
DASH (points)	71.1 ± 17.2	41.9 ± 20.5	29.2	<0.001

\*The values are given as the mean and the standard deviation. †Triceps strength was assessed clinically on a scale from 0 to 5 according to the British Medical Research Council (MRC) System (0 = no muscle contraction; 1 = muscle contraction without movement; 2 = movement in the plane of the bed; 3 = movement against gravity; 4 = movement against resistance; and 5 = normal muscle strength).

the majority of cases. The most frequent complication was infection, a common complication after revision TEA<sup>7</sup>. Various therapeutic options are available to treat an infection following

TEA<sup>33,34</sup>. The choice depends on the time that the infection presents, the bacteria isolated, whether or not the implant is loose, and the patient's comorbidities. In our series, 2 patients

**TABLE IV Complications at the Time of Follow-up and Type of Treatment**

Complication	No. of Complications (N = 29)	Treatment (No. of Patients)	Results
Sepsis	4	Irrigation, debridement, and suppressive antibiotics (1); irrigation, debridement, and antibiotics (1), joint resection (2)	Results of medical treatment with long-term antibiotics were stable, with a painless elbow with or without a fistula; joint resections yielded a painless, unstable, and functional elbow
Radial nerve injury	4	Observation (3) and neurolysis (1)	Satisfactory clinical evolution except for the patient with neurolysis and radial nerve palsy
Ulnar nerve injury	4	Observation	Satisfactory clinical evolution despite persistent paresthesia
Humeral fracture	4	Conservative treatment (3) and open reduction and internal fixation (1)	Satisfactory clinical evolution for conservative and surgical treatment
Triceps tear	4	Observation	Functional impairment, in particular for movements above the head and requiring resistance: mean score of 63 points for MEPS and 63 points for DASH
Ulnar fracture	2	Conservative treatment (1) and open reduction and internal fixation (1)	Satisfactory clinical evolution for conservative treatment; failure of open reduction and internal fixation with postoperative infection and joint resection
Wound dehiscence	2	Local treatment	Satisfactory clinical evolution
Heterotopic ossifications	3	Observation	Satisfactory clinical evolution
Early aseptic loosening	1	Revision of humeral implant and massive humeral allograft	Satisfactory evolution at the last follow-up (3 years); stable elbow, 2 points for VAS, 70 points for MEPS, and 52 points for DASH
Hematoma	1	Surgical evacuation	Satisfactory clinical evolution

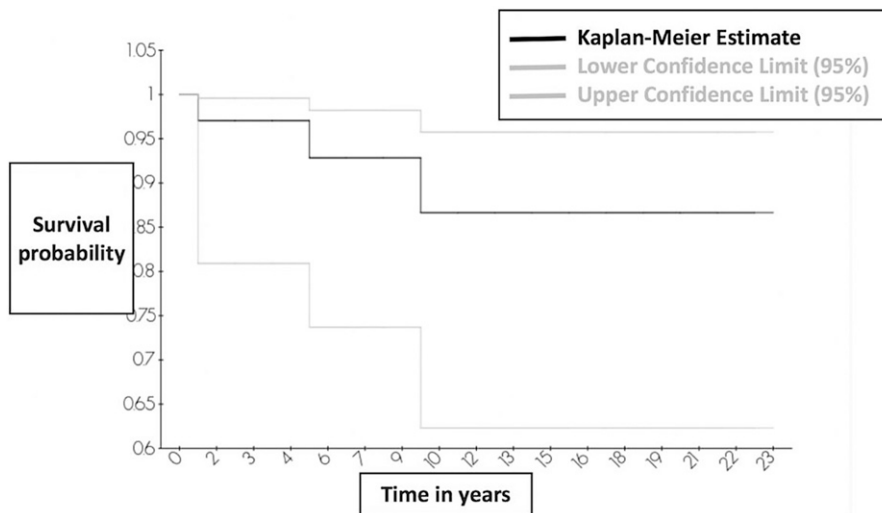


Fig. 3  
Revision-free survival curve.

had had several previous surgical procedures and we decided to remove the prosthesis and leave the patients with a joint resection by using only a splint for a short postoperative period.

Four patients (13%) presented with postoperative radial nerve lesions that may have been related to extensive exposure and intraoperative incorrect humeral passage ( $n = 4$ ). This rate of radial nerve damage is consistent with other studies (6% to 13%<sup>25,31,35</sup>). A majority of patients recovered spontaneously (3 of 4 in our series). Recovery prognosis was related to the cause of the radial nerve injury<sup>36</sup>. Two stages of the

procedure placed the nerve at risk: the approach and preparation of the humerus. During the approach, we advise surgeons to systematically locate the radial nerve at the posterior or lateral surface of the humerus through a transtricipital or laterotricipital window<sup>36</sup>. This proximal counter-incision should be made in the area at high risk for radial nerve damage; the landmark is approximately 14 cm above the olecranon fossa<sup>36</sup>. When preparing the humerus, the old cement can be left in place if it does not interfere with the placement of a new implant. We recommend great care when using ultrasonic and/or motorized instruments to remove

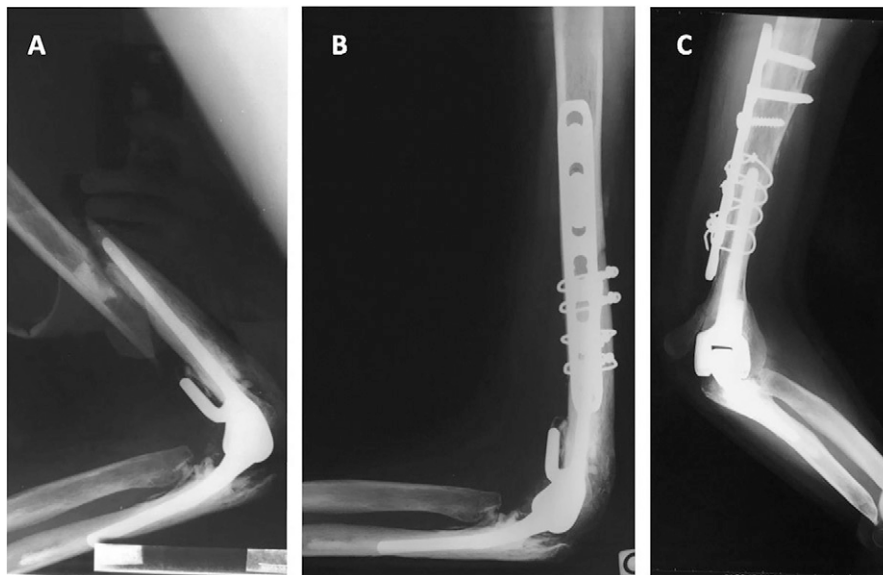


Fig. 4  
**Figs. 4-A, 4-B, and 4-C** Open reduction and internal fixation of a periprosthetic fracture at 9 years after a revision TEA in a 67-year-old patient with rheumatoid arthritis. **Fig. 4-A** Mayo type-II humeral fracture without prosthetic loosening. **Fig. 4-B** Open reduction and internal fixation with a locking plate. **Fig. 4-C** Healing of the fracture at 12 years after revision TEA with no evidence of bipolar loosening.



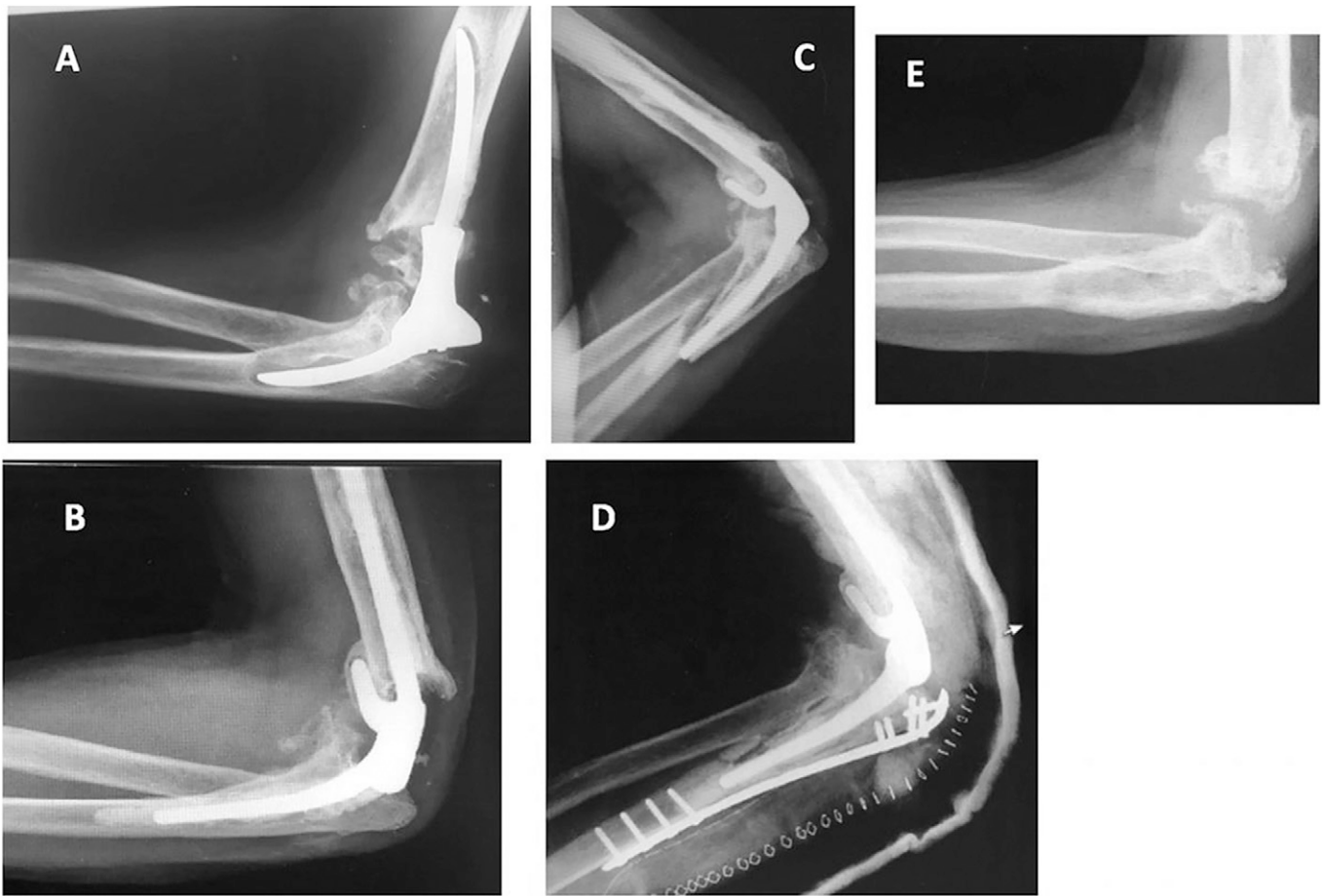


Fig. 5

**Figs. 5-A through 5-E** Resection arthroplasty following a periprosthetic fracture (after revision TEA) treated with plate open reduction and internal fixation and development of early sepsis. Elbow prosthesis (Dee) traumatic sequelae. **Fig. 5-A** Aseptic loosening in a 59-year-old patient. **Fig. 5-B** Revision TEA with a Coonrad/Morrey prosthesis; satisfactory radiographic and clinical evolution. **Fig. 5-C** A Mayo type-III ulnar periprosthetic fracture without prosthetic loosening. **Fig. 5-D** Open reduction and internal fixation. **Fig. 5-E** A fistula with sepsis, resulting in a decision for a resection arthroplasty.

cement with fluoroscopic control. The instrumentation must be adapted: 4 to 5-mm miniature drill bits on high-speed drills and/or 4-mm reamers on guide rods. Four cases (12%) of ulnar nerve involvement were observed, which is similar to the findings of other studies (13% to 20%)<sup>25,31,35</sup>. Triceps insufficiency was noted in 4 cases, despite triceps repair. All of these patients had undergone at least 1 surgical procedure through the triceps tendon before revision TEA, which could explain a certain weakness of the triceps tendon. This functional deficiency may be due to an injury of the triceps or fibrosis around the muscle and/or capsule. All patients with triceps weakness reported some functional impairment. No repeat surgical procedure was performed for triceps repair. Special attention must be paid to the management of the triceps intraoperatively. A bone pellet encountered during the approach on the triceps allowed possibly better consolidation with transosseous nonresorbable sutures due to bone-to-bone contact. Postoperatively, the tricital repair was protected and active extension against resistance was limited for 6 weeks.

Bearing surface wear is a typical complication observed with the Coonrad/Morrey prosthesis<sup>2,12</sup>. We found only 3 patients with signs of wear during follow-up. The low physical demand of our patients with moderate wear could explain this result.

A bone loss analysis should be performed systematically in the preoperative period to allow the surgeon to decide which strategy is needed<sup>15-18,27,28,37</sup>. If the bone is in continuity without a periprosthetic fracture, a prosthesis with a long stem can be sufficient. In the case of cortical expansion around a loose implant, bone augmentation can be used with impaction bone-grafting<sup>37</sup> or an externally applied strut graft<sup>15,16</sup>. In the case of a periprosthetic fracture without bone loss, strut grafts are usually recommended around a long-stem implant<sup>15,16</sup>. If there is a loss of <8 cm of bone stock, it can be compensated for with a long-stemmed prosthesis with an expanded anterior flange, with only 2 cm of the 5 cm of the flange being in contact with the anterior humeral cortex. With >8 cm of bone stock loss, an APC is an option<sup>18,28</sup>. In our series, 18% of the patients had substantial loss of bone stock, which explains the use of

allografts or cortical bone autografts in 15% of the cases. According to the literature, a greater preoperative amount of bone loss is correlated with a higher risk of postoperative revision<sup>31</sup>. Series with high preoperative rates of bone defects have revision rates between 17% and 27%<sup>32,35</sup>. Those studies used the same semi-constrained prosthesis with a great choice of implant lengths. In no case was a custom implant needed. Our series had a longer follow-up and only a 9% revision rate was observed, which could be explained by a better preoperative bone stock evaluation, the use of an adaptable prosthesis, and a rigorous procedure to address the problems. An annual follow-up of patients with primary TEA has allowed implant loosening to be detected early and a revision procedure to be proposed before bone loss is too extensive.

There were limitations to this study. The study spread over a period of 20 years, and the resulting changes in practice may have prevented some results from reaching significance. Other results may have failed to reach significance because of the small sample size. This was a retrospective study, and not all of the possible reconstructive options were used. The bone impaction technique<sup>37</sup> presents risks of fractures and infection and demands caution. In the case of major bone loss, an allograft was chosen over a custom-made prosthesis<sup>18,28</sup>. In the case of infection with removal of the prosthesis, resection arthroplasties were chosen<sup>33,34</sup> over other options such as arthrodesis<sup>38,39</sup>, as the degree of bone loss would have resulted in a high risk of nonunion. Functional results after elbow arthrodesis were also poor. There was selection bias in the choice of patients. Indications for a revision surgical procedure were determined on specific criteria that were based on >20 years of surgical experience. Only 1 surgeon performed the surgical procedure on all patients, which led to an expertise bias.

The strengths of this series are the relatively large number of patients and the long-term follow-up. This study was conducted in a high-volume elbow arthroplasty center with a senior surgeon with extensive experience in this type of surgical procedure.

In conclusion, revision TEA was able to provide satisfactory clinical results that could be maintained during follow-up. There was a high rate of complications, which, in a certain number of cases, required a revision surgical procedure. Pre-operative planning involving ruling out infection, evaluating the cause of failure, and identifying the type of prosthesis to be removed and the remaining bone stock was a prerequisite for success. ■

Hugo Barret, MD<sup>1</sup>  
Pierre Laumonerie, MD<sup>1</sup>  
Stéphanie Delclaux, MD<sup>1</sup>  
Marine Arboucalot, MD<sup>1</sup>  
Nicolas Bonneville, MD, PhD<sup>1</sup>  
Pierre Mansat, MD, PhD<sup>1</sup>

<sup>1</sup>Service de Chirurgie Orthopédique et Traumatologique, Hôpital Pierre Paul Riquet, Toulouse, France

Email address for H. Barret: hugobarret89@gmail.com

ORCID iD for H. Barret: [0000-0002-2243-8260](https://orcid.org/0000-0002-2243-8260)  
ORCID iD for P. Laumonerie: [0000-0002-3019-9861](https://orcid.org/0000-0002-3019-9861)  
ORCID iD for S. Delclaux: [0000-0001-5063-419X](https://orcid.org/0000-0001-5063-419X)  
ORCID iD for M. Arboucalot: [0000-0001-6147-5745](https://orcid.org/0000-0001-6147-5745)  
ORCID iD for N. Bonneville: [0000-0002-3482-9867](https://orcid.org/0000-0002-3482-9867)  
ORCID iD for P. Mansat: [0000-0002-2333-0366](https://orcid.org/0000-0002-2333-0366)

## References

- Viveen J, van den Bekerom MPJ, Doornberg JN, Hatton A, Page R, Koenraadt KLM, Wilson C, Bain GI, Jaarsma RL, Eygendaal D. Use and outcome of 1,220 primary total elbow arthroplasties from the Australian Orthopaedic Association National Joint Arthroplasty Replacement Registry 2008-2018. *Acta Orthop*. 2019 Dec;90(6):511-6. Epub 2019 Aug 27.
- Mansat P, Bonneville N, Rongières M, Mansat M, Bonneville P. Experience with the Coonrad-Morrey total elbow arthroplasty: 78 consecutive total elbow arthroplasties reviewed with an average 5 years of follow-up. *J Shoulder Elbow Surg*. 2013 Nov;22(11):1461-8.
- National Joint Replacement Registry. Hip, knee & shoulder arthroplasty: 2018 annual report. Adelaide: Australian Orthopaedic Association; 2018.
- Perretta D, van Leeuwen WF, Dyer G, Ring D, Chen N. Risk factors for reoperation after total elbow arthroplasty. *J Shoulder Elbow Surg*. 2017 May;26(5):824-9. Epub 2017 Jan 31.
- Geurts EJ, Viveen J, van Riet RP, Kodde IF, Eygendaal D. Outcomes after revision total elbow arthroplasty: a systematic review. *J Shoulder Elbow Surg*. 2019 Feb;28(2):381-6.
- Toulemonde J, Ancelin D, Azoulay V, Bonneville N, Rongières M, Mansat P. Complications and revisions after semi-constrained total elbow arthroplasty: a mono-centre analysis of one hundred cases. *Int Orthop*. 2016 Jan;40(1):73-80. Epub 2015 Oct 5.
- Voloshin I, Schippert DW, Kakar S, Kaye EK, Morrey BF. Complications of total elbow replacement: a systematic review. *J Shoulder Elbow Surg*. 2011 Jan;20(1):158-68.
- Morrey BF, Bryan RS. Revision total elbow arthroplasty. *J Bone Joint Surg Am*. 1987 Apr;69(4):523-32.
- Skyttä ET, Eskelinen A, Paavolainen P, Ikävalko M, Remes V. Total elbow arthroplasty in rheumatoid arthritis: a population-based study from the Finnish Arthroplasty Register. *Acta Orthop*. 2009 Aug;80(4):472-7.
- Pham TT, Bonneville N, Rongières M, Bonneville P, Mansat P. Mechanical failure of the Coonrad-Morrey linked total elbow arthroplasty: a case report. *Orthop Traumatol Surg Res*. 2014 Nov;100(7):831-4. Epub 2014 Sep 26.
- Viveen J, Prkic A, Koenraadt KL, Kodde IF, The B, Eygendaal D. Clinical and radiographic outcome of revision surgery of total elbow prosthesis: midterm results in 19 cases. *J Shoulder Elbow Surg*. 2017 Apr;26(4):716-22. Epub 2017 Jan 13.
- Lee BP, Adams RA, Morrey BF. Polyethylene wear after total elbow arthroplasty. *J Bone Joint Surg Am*. 2005 May;87(5):1080-7.
- Jenkins PJ, Watts AC, Norwood T, Duckworth AD, Rymaszewski LA, McEachan JE. Total elbow replacement: outcome of 1,146 arthroplasties from the Scottish Arthroplasty Project. *Acta Orthop*. 2013 Apr;84(2):119-23. Epub 2013 Mar 14.
- Ring D, Kocher M, Koris M, Thornhill TS. Revision of unstable capitellocondylar (unlinked) total elbow replacement. *J Bone Joint Surg Am*. 2005 May;87(5):1075-9.
- Sanchez-Sotelo J, O'Driscoll S, Morrey BF. Periprosthetic humeral fractures after total elbow arthroplasty: treatment with implant revision and strut allograft augmentation. *J Bone Joint Surg Am*. 2002 Sep;84(9):1642-50.
- Kamineni S, Morrey BF. Proximal ulnar reconstruction with strut allograft in revision total elbow arthroplasty. *J Bone Joint Surg Am*. 2004 Jun;86(6):1223-9.
- Foruria AM, Sanchez-Sotelo J, Oh LS, Adams RA, Morrey BF. The surgical treatment of periprosthetic elbow fractures around the ulnar stem following semi-constrained total elbow arthroplasty. *J Bone Joint Surg Am*. 2011 Aug 3;93(15):1399-407.
- Mansat P, Adams RA, Morrey BF. Allograft-prosthesis composite for revision of catastrophic failure of total elbow arthroplasty. *J Bone Joint Surg Am*. 2004 Apr;86(4):724-35.
- Allieu Y, Marck G, Chammas M, Desbonnet P, Raynaud JP. [Total elbow joint allograft for long term posttraumatic osteoarticular loss. Follow-up results at twelve years]. *Rev Chir Orthop Reparatrice Appar Mot*. 2004 Jun;90(4):319-28. French.

- 20.** Celli A, Arash A, Adams RA, Morrey BF. Triceps insufficiency following total elbow arthroplasty. *J Bone Joint Surg Am.* 2005 Sep;87(9):1957-64.
- 21.** Cusick MC, Bonnaig NS, Azar FM, Mauck BM, Smith RA, Throckmorton TW. Accuracy and reliability of the Mayo Elbow Performance Score. *J Hand Surg Am.* 2014 Jun;39(6):1146-50. Epub 2014 Mar 20.
- 22.** Hudak PL, Amadio PC, Bombardier C; The Upper Extremity Collaborative Group (UECG). Development of an upper extremity outcome measure: the DASH (Disabilities of the Arm, Shoulder and Hand) [corrected] [Erratum in: *Am J Ind Med* 1996 Sep; 30(3):372]. *Am J Ind Med.* 1996 Jun;29(6):602-8.
- 23.** Throckmorton TW, Zarkadas PC, Sanchez-Sotelo J, Morrey BF. Radial nerve palsy after humeral revision in total elbow arthroplasty. *J Shoulder Elbow Surg.* 2011 Mar;20(2):199-205. Epub 2010 Nov 24.
- 24.** Jeon IH, Morrey BF, Anakwenze OA, Tran NV. Incidence and implications of early postoperative wound complications after total elbow arthroplasty. *J Shoulder Elbow Surg.* 2011 Sep;20(6):857-65. Epub 2011 Jun 8.
- 25.** Medical Research Council. Aids to examination of the peripheral nervous system. Memorandum no. 45. London: Her Majesty's Stationary Office; 1976.
- 26.** King GJ, Adams RA, Morrey BF. Total elbow arthroplasty: revision with use of a non-custom semiconstrained prosthesis. *J Bone Joint Surg Am.* 1997 Mar;79(3):394-400.
- 27.** Wee AT, Morrey BF, Sanchez-Sotelo J. The fate of elbows with unexpected positive intraoperative cultures during revision elbow arthroplasty. *J Bone Joint Surg Am.* 2013 Jan 16;95(2):109-16.
- 28.** Morrey ME, Sanchez-Sotelo J, Abdel MP, Morrey BF. Allograft-prosthetic composite reconstruction for massive bone loss including catastrophic failure in total elbow arthroplasty. *J Bone Joint Surg Am.* 2013 Jun 19;95(12):1117-24.
- 29.** Malone AA, Sanchez JS, Adams R, Morrey B. Revision of total elbow replacement by exchange cementing. *J Bone Joint Surg Br.* 2012 Jan;94(1):80-5.
- 30.** Bryan RS, Morrey BF. Extensive posterior exposure of the elbow. A triceps-sparing approach. *Clin Orthop Relat Res.* 1982 Jun;166:188-92.
- 31.** de Vos MJ, Wagener ML, Hannink G, van der Pluijm M, Verdonchot N, Eygendaal D. Short-term clinical results of revision elbow arthroplasty using the Latitude total elbow arthroplasty. *Bone Joint J.* 2016 Aug;98-B(8):1086-92.
- 32.** Sneftrup SB, Jensen SL, Johannsen HV, Søjbjerg JO. Revision of failed total elbow arthroplasty with use of a linked implant. *J Bone Joint Surg Br.* 2006 Jan; 88(1):78-83.
- 33.** Rhee YG, Cho NS, Park JG, Song JH. Resection arthroplasty for periprosthetic infection after total elbow arthroplasty. *J Shoulder Elbow Surg.* 2016 Jan;25(1):105-11. Epub 2015 Oct 23.
- 34.** Zarkadas PC, Cass B, Throckmorton T, Adams R, Sanchez-Sotelo J, Morrey BF. Long-term outcome of resection arthroplasty for the failed total elbow arthroplasty. *J Bone Joint Surg Am.* 2010 Nov 3;92(15):2576-82.
- 35.** Shi LL, Zurakowski D, Jones DG, Koris MJ, Thornhill TS. Semiconstrained primary and revision total elbow arthroplasty with use of the Coonrad-Morrey prosthesis. *J Bone Joint Surg Am.* 2007 Jul;89(7):1467-75.
- 36.** Waitzenegger T, Mansat P, Guillon P, Lenoir H, Coulet B, Lazerges C, Chammas M. Radial nerve palsy in surgical revision of total elbow arthroplasties: a study of 4 cases and anatomical study, possible aetiologies and prevention. *Orthop Traumatol Surg Res.* 2015 Dec;101(8):903-7. Epub 2015 Oct 20.
- 37.** Loebenberg MI, Adams R, O'Driscoll SW, Morrey BF. Impaction grafting in revision total elbow arthroplasty. *J Bone Joint Surg Am.* 2005 Jan;87(1):99-106.
- 38.** Galley IJ, Bain GI, Stanley JC, Lim YW. Arthrodesis of the elbow with two locking compression plates. *Tech Elbow Shoulder Surg.* 2007 Sep;8(3):141-5.
- 39.** Otto RJ, Mulieri PJ, Cottrell BJ, Mighell MA. Arthrodesis for failed total elbow arthroplasty with deep infection. *J Shoulder Elbow Surg.* 2014 Mar; 23(3):302-7.