



A commentary by Jeffrey D. Thomson, MD, is linked to the online version of this article at jbjs.org.

The Natural History of Benign Bone Tumors of the Extremities in Asymptomatic Children

A Longitudinal Radiographic Study

Christopher D. Collier, MD, Grant B. Nelson, MD, Keegan T. Conry, MD, Christos Kosmas, MD, Patrick J. Getty, MD,* and Raymond W. Liu, MD*

Investigation performed at University Hospitals Rainbow Babies & Children's Hospital, Case Western Reserve University, Cleveland, Ohio

Background: Benign bone tumors are common incidental findings in the pediatric population during radiographic evaluation. Counseling these patients requires reassurance and raises questions about the natural history of these tumors over time. The purpose of this study was to estimate the prevalence and observe the behavior of benign childhood bone tumors in an asymptomatic population.

Methods: A historical, longitudinal radiographic collection of healthy children was reviewed, which included comprehensive left-sided radiographs of the extremities at yearly intervals. In this study, 262 subjects with 25,555 radiographs were screened for benign bone tumors at a median age of 8 years (range, 0 to 18 years). All potential tumors were reviewed by a multidisciplinary panel, which confirmed the radiographic diagnosis of each lesion, the age at which the lesion first appeared, and the age at which it had resolved. Prevalence rates were calculated using the number of distinct subjects available for each radiographic location and age.

Results: Thirty-five tumors were identified in 33 subjects, including 19 nonossifying fibromas, 8 enostoses, 6 osteochondromas, and 2 enchondromas. The prevalence rate for all tumors combined increased with age and was 18.9% overall. The overall prevalence rates for specific tumor types were 7.5% for nonossifying fibromas, 5.2% for enostoses, 4.5% for osteochondromas, and 1.8% for enchondromas. Nonossifying fibromas demonstrated a bimodal distribution of prevalence, with a peak at 5 years (10.8%) and another after skeletal maturity (13.3%). The median age at the first appearance for all tumors combined was 9 years (range, 2 to 15 years), but varied by tumor type. Nonossifying fibromas often resolved (7 [37%] of 19), with further resolution possible beyond the last available radiograph. Enostoses, osteochondromas, and enchondromas persisted until the last available radiographs in all subjects.

Conclusions: The prevalence of benign childhood bone tumors of the extremities was 18.9% in a historical asymptomatic population. Longitudinal radiographs allowed observation of the timing of the first appearance and the potential for resolution for each tumor type. These findings provide unique evidence to answer many commonly encountered questions when counseling patients and their families on benign bone tumors.

Level of Evidence: Prognostic Level IV. See Instructions for Authors for a complete description of levels of evidence.

Benign bone tumors were classified by Enneking into 3 stages based on biologic behavior: latent, active, or aggressive¹. Active and aggressive tumors of childhood include unicameral bone cysts, aneurysmal bone cysts, and giant cell

tumors of bone and are typically discovered because of discomfort or pathologic fracture that prompts clinical evaluation²⁻⁴. Latent tumors of childhood include nonossifying fibromas or fibrous cortical defects, enostoses or bone islands, osteochondromas, and

*Patrick J. Getty, MD, and Raymond W. Liu, MD, contributed equally to this article.

Disclosure: The authors indicated that no external funding was received for any aspect of this work. The **Disclosure of Potential Conflicts of Interest** forms are provided with the online version of the article (<http://links.lww.com/JBJS/G309>).

enchondromas, all of which rarely present with symptoms but instead present as incidental findings during the radiographic evaluation of trauma, unrelated pain, or deformity²⁻⁴. In the case of an active or aggressive tumor, the incidence and prevalence can be accurately estimated by comparing the number of presenting patients with the size of the population, as previously reported^{5,6}. However, establishing similar epidemiologic proportions for latent tumors is challenging because the majority are undiagnosed.

The initial management of benign childhood bone tumors, when recognized, often includes referral to a pediatric orthopaedic surgeon or orthopaedic oncologist. Benign or non-neoplastic bone lesions may comprise 57% of new consultations in an orthopaedic oncology practice⁷. Although not studied directly, several authors have highlighted the anxiety experienced by patients and their families as they await the confirmation of a benign diagnosis^{3,4,8}. Counseling these patients requires reassurance and raises questions about the natural history of their tumor over time. The existing literature has been largely limited to estimates of prevalence based on incidental lesions, which is less desirable⁹⁻¹⁵. The purpose of this study was therefore to determine the prevalence and observe the behavior of benign childhood bone tumors in a longitudinal radiographic collection of asymptomatic children.

Materials and Methods

Study Population

The Brush Inquiry, which includes a longitudinal radiographic collection of healthy children, was conducted in Cleveland, Ohio, from 1926 to 1942 to document normal growth and development¹⁶. It included >4,400 subjects who were selected for enrollment only if “free of gross physical and mental defects” and in some cases through “health contests” held at local schools to identify “normal” children. Data collection included annual left-sided radiographs of the chest and shoulder, elbow, pelvis and hip, knee, and ankle and foot. A simultaneous study, the Bolton Study¹⁷, was conducted on the same subjects to document normal dentofacial growth and included left-sided wrist and hand radiographs, which later provided the images for the widely recognized Greulich and Pyle Atlas for bone age¹⁸. The Bolton-Brush population reflected the demographic characteristics of early twentieth-century Cleveland, Ohio, with respect to sex (49.2% male and 50.8% female), race (92.2% White, 7.7% Black, and 0.1% other), and socioeconomic status.

Anteroposterior and lateral radiographs of the left elbow, wrist and hand, knee, and ankle and foot, and anteroposterior radiographs of the chest and shoulder and the pelvis and hip were retrieved and were digitized for a sample of 262 subjects with at least 5 consecutive annual visits. These subjects were randomly chosen from the 4,400 available subjects in 2 separate batches. In the first batch, 150 subjects with multiple visits spanning the pubertal age range were selected. In the second batch, 112 subjects with at least 10 visits were chosen, with a preference for subjects with younger-age study visits to include ages not well covered in the first batch. Images were optimized using the Levels function in Adobe Photoshop. Of the subjects, 54.2% were male and 45.8% were female. Racial differences were not available for this sample. Initially, 25,801 radiographs were reviewed, including anteropos-

terior and lateral views. There were 246 radiographs excluded because of motion artifact, underpenetration or overpenetration, decomposition of the film, or an incomplete field of view. For the chest and shoulder, the radiograph included the clavicle, scapula, and the articular surface of the humerus to the metaphyseal-diaphyseal junction. For the pelvis and hip, the radiograph included the hemipelvis and the articular surface of the femur to the metaphyseal-diaphyseal junction, including the lesser trochanter. All other radiographs included all bones in the region of interest including the articular surface to the metaphyseal-diaphyseal junction of the adjacent long bones on at least 1 view. The axial skeleton was not studied. The subject age at the time of each radiograph was available and was rounded to the nearest whole number. Siblings of study participants were recruited to allow the inclusion of infants. Radiographs taken before the patient age of 6 months were rounded to 0. The median age at the time of radiographic evaluations was 8 years (range, 0 to 18 years). If >1 visit was available for the same subject at a given age, the anteroposterior and lateral radiographs were pooled and were considered a single distinct visit. The median number of visits per subject was 11 (range, 5 to 29), resulting in a median of 100 radiographs (range, 3 to 168 radiographs). In total, 25,555 radiographs of 262 subjects, representing 12,241 distinct subject visits for all locations combined, were included for analysis (Fig. 1).

Screening and Diagnosis of Tumors

An initial screening of 80 subjects was performed by a multidisciplinary panel consisting of a fellowship-trained musculoskeletal radiologist (C.K.), a pediatric orthopaedic surgeon (R.W.L.), an orthopaedic oncologist (P.J.G.), and a senior-level orthopaedic resident (C.D.C.). All radiographs with lesions were noted. At a later date, the radiographs for these 80 subjects were rescreened by a single author (C.D.C.). The interrater reliability was determined, using the phi coefficient for 2 binary variables, and demonstrated near-perfect agreement for the identification of lesions between the multidisciplinary panel and single-author groups (0.94)¹⁹. The difference was that 2 tumors were missed by the multidisciplinary panel but were identified by the single-author review. The remaining 182 subjects were therefore screened by a single author (C.D.C.). All radiographs were screened by subject and anatomic location in chronologic order, such that if a lesion was missed on 1 radiograph, it could potentially be identified on subsequent

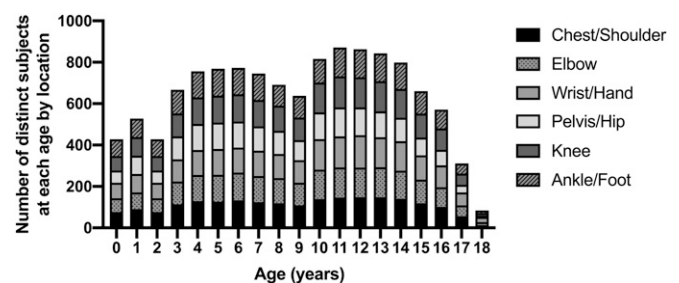


Fig. 1
Number of distinct subjects screened at each age by location.

views or visits. Additionally, radiographs were screened over several months, with frequent breaks, using a dark room and a high-resolution monitor to reduce the risk of missed lesions as a result of eyestrain and fatigue²⁰. After completion of all screening, identified lesions were evaluated by the multidisciplinary panel. By consensus, the panel confirmed the radiographic diagnosis of each lesion, the age at which the lesion first appeared, and the age at which it was last seen. No tumor types were excluded.

Calculation of Prevalence Rates

Prevalence, the proportion of a population affected by a condition at a given time, was estimated for the study population for all tumors and each tumor type observed. Incidence, the proportion of a population diagnosed with a new condition within a specified time period, could not be estimated because the age of first appearance was not known for all tumors²¹. Radiographs were not available for each subject at every location and age because of missed visits, incomplete radiographic surveys, or exclusion due to poor quality. To account for missing radiographs, location and age-specific prevalence rates were estimated by dividing the number of tumors for each

radiographic location and age by the number of distinct subjects available (see Appendix Table S1). The prevalence rates for each radiographic location were then combined to provide the all-location rate for a given age. The overall prevalence rates assumed an equally distributed population by age and were calculated by averaging the rates for ages 0 to 18 years. Finally, all reported prevalence rates were doubled to account for the contralateral extremities, as only left-sided radiographs were reviewed.

Results

Prevalence of Benign Childhood Bone Tumors

Thirty-five tumors were identified in 33 subjects, including 19 nonossifying fibromas, 8 enostoses, 6 osteochondromas, and 2 enchondromas (Fig. 2). No other bone tumors, including cystic lesions, were identified. The prevalence rate for all tumors combined increased with age and was 18.9% overall (Fig. 3; see also Appendix Table S1). The overall prevalence rates for specific tumor types were 7.5% for nonossifying fibromas, 5.2% for enostoses, 4.5% for osteochondromas, and 1.8% for enchondromas. Nonossifying fibromas demonstrated a bimodal distribution of prevalence, with a peak at 5 years

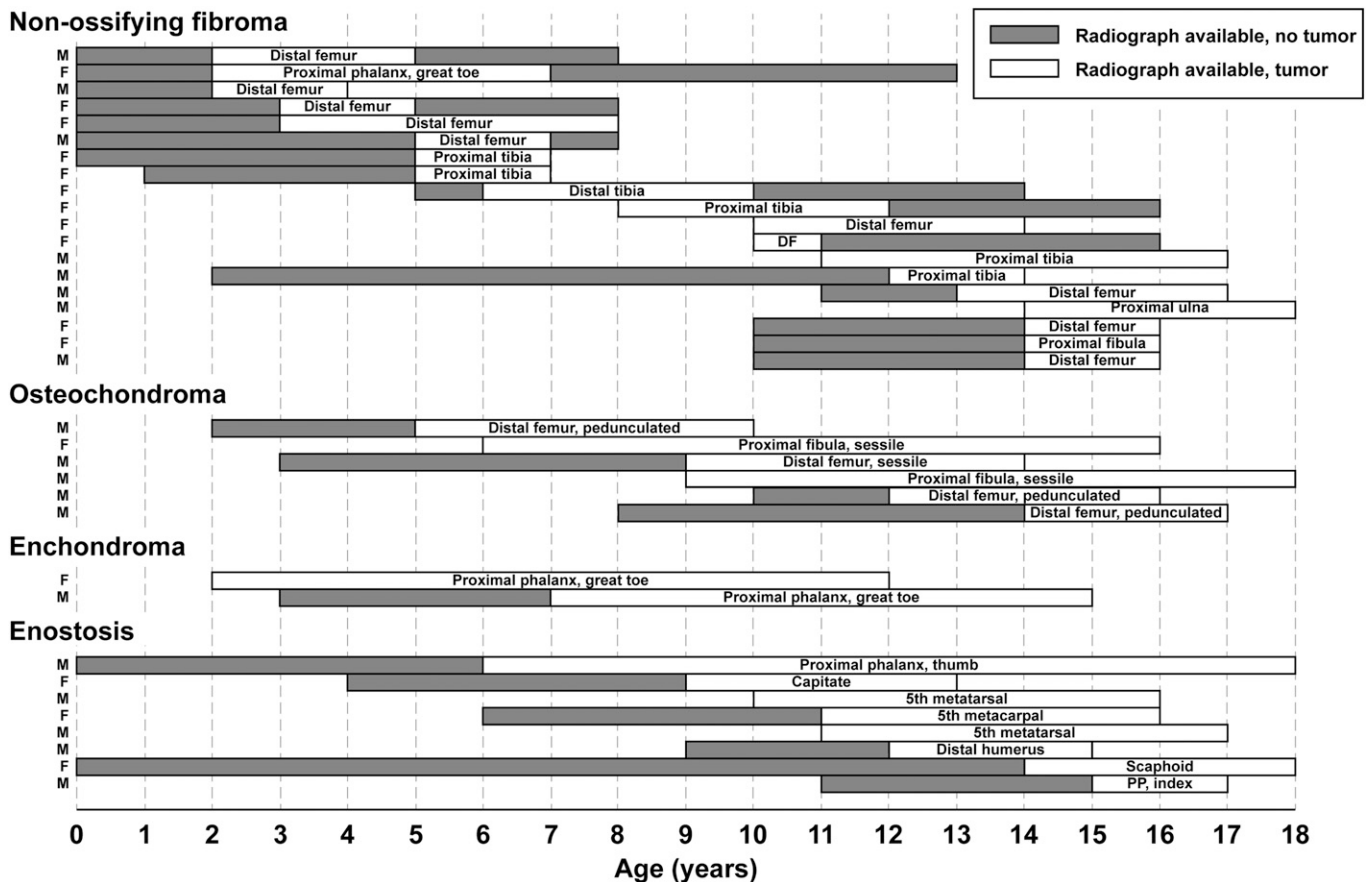


Fig. 2 Natural history of the benign childhood tumors identified in this study over time. Bars represent individual subjects. The position and length of each bar along the x axis describe the availability of radiographs at each age. The shading of each bar describes the presence or absence of a tumor. Sex is indicated on the left side. M = male, F = female, DF = distal part of the femur, and PP = proximal phalanx.

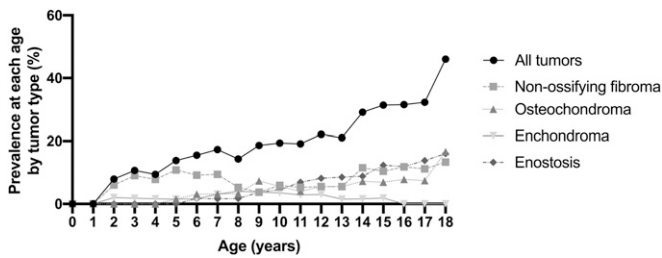


Fig. 3
Prevalence of benign childhood tumors at each age by tumor type. Rates were doubled to account for the contralateral extremities as only left-sided radiographs were reviewed.

(10.8%) and another after skeletal maturity (13.3%). The overall prevalence rates for all tumors combined for specific radiographic locations were 0.0% for the chest and shoulder, 1.5% for the elbow, 3.6% for the hand and wrist, 0.0% for the pelvis and hip, 9.8% for the knee, and 4.1% for the ankle and foot (see Appendix Table S1).

Behavior of Benign Childhood Bone Tumors Over Time

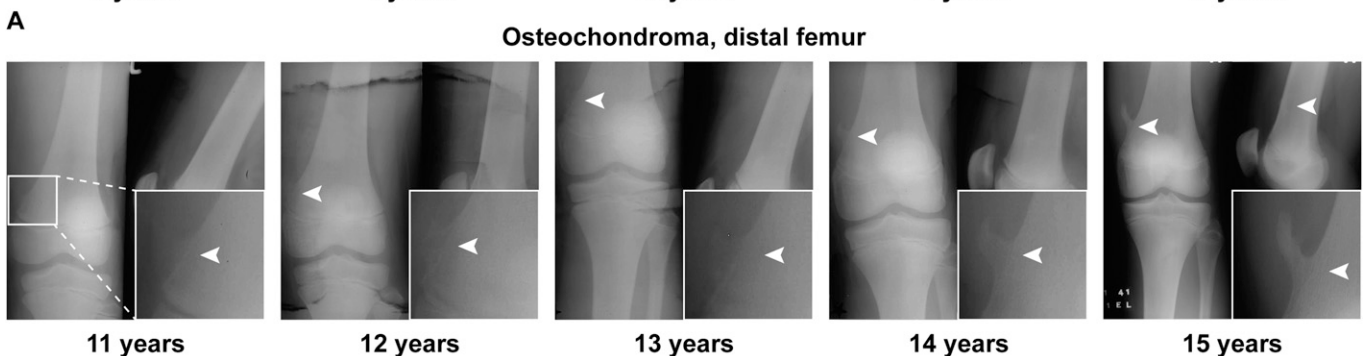
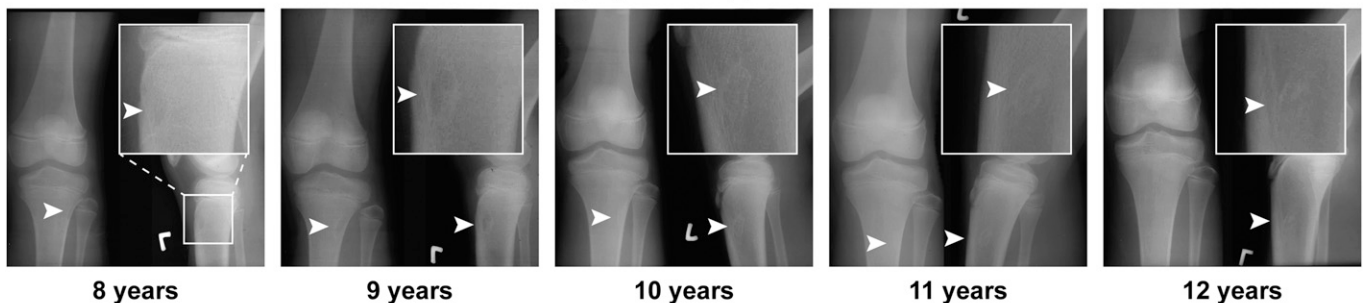
The median age of first appearance for subjects with previously negative radiographs was 9 years (range, 2 to 15 years) for all tumors combined, 5 years (range, 2 to 14 years) for non-ossifying fibromas, 10.5 years (range, 6 to 15 years) for enostoses, 10.5 years (range, 5 to 14 years) for osteochondromas,

and 7 years (no range available) for enchondromas. Non-ossifying fibromas were typically identified about the knee (16 [84%] of 19) and often resolved (7 [37%] of 19), with further resolution possible beyond the last available radiograph (Fig. 4-A). Osteochondromas were always identified about the knee (6 [100%] of 6) and persisted until the last available radiograph (Fig. 4-B). Enchondromas (2 [100%] of 2) and enostoses (7 [88%] of 8) were commonly identified in the small bones of the hand or foot and also persisted until the last available radiograph in all subjects.

Discussion

The prevalence of benign childhood bone tumors of the extremities was 18.9% in a historical asymptomatic population. Nonossifying fibromas were the most commonly observed tumor type at an overall prevalence of 7.5%, followed by enostoses (5.2%), osteochondromas (4.5%), and enchondromas (1.8%). The prevalence of tumors and the most common tumor type were location-specific, and the overall prevalence increased with age. Nonossifying fibromas were the only tumor type that resolved in this population based on the available radiographs. To our knowledge, this is the only longitudinal radiographic study to estimate the prevalence of benign childhood bone tumors in an asymptomatic population. Considering the now-recognized carcinogenic effect of ionizing radiation, it is no longer ethical

Non-ossifying fibroma, proximal tibia



B
Fig. 4

Figs. 4-A and 4-B Examples of benign childhood tumors over time are shown and are highlighted by a white arrowhead and a magnified inset. **Fig. 4-A** A nonossifying fibroma of the proximal part of the tibia appears at the patient age of 8 years and becomes sclerotic and less visible by the patient age of 12 years. **Fig. 4-B** A pedunculated osteochondroma of the distal part of the femur appears at the patient age of 11 years and increases in size as the subject approaches skeletal maturity.

or practical to obtain annual whole-skeleton radiographs of healthy children²². This study, despite inherent limitations, may therefore provide the best available evidence with regard to the natural history of asymptomatic benign childhood bone tumors.

Although the existing literature is largely limited to incidental lesions, there are several studies that provide an important context for our findings. Seo et al.⁹ reported on 1,562 knee radiographs in children with knee pain or malalignment and found the prevalence of metaphyseal lucent areas, including nonossifying fibromas, to be 8.4% and that for osteochondromas to be 2.8%, which is comparable with the rates reported here for nonossifying fibromas (5.3%) and osteochondromas (4.5%) of the knee. For osteochondromas, we previously described a prevalence rate of 0.4% in a large osteologic collection; however, the study consisted primarily of adult specimens and only considered the pedunculated subtype, limiting its applicability to the current subjects²³. Incidental enchondromas in adults are present on 2.1% of shoulder¹⁴ and 2.8% to 2.9% of knee^{10,13} magnetic resonance imaging scans and 0.07% of hand radiographs¹¹. To our knowledge, prior estimates in children are not available, but the observed overall rate of 1.8% for enchondromas in this study is lower than that predicted in the adult population, albeit using different techniques. Enchondromas could therefore develop with age or become more radiographically apparent over time because of increased size or calcification, as has been observed²⁴. Interestingly, 80% of foot enchondromas occur in the proximal phalanx²⁵, consistent with our findings. Enostoses, or bone islands, were reported in 3.8% of hand radiographs made during childhood¹⁵, which is similar to the 3.6% prevalence observed for the hand in this study. Taken together, prior studies on incidental lesions are generally in agreement with our findings in an asymptomatic population.


Unique to our study was the ability to observe tumors longitudinally, including the age of first appearance. Nonossifying fibromas occurred earlier (median age overall, 5 years) but had a bimodal distribution for prevalence with a second peak around skeletal maturity. The observed periods of higher nonossifying fibroma prevalence followed described phases of rapid childhood growth: the infantile growth spurt lasting until approximately 3 years of age, and the adolescent growth spurt just before skeletal maturity²⁶. Although not the focus of this study, this finding suggests that the pathogenesis of nonossifying fibromas may be related to changing skeletal growth rates. Osteochondromas and enostoses occurred later, at a median age of 10.5 years. Tan et al.²⁷ described 6 incidental or pathologic nonossifying fibromas, with previously normal radiographs, presenting at a mean age of 11.4 years; however, the mean interval between normal and abnormal radiographs was 4.3 years, without intervening studies, which likely overestimated the age of first appearance. In another study¹⁵, Limb and Agrawal reported on 610 hand radiographs from children who were between 5 and 13 years of age and found 24 bone islands, the earliest at 10 years and 2 months, which is comparable with our findings. In the present study, nonossifying fibromas were the only tumor type that resolved with the radi-

ographs available, although reports exist describing spontaneous resolution for nonossifying fibromas^{28,29}, osteochondromas^{28,30-34}, enchondromas³⁵, and enostoses^{28,36}. Many of these cases occurred during late adolescence or adulthood, which could have been missed in our study. The lack of resolution for most tumor types in our sample led to the accumulation of tumors with age and higher overall prevalence, which was >30% for the ages of 15 to 18 years.

There were important limitations to our study. First, the use of a historical collection, representative of the Greater Cleveland area approximately 80 years ago (the subjects of which were 92.2% White), may limit the generalizability of this study to modern populations and other races. However, there was consistency between estimates from this study and others based on incidental findings. Second, the exclusion of children with “physical defects” may have led to an underestimation of tumor prevalence if asymptomatic children with benign bone tumors were excluded. Third, despite reviewing 25,555 radiographs from 262 subjects, this collection did not include radiographs for all ages and locations for each subject, resulting in a variance in the number of radiographs available for each individual subject. Prevalence was therefore estimated on the basis of the number of distinct subjects available for each radiographic location and age, which may have skewed the results. However, given the nature of the data set with the appearance and resolution of many lesions on serial images, we did not identify a superior method for tabulating the data, and the effect should be minimized by the relatively large sample size. Fourth, we assumed a symmetric distribution of tumors and therefore doubled all reported prevalence rates to account for unimaged contralateral extremities. Although we are not aware of a relationship between laterality and the presence of benign bone tumors, this may have resulted in an underestimation or overestimation of prevalence. Fifth, even for the radiographs that met our inclusion criteria, there was some limitation to the contrast and detail as a result of their antiquity and digitization. Although we mitigated this by optimizing the images, this could have resulted in the underreporting of smaller, indistinct tumors. Sixth, because the radiographs were centered around major joints, the diaphysis was not uniformly included for long bones. This was particularly true in larger, older subjects, as the x-ray plate size was consistent throughout the different ages, and, thus, the prevalence of diaphyseal tumors may be underreported in older ages. Seventh, inherent to any screening study is the possibility of missed events. Considerable efforts were therefore made to mitigate this risk, including screening by multiple authors, over time, and under optimized conditions, but the risk of missed tumors is not negligible. Eighth, there were fewer radiographs available at older ages, which could have resulted in an underestimation or overestimation of prevalence due to chance. Finally, this study was likely underpowered to recognize relatively rare events, including less common tumors and locations. Despite these limitations, this study was strengthened by using a large, longitudinal, and truly observational cohort of subjects that could not be repeated in modern times because of the now-recognized risks of radiation exposure in children.

In summary, this study described the natural history of benign childhood bone tumors of the extremities, reporting an overall prevalence rate of 18.9% in a historical asymptomatic population. Longitudinal radiographs allowed observations with regard to the timing of the first appearance and the potential for resolution for each tumor type. These findings provide useful evidence to answer many commonly encountered questions when counseling patients and their family members on benign bone tumors.

Appendix

 Supporting material provided by the authors is posted with the online version of this article as a data supplement at [jbjs.org \(http://links.lww.com/JBJS/G310\)](http://links.lww.com/JBJS/G310). ■

Christopher D. Collier, MD¹
Grant B. Nelson, MD²

Keegan T. Conry, MD²
Christos Kosmas, MD³
Patrick J. Getty, MD²
Raymond W. Liu, MD²

¹Department of Orthopaedic Surgery, Indiana University School of Medicine, Indianapolis, Indiana

²Department of Orthopaedics, University Hospitals Rainbow Babies & Children's Hospital, Case Western Reserve University, Cleveland, Ohio

³Department of Radiology, University Hospitals Cleveland Medical Center, Case Western Reserve University, Cleveland, Ohio

Email address for C.D. Collier: ccollier5@iuhealth.org

ORCID iD for C.D. Collier: [0000-0003-2639-4290](https://orcid.org/0000-0003-2639-4290)

ORCID iD for G.B. Nelson: [0000-0002-4635-5507](https://orcid.org/0000-0002-4635-5507)

ORCID iD for K.T. Conry: [0000-0002-9995-0297](https://orcid.org/0000-0002-9995-0297)

ORCID iD for C. Kosmas: [0000-0003-1849-0274](https://orcid.org/0000-0003-1849-0274)

ORCID iD for P.J. Getty: [0000-0002-2716-3032](https://orcid.org/0000-0002-2716-3032)

ORCID iD for R.W. Liu: [0000-0003-3041-8312](https://orcid.org/0000-0003-3041-8312)

References

- Enneking WF. A system of staging musculoskeletal neoplasms. *Clin Orthop Relat Res.* 1986 Mar;204:9-24.
- Gitelis S, Wilkins R, Conrad E III. Benign bone tumors. *J Bone Joint Surg Am.* 1995;77(11):1756-82.
- Abouafia AJ, Kennon RE, Jelinek JS. Benign bone tumors of childhood. *J Am Acad Orthop Surg.* 1999 Nov-Dec;7(6):377-88.
- Biermann JS. Common benign lesions of bone in children and adolescents. *J Pediatr Orthop.* 2002 Mar-Apr;22(2):268-73.
- Zehetgruber H, Bittner B, Gruber D, Krepler P, Trieb K, Kotz R, Dominkus M. Prevalence of aneurysmal and solitary bone cysts in young patients. *Clin Orthop Relat Res.* 2005 Oct;439:136-43.
- Liede A, Bach BA, Stryker S, Hernandez RK, Sobocki P, Bennett B, Wong SS. Regional variation and challenges in estimating the incidence of giant cell tumor of bone. *J Bone Joint Surg Am.* 2014 Dec 3;96(23):1999-2007.
- Abouafia AJ, Levin AM, Blum J. Prereferral evaluation of patients with suspected bone and soft tissue tumors. *Clin Orthop Relat Res.* 2002 Apr;397:83-8.
- Henderson ER; Evidence Based Medicine Committee of the Musculoskeletal Tumor Society. Information statement: guidelines for specialist referral in newly identified bone lesions. 2018 Jan. Accessed 2020 May 12. <http://msts.org/view/download.php/education/pdfs/guidelines-for-specialist-referral-in-newly-identified-bone-lesions>
- Seo SG, Sung KH, Chung CY, Lee KM, Lee SY, Choi Y, Kim TG, Baek JK, Kwon SS, Kwon DG, Choi IH, Cho TJ, Yoo WJ, Park MS. Incidental findings on knee radiographs in children and adolescents. *Clin Orthop Surg.* 2014 Sep;6(3):305-11. Epub 2014 Aug 5.
- Stomp W, Reijniere M, Kloppenburg M, de Mutsert R, Bovée JV, den Heijer M, Bloem JL; NEO Study Group. Prevalence of cartilaginous tumours as an incidental finding on MRI of the knee. *Eur Radiol.* 2015 Dec;25(12):3480-7. Epub 2015 May 21.
- Davies AM, Shah A, Shah R, Patel A, James SL, Botchu R. Are the tubular bones of the hand really the commonest site for an enchondroma? *Clin Radiol.* 2020 Jul;75(7):533-7. Epub 2020 Mar 14.
- Velasco BT, Ye MY, Chien B, Kwon JY, Miller CP. Prevalence of incidental benign and malignant lesions on radiographs ordered by orthopaedic surgeons. *J Am Acad Orthop Surg.* 2020 Apr 15;28(8):e356-62.
- Walden MJ, Murphey MD, Vidal JA. Incidental enchondromas of the knee. *AJR Am J Roentgenol.* 2008 Jun;190(6):1611-5.
- Hong ED, Carrino JA, Weber KL, Fayad LM. Prevalence of shoulder enchondromas on routine MR imaging. *Clin Imaging.* 2011 Sep-Oct;35(5):378-84.
- Limb D, Agrawal Y. The distribution of bone islands and juxta-articular bone cysts in the growing hand. *J Hand Surg Br.* 2006 Aug;31(4):441-4. Epub 2006 Apr 27.
- Nelson S, Hans MG, Broadbent BH Jr, Dean D. The Brush Inquiry: an opportunity to investigate health outcomes in a well-characterized cohort. *Am J Hum Biol.* 2000 Jan;12(1):1-9.
- Hans MG, Broadbent BH Jr, Nelson SS. The Broadbent-Bolton growth study—past, present, and future. *Am J Orthod Dentofacial Orthop.* 1994 Jun;105(6):598-603.
- Greulich WW, Pyle SI. Radiographic atlas of skeletal development of the hand and wrist. 2nd ed. Stanford, CA: Stanford University Press; 1959.
- Hartmann DP. Considerations in the choice of interobserver reliability estimates. *J Appl Behav Anal.* 1977 Spring;10(1):103-16.
- Krupinski EA, Berbaum KS, Caldwell RT, Scharz KM, Kim J. Long radiology workdays reduce detection and accommodation accuracy. *J Am Coll Radiol.* 2010 Sep;7(9):698-704.
- Porta M. A dictionary of epidemiology. 6th ed. Online. Oxford University Press; 2016. Accessed 2021 Jan 4. <https://www.oxfordreference.com/view/10.1093/acref/9780199976720.001.0001/acref-9780199976720>
- Kleinerman RA. Cancer risks following diagnostic and therapeutic radiation exposure in children. *Pediatr Radiol.* 2006 Sep;36(Suppl 2):121-5.
- Gaumer GR, Weinberg DS, Collier CD, Getty PJ, Liu RW. An osteological study on the prevalence of osteochondromas. *Iowa Orthop J.* 2017;37:147-50.
- Murphey MD, Flemming DJ, Boyea SR, Bojeskul JA, Sweet DE, Temple HT. Enchondroma versus chondrosarcoma in the appendicular skeleton: differentiating features. *Radiographics.* 1998 Sep-Oct;18(5):1213-37; quiz 1244-5.
- Chun KA, Stephanie S, Choi JY, Nam JH, Suh JS. Enchondroma of the foot. *J Foot Ankle Surg.* 2015 Sep-Oct;54(5):836-9. Epub 2015 May 27.
- Sanders JO, Qiu X, Lu X, Duren DL, Liu RW, Dang D, Menendez ME, Hans SD, Weber DR, Cooperman DR. The uniform pattern of growth and skeletal maturation during the human adolescent growth spurt. *Sci Rep.* 2017 Dec 1;7(1):16705.
- Tan E, T Mehlman C, Baker M. Benign osteolytic lesions in children with previously normal radiographs. *J Pediatr Orthop.* 2017 Jun;37(4):e282-5.
- Yanagawa T, Watanabe H, Shinozaki T, Ahmed AR, Shirakura K, Takagishi K. The natural history of disappearing bone tumours and tumour-like conditions. *Clin Radiol.* 2001 Nov;56(11):877-86.
- Herget GW, Mauer D, Krauß T, El Tayeh A, Uhl M, Südkamp NP, Hauschild O. Non-ossifying fibroma: natural history with an emphasis on a stage-related growth, fracture risk and the need for follow-up. *BMC Musculoskelet Disord.* 2016 Apr 5;17:147.
- Paling MR. The "disappearing" osteochondroma. *Skeletal Radiol.* 1983;10(1):40-2.
- Copeland RL, Meehan PL, Morrissy RT. Spontaneous regression of osteochondromas. Two case reports. *J Bone Joint Surg Am.* 1985 Jul;67(6):971-3.
- Castriota-Scanderberg A, Bonetti MG, Cammisia M, Dallapiccola B. Spontaneous regression of exostoses: two case reports. *Pediatr Radiol.* 1995;25(7):544-8.
- Arkader A, Dormans JP, Gaugler R, Davidson RS. Spontaneous regression of solitary osteochondroma: reconsidering our approach. *Clin Orthop Relat Res.* 2007 Jul;460:253-7.
- Hill CE, Boyce L, van der Ploeg ID. Spontaneous resolution of a solitary osteochondroma of the distal femur: a case report and review of the literature. *J Pediatr Orthop B.* 2014 Jan;23(1):73-5.
- Sensarma A, Madewell JE, Meis JM, Kumar R, Lin PP, Amini B. Regression of an enchondroma: a case report and proposed etiology. *Skeletal Radiol.* 2015 May;44(5):739-42. Epub 2014 Oct 21.
- Onitsuka H. Roentgenologic aspects of bone islands. *Radiology.* 1977 Jun;123(3):607-12.