



Original Contribution

Preprocedural prediction of epidural depth using ultrasonography and magnetic resonance imaging in cervical interlaminar epidural injections: A fluoroscopic validation study

Damla Yürük, MD^{a,*}, Gözde Erol, MD^b, Pelin Kavak, MD^c, Ömer Taylan Akkaya, MD^a

^a Department of Algology, Ankara Etlük City Hospital, Ankara, Türkiye

^b Department of Algology, Dr. Nafiz Körez State Hospital, Sincan, Ankara, Türkiye

^c Department of Radiology, Ufuk University Dr. Rıdvan Ege Hospital, Ankara, Türkiye

HIGHLIGHTS

- Epidural depth can be predicted in cervical interlaminar epidural injections.
- MRI is more accurate, but ultrasonography provides a practical bedside alternative.
- Greater epidural depth is associated with increased fluoroscopy use.
- Preprocedural imaging may reduce fluoroscopy use and radiation exposure.

ARTICLE INFO

Keywords:

Epidural steroid injections
Epidural space
Cervical spine
Ultrasonography
Magnetic resonance imaging

ABSTRACT

Background: Cervical interlaminar epidural injection (CIEI) is a commonly performed neuraxial intervention in anesthetic and pain management practice for the treatment of neck and radicular pain. Accurate identification of the epidural space is essential to avoid serious complications. Although fluoroscopy is considered the reference standard for confirming epidural placement, epidural access in anesthetic practice is typically achieved using the loss-of-resistance technique. Preprocedural estimation of epidural depth using ultrasonography (US) and magnetic resonance imaging (MRI) may enhance procedural control and optimize fluoroscopic use.

Methods: This prospective observational study, included 90 patients undergoing CIEI at the C7–T1 level. Epidural depth was estimated preprocedurally using ultrasonography (US-PED) and cervical magnetic resonance imaging (MRI-PED) and compared with contrast-confirmed epidural depth under fluoroscopic guidance (CCED). Accuracy was defined as measurements within ± 0.3 cm of the CCED. Associations and agreement between measurement methods were assessed using Spearman correlation and Bland–Altman analyses. In addition, relationships between CCED, patient demographic characteristics, and the number of lateral fluoroscopic images (NLFI) were analyzed.

Results: The CCED was measured at 6.01 ± 0.84 cm. Mean ultrasonography-predicted (US-PED) and MRI-predicted epidural depths (MRI-PED) were 5.92 ± 0.77 cm and 5.93 ± 0.97 cm, respectively. Within an error margin of ± 0.3 cm, 60.0% of US-PED and 67.8% of MRI-PED measurements accurately predicted the CCED. The two methods demonstrated strong positive correlations with CCED (US-PED: $r = 0.80$; MRI-PED: $r = 0.94$; $p < 0.001$ for both), with narrower limits of agreement for MRI on Bland–Altman analysis. CCED showed a moderate positive correlation with the number of lateral fluoroscopic images (NLFI) ($r = 0.46$; $p < 0.001$), while no significant associations were observed with age, gender, or body mass index.

Conclusion: Epidural depth in CIEIs can be predicted with clinically meaningful accuracy using both MRI and ultrasonography, with MRI demonstrating superior accuracy. Although these modalities do not replace fluoroscopy, preprocedural depth estimation may enhance procedural safety and improve planning of lateral fluoroscopic imaging as reflected by the NLFI. Further studies are needed to confirm these findings in broader patient populations.

* Corresponding author at: Department of Algology, Ankara Etlük City Hospital, Ankara, Türkiye.

E-mail address: damlayuruk@hotmail.com (D. Yürük).

<https://doi.org/10.1016/j.jclinane.2026.112183>

Received 17 January 2026; Received in revised form 22 February 2026; Accepted 10 March 2026

Available online 19 March 2026

0952-8180/© 2026 Elsevier Inc. All rights reserved, including those for text and data mining, AI training, and similar technologies.

1. Introduction

Cervical interlaminar epidural injection (CIEI) is a widely performed neuraxial intervention in anesthetic and pain management practice for neck and radicular pain associated with cervical disc herniation and nerve root irritation [1]. Accurate identification of the epidural space is critical, as inadvertent needle advancement may lead to serious complications, including dural puncture, spinal cord injury, and epidural or subdural hematoma [2].

The loss-of-resistance (LOR) technique remains the most commonly used method for epidural space identification. However, anatomical variations or incomplete midline fusion of the ligamentum flavum in the cervical region may result in false LOR [3]. Lee et al. reported a false-positive LOR rate of 68.7% during CIEIs, highlighting the importance of reliable epidural depth estimation in cervical epidural procedures [4].

Most studies investigating epidural depth prediction have focused on the lumbar region, with limited data available for cervical epidural injections. In lumbar procedures, magnetic resonance imaging (MRI) measurements have demonstrated good agreement with clinically determined LOR depth [5]. However, the routine use of MRI is limited by cost and accessibility [5]. By contrast, ultrasonography (US) offers a practical alternative owing to its bedside applicability and absence of ionizing radiation. Although US has been reported to be useful for preprocedural estimation of cervical epidural depth, no study has directly compared its performance with MRI or evaluated its impact on fluoroscopic use [6].

Fluoroscopy remains essential for confirming epidural placement during CIEIs and reducing the risk of complications. Nevertheless, a balance must be maintained between procedural safety and radiation exposure [7]. In this context, preprocedural epidural depth estimation should be regarded not as a substitute for fluoroscopy, but as a complementary strategy to optimize its use, particularly in high-risk cervical epidural interventions [8]. In the present study, fluoroscopic utilization was assessed by the number of lateral fluoroscopic images (NLFI), which was used as an indirect indicator of fluoroscopic use rather than a direct measurement of fluoroscopy time.

The aim of this study was to evaluate the accuracy of preprocedural epidural depth estimation using ultrasonography and magnetic resonance imaging in patients undergoing CIEIs, and to assess the relationship between true epidural depth, patient demographic characteristics, and fluoroscopic imaging requirements.

2. Methods

2.1. Study design, setting, and ethical approval

This study was designed as a prospective observational methodological comparison study. It was conducted between December 2024 and July 2025 through collaboration between the Algology Clinic and the Radiology Clinic at Ankara Etlik City Hospital, Turkey. The study protocol was approved by the Ankara Etlik City Hospital Scientific Research Evaluation and Ethics Committee on 27 November 2024 (Approval No: AESH-BADEK-2024-1133). Written informed consent was obtained from all participants, separate from procedural consent. The study was conducted in accordance with the Declaration of Helsinki.

The study was prospectively registered at [ClinicalTrials.gov](https://clinicaltrials.gov) (Identifier: NCT06747663) on December 18, 2024, and patient enrollment commenced on the same date.

2.2. Study population

Patients scheduled for CIEI as part of routine clinical practice were enrolled. Inclusion criteria were age ≥ 18 years, availability of a technically adequate cervical spine MRI obtained within the preceding six months, and suitability for preprocedural ultrasonographic evaluation.

Exclusion criteria included conditions in which CIEI is not routinely

performed for safety reasons, such as pregnancy, coagulation disorders or high bleeding risk related to anticoagulant or antiplatelet therapy, known allergy to radiopaque contrast media, prior cervical spine surgery, and distorted cervical anatomy due to infection, tumor, or other pathological conditions.

In addition, for methodological consistency in epidural depth measurement, patients undergoing non-midline epidural approaches (paramedian, parasagittal, or transforaminal) were excluded, as the study specifically aimed to evaluate midline interlaminar epidural depth.

2.3. Imaging and measurement protocols

2.3.1. Ultrasonography-predicted epidural depth (US-PED)

Before CIEI, all patients underwent ultrasonographic evaluation in the prone position with a pillow placed beneath the chest to increase cervical flexion. The C7–T1 interlaminar level was identified using fluoroscopy and marked on the skin.

Ultrasonographic measurements were performed according to a standardized protocol by the same experienced algology specialist who was not involved in needle insertion. A GE Healthcare LOGIQ P9 ultrasound system with a convex transducer (5–8 MHz) was used. Measurements were obtained in the transverse plane with strict midline alignment. US-predicted epidural depth (US-PED) was defined as the distance from the skin surface to the first hyperechoic structure corresponding to the ligamentum flavum–posterior epidural complex and recorded using built-in calipers (Fig. 1A).

Measurements were performed exclusively in the transverse plane; sagittal or parasagittal imaging was not used. This approach ensured consistency across ultrasonography, MRI, and fluoroscopic measurements and improved comparability between modalities.

2.3.2. Magnetic resonance imaging-predicted epidural depth (MRI-PED)

The most recent non-contrast cervical spine MRI obtained within six months prior to the procedure was reviewed for each patient. All MRI examinations were performed at the same institution using a standardized protocol on a 3-Tesla scanner, including sagittal and axial T1- and T2-weighted sequences.

MRI-based epidural depth measurements were performed at the C7–T1 level on sagittal T2-weighted images, which provide optimal visualization of the ligamentum flavum. Epidural depth was defined as the linear distance from the skin surface to the anterior margin of the ligamentum flavum, representing the posterior boundary of the epidural space.

Measurements were obtained using digital calipers and standardized to simulate a midline interlaminar needle trajectory while avoiding spinous processes. When necessary, minor cephalad or caudad adjustments were made to reflect the physiological needle path. As shown in Fig. 1B, care was taken to avoid measurement lines crossing osseous structures.

MRI-PED measurements were performed independently of the physician performing the injection and blinded to fluoroscopy-confirmed epidural depth values.

2.4. Fluoroscopic confirmation

2.4.1. Contrast-confirmed epidural depth (CCED)

CIEI procedures were performed by an interventional pain specialist blinded to US-PED and MRI-PED measurements. Patients were positioned prone with arms alongside the body to minimize shoulder superposition.

Under anteroposterior fluoroscopic guidance, the midline entry point at the C7–T1 interlaminar space was identified. Local anesthesia was administered using 1% lidocaine. A 9-cm, 18-gauge Tuohy epidural needle was advanced strictly in the midline using the loss-of-resistance technique with continuous saline pressure. Lateral fluoroscopic images were obtained at the discretion of the operator when necessary.

Epidural placement was confirmed by injection of 2 mL of nonionic contrast medium, demonstrating contrast spread within the posterior epidural space on anteroposterior and lateral views. Contrast-confirmed epidural depth (CCED) was defined as the distance from the skin surface to the point of epidural contrast spread, measured using calibrated needle markings at 0.25-cm intervals (Fig. 1C).

2.4.2. Number of lateral fluoroscopic images (NLFI)

The number of lateral fluoroscopic images (NLFI) was defined as the total number of lateral fluoroscopic acquisitions obtained during needle advancement throughout the procedure. NLFI was recorded by the algology specialist who performed the ultrasonographic measurements and used as an indirect indicator of fluoroscopy-related radiation exposure.

The purpose of analyzing NLFI was to evaluate the relationship between CCED and fluoroscopic imaging requirements, rather than to assess the impact of preprocedural imaging on operator behavior. The proceduralist was blinded to US-PED and MRI-PED measurements; therefore, NLFI was not influenced by predicted depth. In cervical interlaminar epidural procedures, incomplete midline fusion of the ligamentum flavum and the narrow safety margin may limit the reliability of LOR, increasing the risk of false LOR. As needle depth increases, the operator may intermittently obtain lateral fluoroscopic images to confirm appropriate interlaminar positioning and avoid advancement beyond the posterior epidural complex. To prevent misinterpretation, epidural placement was confirmed in all patients by contrast injection demonstrating posterior epidural spread. Thus, NLFI was considered a technical parameter potentially associated with actual epidural depth.

3. Demographic data

Patient age, gender, and body mass index (BMI) were recorded and evaluated as potential influencing variables.

3.1. Outcome measures

3.1.1. Primary outcome

The primary outcome was the accuracy of preprocedural epidural depth prediction using US-PED and MRI-PED compared with CCED, which served as the reference standard. Prediction accuracy was defined as measurements within ± 0.3 cm of CCED. Although a ± 0.5 cm equivalence margin has been used in lumbar epidural studies, a narrower threshold was selected due to the reduced safety margin in the cervical region [9].

3.1.2. Secondary outcomes

Secondary outcomes included evaluation of the relationship between

CCED and NLFI, as well as the influence of age, sex, and BMI on NLFI.

3.1.3. Sample size calculation

Sample size estimation was performed using G*Power software. Based on an effect size of 0.345 reported by Pak et al. for ultrasonographic measurement of ligamentum flavum depth in the cervical region, a significance level of 0.05 and statistical power of 0.90 were selected. The required minimum sample size was calculated as 90 patients [10].

3.2. Statistical analysis

Descriptive data are presented as mean \pm standard deviation for normally distributed variables and median (minimum–maximum) for non-normally distributed variables. Categorical variables are presented as counts and percentages. Normality was assessed using the Shapiro–Wilk test and visual inspection of histograms and probability plots.

Spearman correlation analysis was used to assess relationships between US-PED, MRI-PED, and CCED. Agreement between measurement methods was evaluated using Bland–Altman analysis. Clinical accuracy was defined as an absolute deviation ≤ 0.3 cm. Associations between NLFI and age, BMI, and CCED were analyzed using Spearman correlation, while differences in NLFI by sex were assessed using the Mann–Whitney *U* test.

All analyses were performed using R (version 4.3.2; R Core Team, Vienna, Austria). Bland–Altman analyses were conducted using the BlandAltmanLeh package. A *p* value < 0.05 was considered statistically significant.

4. Results

4.1. Patient characteristics and epidural depth measurements

During the study period, 94 patients were assessed for eligibility. Ninety patients met the inclusion criteria and were included in the final analysis; four patients were excluded due to failure to achieve a midline approach during CIEI. The mean age was 49.5 ± 9.5 years; 55 patients (61.1%) were female and 35 (38.9%) were male. The mean body mass index (BMI) was 28.6 ± 5.7 kg/m².

The mean contrast-confirmed epidural depth (CCED) was 6.01 ± 0.84 cm. Mean ultrasonography-predicted epidural depth (US-PED) was 5.92 ± 0.77 cm, and mean MRI-predicted epidural depth (MRI-PED) was 5.93 ± 0.97 cm.

Successful midline epidural access at the C7–T1 level was achieved in all included patients, and epidural placement was confirmed with contrast medium. Anatomical reference structures required for epidural depth measurement were identifiable in all patients on both

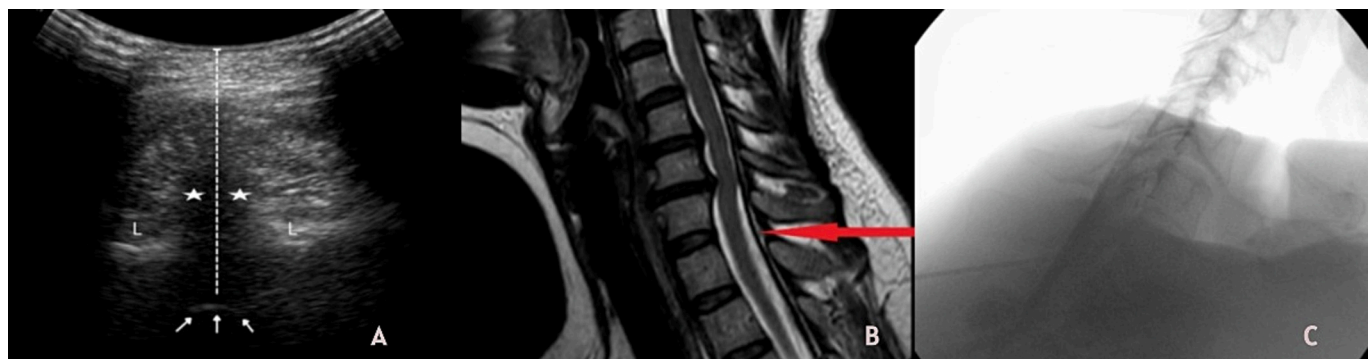

Fig. 1. Preprocedural prediction of cervical epidural depth using magnetic resonance imaging and ultrasound, with contrast confirmation. (A) Transverse ultrasonographic image at the C7–T1 interlaminar level demonstrating ultrasonography-predicted epidural depth (US-PED). (B) Sagittal T2-weighted cervical magnetic resonance image illustrating magnetic resonance imaging-predicted epidural depth (MRI-PED). (C) Lateral fluoroscopic image showing contrast spread within the posterior epidural space confirming epidural placement.

ultrasonographic and MRI evaluations.

4.2. Performance of imaging modalities in predicting true epidural depth

The performance of US-PED and MRI-PED in predicting CCED within the predefined ± 0.3 -cm clinically meaningful error margin is summarized in Table 1.

For US-PED, the mean absolute error was 0.37 ± 0.38 cm, with 54 measurements (60.0%) falling within the acceptable error range. For MRI-PED, the mean absolute error was 0.26 ± 0.18 cm, and 61 measurements (67.8%) were within the ± 0.3 -cm margin.

Spearman correlation analysis demonstrated a very strong positive correlation between MRI-PED and CCED ($r = 0.94$; $p < 0.001$). A strong positive correlation was also observed between US-PED and CCED ($r = 0.80$; $p < 0.001$). Correlation analyses and Bland–Altman plots are presented in Fig. 2. Bland–Altman analysis demonstrated wider dispersion of measurement error for US-PED, whereas MRI-PED exhibited narrower limits of agreement.

4.3. Relationship between epidural depth, patient characteristics, and number of lateral fluoroscopic images

A moderate, statistically significant positive correlation was observed between CCED and the number of lateral fluoroscopic images (NLFI) (Spearman $r = 0.46$; $p < 0.001$) (Fig. 3, upper left panel).

No significant correlation was observed between age and NLFI (Spearman $r = 0.06$; $p = 0.54$) (Fig. 3, upper right panel). Similarly, BMI was not significantly correlated with NLFI (Spearman $r = 0.17$; $p = 0.10$) (Fig. 3, lower left panel).

Comparison of NLFI by sex revealed no significant difference between female and male patients (median [interquartile range]; female: 5 [3–7] vs. male: 6 [4–7]; Mann–Whitney U test, $p = 0.14$) (Fig. 3, lower right panel).

5. Discussion

In this prospective observational study, epidural depth in patients undergoing CIEs was shown to be predictable preprocedurally with clinically meaningful accuracy using both ultrasonography and MRI. Although both modalities demonstrated strong correlations with contrast-confirmed epidural depth, MRI provided superior reliability, with higher accuracy and narrower error margins compared with ultrasonography. The slight underestimation observed with ultrasonographic measurements, with a mean difference of approximately 0.1 cm, is likely attributable to soft tissue compression caused by probe pressure and should be considered when interpreting US-based depth estimates in clinical practice.

MRI allows clear delineation of the ligamentum flavum and epidural space, making it a reliable modality for epidural depth assessment. Jones et al. demonstrated close agreement between MRI-based measurements and loss-of-resistance depth in both cervical and lumbar epidural

Table 1

The accuracy of ultrasonography (US-PED) and magnetic resonance imaging (MRI-PED) in predicting contrast-confirmed epidural depth (CCED) was investigated, with a margin of error of ± 0.3 cm being established.

Method	Mean Absolute Error (cm)	Standard Deviation (SD)	Number of Accurate Measurements (≤ 0.3 cm), n/N	Accuracy Rate, %
USG-PED	0,37	0,38	54/90	60,0
MRG-PED	0,26	0,18	61/90	67,8

The data are presented as mean \pm standard deviation or number (percentage). The term “clinical accuracy” was defined as an absolute measurement error of ≤ 0.3 cm.

injections [11]. Similarly, cervical spine-specific studies have reported strong correlations between MRI-predicted epidural depth and actual needle depth [12]. The findings of the present study are consistent with this literature and further support the reliability of MRI for preprocedural epidural depth estimation in CIEs.

In addition to MRI, this study evaluated ultrasonography-derived measurements and examined the relationship between epidural depth and the number of lateral fluoroscopic images as an indirect indicator of fluoroscopic utilization. Given the unique anatomical characteristics and narrower safety margins of the cervical epidural space, a clinically meaningful error margin was predefined to assess the practical applicability of both imaging modalities.

Ultrasonography is increasingly favored before epidural procedures because it avoids ionizing radiation, is readily available at the bedside, and allows rapid anatomical assessment. Previous studies have demonstrated the clinical utility of preprocedural ultrasonography in obstetric neuraxial anesthesia and during epidural catheter placement, where it facilitates identification of relevant anatomical landmarks and enhances procedural safety [13,14].

However, fluoroscopy with contrast confirmation remains the gold standard for CIEs, and ultrasonography is not intended to replace fluoroscopic guidance. In the present study, all procedures were performed under fluoroscopic guidance with contrast-confirmed epidural spread. Ultrasonography was evaluated as a complementary preprocedural planning tool rather than an alternative technique.

Ultrasonography may be particularly useful in selected clinical scenarios, such as when fluoroscopy is temporarily unavailable, when contrast use is contraindicated, in patients with significant concern regarding radiation exposure, or in technically challenging cases. Nevertheless, fluoroscopic confirmation remains essential to ensure procedural safety in cervical epidural interventions.

Fluoroscopy remains essential for confirming epidural placement during CIEs. Although radiation exposure is an inherent consideration in fluoroscopy-guided procedures, in the present study radiation dose was not directly quantified. Repeated lateral fluoroscopic imaging increases radiation exposure for both patients and healthcare personnel [15]. Therefore, NLFI should not be interpreted as a direct measure of radiation exposure but rather as a procedural parameter potentially associated with actual epidural depth.

In the present study, epidural depth emerged as a factor associated with the number of lateral fluoroscopic images obtained. In contrast, patient-related factors such as age, sex, and body mass index were not associated with fluoroscopic imaging requirements. These findings are consistent with previous studies and current guidelines demonstrating that radiation exposure correlates with procedural complexity and the number of fluoroscopic acquisitions, particularly in technically challenging cervical spine interventions [16].

Fluoroscopic guidance has been shown to reduce the risk of complications associated with epidural injections [17]. Preprocedural imaging modalities such as ultrasonography and MRI may further enhance procedural safety by improving depth estimation, especially in anatomically challenging cases. In this study, patients with significant cervical deformity or prior cervical spine surgery were excluded to minimize confounding from anatomical variability. While this approach allowed accurate assessment of epidural depth predictability in a relatively homogeneous population, it limits extrapolation of the findings to more complex cervical cases, which should be addressed in future studies.

Several limitations should be acknowledged. Although cervical MRI obtained within six months of the procedure improved temporal relevance, minor changes in body composition during this interval cannot be excluded. Ultrasonographic measurements may have been influenced by probe-related soft tissue compression, particularly in patients with higher BMI. All measurements were performed by a single experienced observer, reducing operator-dependent variability; however, interobserver reliability was not assessed. In addition, radiation exposure was

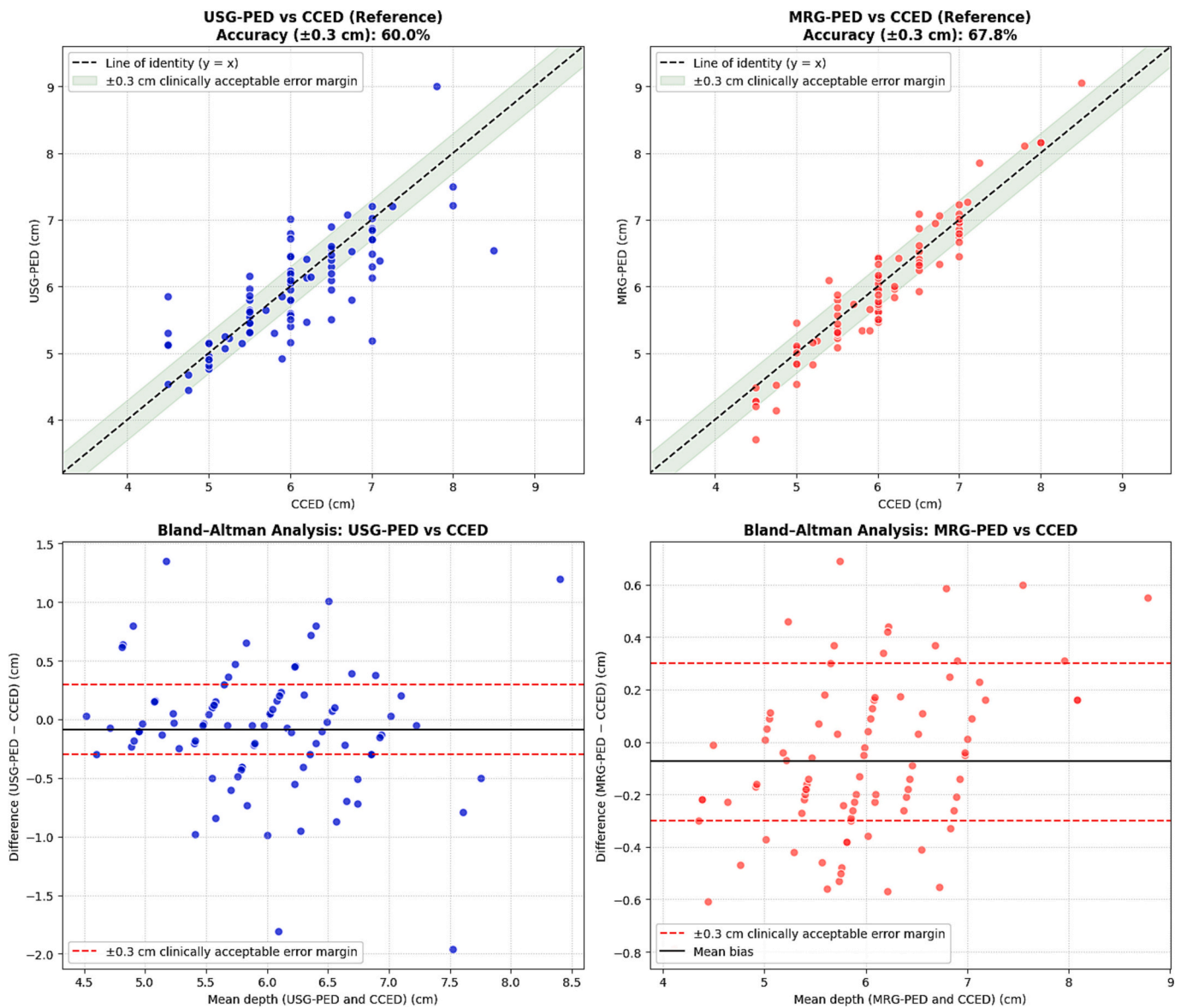


Fig. 2. Relationship between imaging-based epidural depth measurements and contrast-confirmed epidural depth. The upper panels show correlation plots between ultrasonography-predicted epidural depth (US-PED) and magnetic resonance imaging–predicted epidural depth (MRI-PED) versus contrast-confirmed epidural depth (CCED). The lower panels present Bland–Altman agreement analyses comparing US-PED and MRI-PED with CCED.

not quantified using objective metrics such as total fluoroscopy time or dose-area product; therefore, NLFIs should not be interpreted as a direct surrogate of radiation exposure.

Furthermore, the present study was conducted using a standard midline interlaminar approach with anteroposterior and lateral fluoroscopic views. The increasing use of contralateral oblique (CLO) imaging in CIEIs may limit the generalizability of our findings, as epidural depth measurements were standardized to the midline trajectory. Application of MRI- or ultrasonography-based depth estimation to CLO-guided techniques may require different anatomical projection considerations.

Despite these limitations, this study has notable strengths. Its prospective design, specific focus on cervical interlaminar epidural injections, and direct comparison of ultrasonography- and MRI-derived measurements with contrast-confirmed epidural depth in the same patient cohort represent important methodological advantages. Blinding of the proceduralist to preprocedural imaging measurements reduced measurement bias and strengthened internal validity. The use of a standardized measurement protocol, a clinically meaningful error

margin (± 0.3 cm), and lateral fluoroscopic image count as a surrogate marker of fluoroscopic utilization further enhance the clinical relevance and applicability of the findings.

6. Conclusions

This prospective study shows that epidural depth in CIEIs can be predicted preprocedurally using both MRI and ultrasonography. Although these imaging modalities do not replace fluoroscopy, preprocedural depth estimation may facilitate safer and more predictable epidural access planning. The observed association between epidural depth and the number of lateral fluoroscopic images highlights the potential role of depth estimation in optimizing fluoroscopic use and reducing radiation exposure. Further studies are needed to confirm these findings in broader patient populations and in cases with complex cervical anatomy.

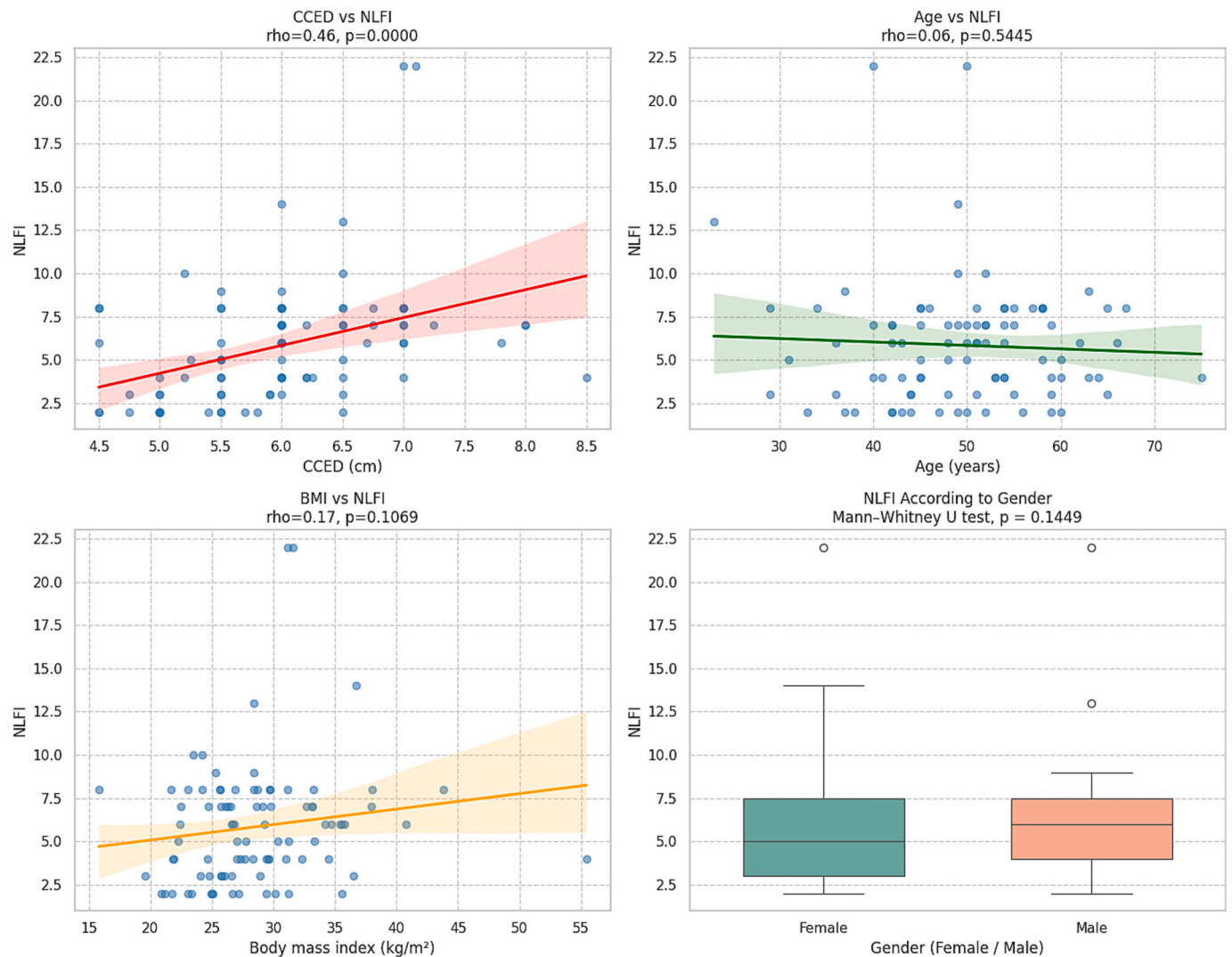


Fig. 3. Associations between contrast-confirmed epidural depth, patient characteristics, and fluoroscopic use. The panels illustrate the relationships between contrast-confirmed epidural depth (CCED), patient age, body mass index, gender, and the number of lateral fluoroscopic images (NLFI).

CRediT authorship contribution statement

Damla Yürük: Writing – review & editing, Writing – original draft, Visualization, Validation, Supervision, Software, Resources, Project administration, Methodology, Investigation, Formal analysis, Data curation, Conceptualization. **Gözde Erol:** Writing – review & editing, Visualization, Validation, Resources, Project administration, Methodology, Investigation, Data curation. **Pelin Kavak:** Writing – review & editing, Visualization, Validation, Supervision, Methodology, Investigation, Formal analysis, Data curation, Conceptualization. **Omer Taylan Akkaya:** Writing – review & editing, Validation, Supervision, Project administration, Methodology, Conceptualization.

Funding

No specific funding was received for this study from any public, commercial, or not-for-profit funding bodies.

Declaration of competing interest

The authors have no competing interests to declare.

Acknowledgments

None.

References

- [1] Yildiz G, Perdecioğlu GRG, Akkaya OT, Can E, Yuruk D. Comparison of selective nerve root pulsed radiofrequency vs paramedian interlaminar epidural steroid injection for the treatment of painful cervical radiculopathy. *Pain Phys* 2024;27(2):E221–9.
- [2] Armon C, Narayanaswami P, Potrebic S, et al. Epidural steroids for cervical and lumbar radicular pain and spinal stenosis: systematic review summary. Report of the AAN Guidelines Subcommittee. *Neurology* 2025;104(5):e213361.
- [3] Holder EK, Lee H, Raghunandan A, International Pain and Spine Intervention Society Patient Safety Committee, et al. FactFinders for patient safety: risks with cervical epidural injections. *Interv Pain Med* 2024;3(3):100430.
- [4] Lee JY, Lee SM, Sim WS, et al. False loss of resistance in cervical epidural injection: the loss of resistance technique compared with Epidrum guidance in locating epidural space. *Pain Phys* 2016;19(3):131–8.
- [5] Kim J, Kim M, Kim JE, Kwon Y, Kim JH. Needle depth and angle for lumbar interlaminar epidural injection using magnetic resonance imaging and C-arm measurements. *Pain Phys* 2023;26(2):E83–90.
- [6] Kim SH, Lee KH, Yoon KB, Park WY, Yoon DM. Sonographic estimation of needle depth for cervical epidural blocks. *Anesth Analg* 2008;106(5):1542–7.
- [7] Benyamin RM, Vallejo R, Kramer J, et al. Complications of cervical epidural steroid injections. *Curr Pain Headache Rep* 2016;20(4):27.
- [8] Benzon HT, Huntoon MA, Rathmell JP, et al. Improving the safety of epidural steroid injections. *Anesthesiology* 2015;122:974–84.

- [9] Singh N, Pritzlaff S, Bautista B, et al. Correlation between epidural space depth measured with ultrasound and MRI compared to clinical loss of resistance when performing lumbar epidural steroid injection. *Reg Anesth Pain Med* 2024;49(12): 871–6. <https://doi.org/10.1136/rapm-2023-105135>.
- [10] Pak MH, Lee WH, Ko YK, So SY, Kim HJ. Ultrasonographic measurement of the ligamentum flavum depth: is it a reliable method to distinguish true and false loss of resistance? *Korean J Pain* 2012;25(2):99–104.
- [11] Jones JH, Singh N, Nidecker A, et al. Agreement between radiologic and clinical measurements of lumbar and cervical epidural depths in patients undergoing prone interlaminar epidural steroid injection. *Anesth Analg* 2017;124:1678–85.
- [12] Algrain H, Liu A, Singh S, Vu TN, Cohen SP. Cervical epidural depth: correlation between cervical MRI measurements of the skin-to-epidural space and actual needle depth during interlaminar cervical epidural injections. *Pain Med* 2018;19(5):1015–22.
- [13] Zhou Y, Chen W, Zhou S, et al. Comparison of different approaches to combined spinal epidural anesthesia under ultrasound guidance in cesarean delivery of obese patients: a randomized controlled trial. *Eur J Med Res* 2021;26:106.
- [14] Arzola C, Davies S, Rofaeel A, et al. Ultrasound using the transverse approach to the lumbar spine provides reliable landmarks for labor epidurals. *Anesth Analg* 2007;104:1188–92.
- [15] Manchikanti L, Kaye AD, Falco FJE, Hirsch JA. Radiation exposure and safety in interventional pain management: a narrative review. *Pain Phys* 2021;24(1): S13–32.
- [16] Engel A, King W, MacVicar J, et al. Practice guidelines for fluoroscopic imaging in spinal interventional pain procedures. *Pain Med* 2023;24(4):451–62.
- [17] Chin KJ, Perlas A, Chan V, et al. Ultrasound imaging facilitates spinal anesthesia in adults with difficult surface anatomic landmarks. *Anesthesiology* 2011;115: 94–101.